



## Get Clarity On Generics

Cost-Effective CT & MRI Contrast Agents



FRESENIUS  
KABI

WATCH VIDEO

# AJNR

### Acute traumatic vacuum sign.

S P Bohrer

*AJNR Am J Neuroradiol* 1986, 7 (5) 973-974

<http://www.ajnr.org/content/7/5/973.citation>

This information is current as  
of August 16, 2025.

# Correspondence

## Letters to the Editor

### Acute Traumatic Vacuum Sign

Acute traumatic vacuum phenomenon as a sign of hyperextension injury in the cervical spine can be a confusing topic. Edeiken-Monroe et al. [1] recently reported 20 patients with hyperextension dislocation injuries of the cervical spine. Three patients showed a "vacuum disc"; one of their radiographs is reproduced in the article. The lucency lies in the center of the nucleus pulposus.

The authors refer to Reymond et al. [2] as the first to report on a "lucent cleft" as a sign of acute hyperextension injury. The cleft reported by these authors is clearly different because it appears at the anterior margin of the vertebral column adjacent to the vertebral end-plate. It is said to be caused by tearing of Sharpey fibers between the annulus fibrosus and the bony vertebral margin [3-6]. There are numerous examples of this cleft in the literature [3-5].

The vacuum shown by Edeiken-Monroe et al. must be a different pathology. They suggest it is due to "transection of the intervertebral disc" (nucleus pulposus). If this is true, their cases are, I believe, the first documented cases of an acute tear of the nucleus with a vacuum sign. Classically, the nucleus cleft (as opposed to the annulus cleft) has been associated with degenerative disease of the nucleus pulposus. The annulus cleft can be due to either traumatic or degenerative causes [4].

Torg [7] does show a similar case in his book and suggests the disc injury is due to axial compressive forces. This should not produce a "central cord syndrome," which all of Edeiken-Monroe's patients had. Rosenberg [8], reviewing Torg's book commented, "I was surprised to learn that the (nucleus) 'vacuum' phenomenon at a cervical interspace is indicative of disc injury (?)," thus indicating that this has not been generally appreciated. Torg's example has some features of a pseudovacuum sign. The vacuum of Edeiken-Monroe et al. also has some characteristics of a pseudovacuum, but is not typical. We are not told if their vacuums disappear or change position in neutral or flexion positions. True vacuums tend to do the former, pseudovacuum the latter.

In conclusion, Edeiken-Monroe et al. have described a new sign, if they can confirm that it is not a pseudosign. There is some controversy about the specific pathology and mechanism involved. Further observations and study by them and others are certainly in order. In the meantime, I suggest we label vacuum clefts as "annulus clefts"

or "nucleus clefts" and as degenerative or traumatic to lessen the existing confusion in the literature.

Stanley P. Bohrer  
Bowman Gray School of Medicine  
of Wake Forest University  
Winston-Salem, NC 27103

### REFERENCES

1. Edeiken-Monroe B, Wagner LK, Harris JH Jr. Hyperextension dislocation of the cervical spine. *AJNR* 1986;7:135-140
2. Reymond RD, Wheeler RS, Parovic M, Block B. The lucent cleft, a new radiologic sign of cervical disc injury or disease. *Clin Radiol* 1972;23:188-192
3. Resnick D, Niwayama G, Guerra J, Vint V, Usselman J. Spinal vacuum phenomena: anatomical study and review. *Radiology* 1981;139:341-348
4. Bohrer SP. The annulus vacuum sign. *Skeletal Radiol* 1986;15:233-235
5. Hilton RC, Ball J. Vertebral rim lesions in the dorsolumbar spine. *Ann Rheum Dis* 1984;43:302-307
6. Greenbaum EI, ed. *Radiology of the emergency patient*. New York: Wiley, 1982:117
7. Torg JS, ed. *Athletic injuries to the head, neck and face*. Philadelphia: Lea and Febiger, 1982:185
8. Rosenberg MA. Book review. *AJR* 1982;139:912

### Reply

We appreciate the opportunity to respond to Dr. Bohrer's letter. Traumatic avulsion of a cervical disc from the end-plate in association with a hyperextension injury was first described at autopsy in 1948 by Taylor and Blackwood [1]. In 1972, Reymond et al. subsequently described, on plain radiographs, a lucent cleft, or vacuum disc, as a sign of traumatic cervical disc injury. They proposed that the vacuum occurred from an influx of nitrogen at the time of traumatic separation of the disc from the vertebral end-plate.

In our series, the diagnosis of hyperextension dislocation was based on normal alignment of the cervical spine with diffuse prevertebral soft-tissue swelling and the clinical circumstance of central-cord syndrome. "Vacuum disc" was observed in only three of the 20 patients with hyperextension dislocation in our series and simply served as a supporting and localizing sign of hyperextension dislocation. We made no claim to personal knowledge regarding its cause;



the significance, if any, of its position within the disc space; nor its presence as a "new sign."

We are pleased to learn that Dr. Bohrer is conducting basic research in the area of cervical disc injury. We hope that our observations on the presence of vacuum disc in association with hyperextension dislocation will contribute, in a small part, to the ongoing research.

Beth Edeiken-Monroe  
Louis K. Wagner  
John H. Harris, Jr.  
University of Texas Medical School  
Houston, TX 77030

#### REFERENCE

1. Taylor AR, Blackwood W. Paraplegia in cervical injuries with normal radiographic appearance. *J Bone Joint Surg (Br)* 1948;30:245-248

#### Left-Right Temporal Region Asymmetry in Infants and Children

I was interested in the article by Seidenwurm et al. [1] in the September/October issue of *AJNR*. I have noticed for many years that the left Sylvian fissure, particularly its anterior end, is commonly

wider than is the right in adults. (I do not see many CTs of children.) Arteriographic studies and examinations of brains at autopsy show the posterior portion of the right temporal lobe to be more often larger than the left [2]. Looking at the temporal lobes of gross brains and at many of the brain sections in the Yakovlev collection (now at the Armed Forces Institute of Pathology in Washington), I have noticed that the anterior end of the right temporal lobe commonly appears to be slightly more bulbous than the anterior end of the left temporal lobe (Fig. 1). I have wondered, therefore, if the difference in widths of the Sylvian fissure is not due to the difference in bulk of the temporal lobes.

Pneumoencephalographic (PEG) studies (which some of the readers of *AJNR* may be too young to be familiar with) also show temporal lobe asymmetries. The left temporal horn, as well as the body of the left lateral ventricle, is commonly larger than the right [3].

Seidenwurm et al. caution the readers that some of the children they are studying may have abnormal brains because their neurologic symptoms developed in early life. As has been shown in earlier PEG studies [4, 5], brain asymmetries are frequently different in patients who develop seizures in early life from those in patients without seizures. I believe that the results of the carefully carried out study by Deuel et al. are flawed by the fact that most of the children they studied either had, or were suspected of having, seizures.

Marjorie LeMay  
Harvard University Health Services  
Cambridge, MA 02138

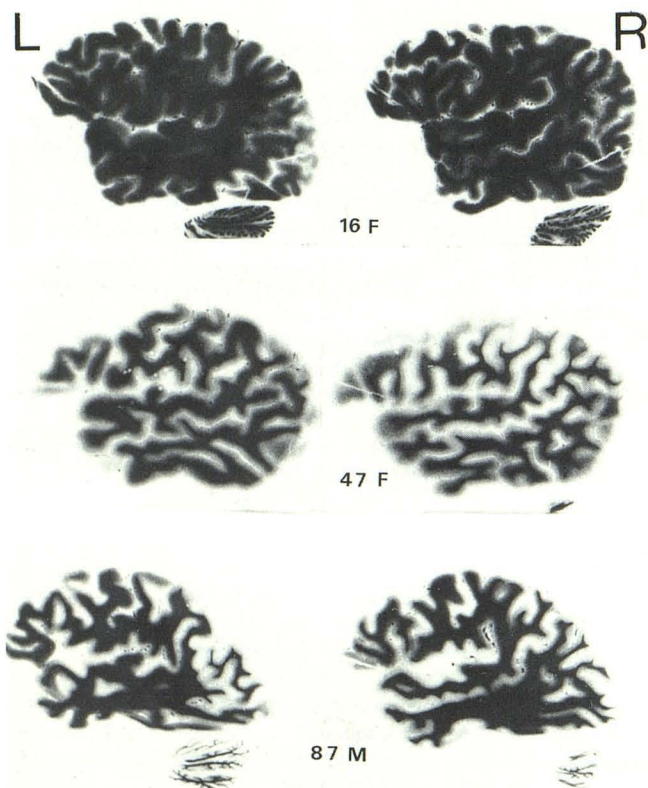


Fig. 1.—Sections through right and left temporal lobes of brain from patients of various ages show right temporal lobes larger than left, even at anterior ends.

#### REFERENCES

1. Seidenwurm D, Bird CR, Enzmann DR, Marshall WH. Left-right temporal region asymmetry in infants and children. *AJNR* 1985;6:777-779
2. LeMay M, Culebras A. Human brain: morphologic differences in the hemispheres demonstrable by carotid arteriography. *N Engl J Med* 1972;287:168-170
3. LeMay M. Morphological cerebral asymmetries of modern man, fossil man, and nonhuman primate. *Ann NY Acad Sci* 1976;280:349-366
4. McRae DL, Branch CL, Milner B. The occipital horns and cerebral dominance. *Neurology* 1966;18:95-98
5. Strauss E, Fitz C. Occipital horn asymmetry in children. *Ann Neurol* 1980;8:437-439

#### Reply

We thank Dr. LeMay for her attention to our recent article and acknowledge her contributions to the current understanding of cerebral asymmetries. As we pointed out, methodologic limitations in our study and in others prevent rigorous assertion of left right temporal asymmetry as normal. The mass of accumulated data, some of which is cited by Dr. LeMay, seems to be consistent with our finding that the left Sylvian fissure is normally larger than the right. Perhaps MR or sonography will offer us the opportunity to study true normals.

David Seidenwurm  
C. Roger Bird  
Dieter Enzmann  
W. H. Marshall  
Stanford University Medical Center  
Stanford, CA 94305