



Providing Choice & Value
Generic CT and MRI Contrast Agents

 **FRESENIUS
KABI**

CONTACT REP

AJNR

Left-right temporal region asymmetry in infants and children.

M LeMay

AJNR Am J Neuroradiol 1986, 7 (5) 974

<http://www.ajnr.org/content/7/5/974.citation>

This information is current as
of July 5, 2025.

the significance, if any, of its position within the disc space; nor its presence as a "new sign."

We are pleased to learn that Dr. Bohrer is conducting basic research in the area of cervical disc injury. We hope that our observations on the presence of vacuum disc in association with hyperextension dislocation will contribute, in a small part, to the ongoing research.

Beth Edeiken-Monroe
Louis K. Wagner
John H. Harris, Jr.
University of Texas Medical School
Houston, TX 77030

REFERENCE

1. Taylor AR, Blackwood W. Paraplegia in cervical injuries with normal radiographic appearance. *J Bone Joint Surg (Br)* 1948;30:245-248

Left-Right Temporal Region Asymmetry in Infants and Children

I was interested in the article by Seidenwurm et al. [1] in the September/October issue of *AJNR*. I have noticed for many years that the left Sylvian fissure, particularly its anterior end, is commonly

wider than is the right in adults. (I do not see many CTs of children.) Arteriographic studies and examinations of brains at autopsy show the posterior portion of the right temporal lobe to be more often larger than the left [2]. Looking at the temporal lobes of gross brains and at many of the brain sections in the Yakovlev collection (now at the Armed Forces Institute of Pathology in Washington), I have noticed that the anterior end of the right temporal lobe commonly appears to be slightly more bulbous than the anterior end of the left temporal lobe (Fig. 1). I have wondered, therefore, if the difference in widths of the Sylvian fissure is not due to the difference in bulk of the temporal lobes.

Pneumoencephalographic (PEG) studies (which some of the readers of *AJNR* may be too young to be familiar with) also show temporal lobe asymmetries. The left temporal horn, as well as the body of the left lateral ventricle, is commonly larger than the right [3].

Seidenwurm et al. caution the readers that some of the children they are studying may have abnormal brains because their neurologic symptoms developed in early life. As has been shown in earlier PEG studies [4, 5], brain asymmetries are frequently different in patients who develop seizures in early life from those in patients without seizures. I believe that the results of the carefully carried out study by Deuel et al. are flawed by the fact that most of the children they studied either had, or were suspected of having, seizures.

Marjorie LeMay
Harvard University Health Services
Cambridge, MA 02138

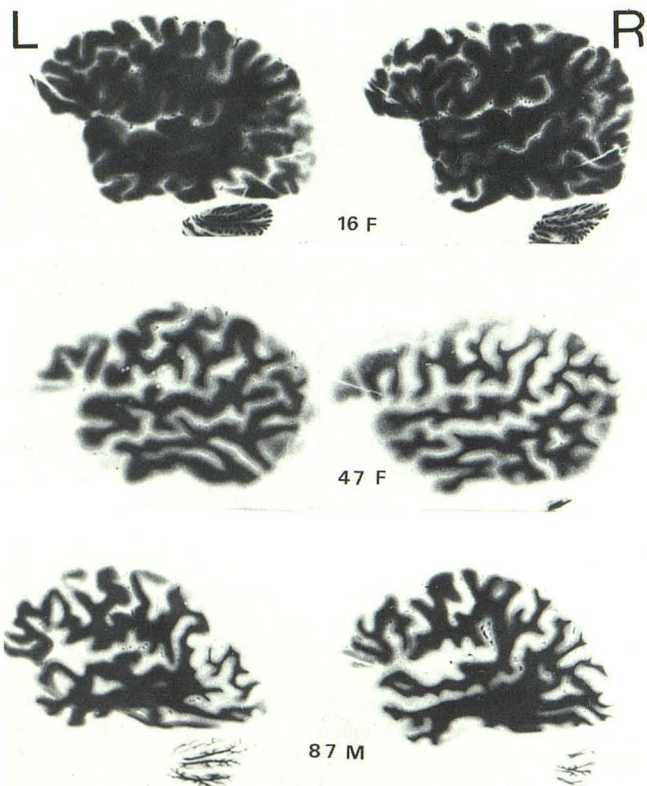


Fig. 1.—Sections through right and left temporal lobes of brain from patients of various ages show right temporal lobes larger than left, even at anterior ends.

REFERENCES

1. Seidenwurm D, Bird CR, Enzmann DR, Marshall WH. Left-right temporal region asymmetry in infants and children. *AJNR* 1985;6:777-779
2. LeMay M, Culebras A. Human brain: morphologic differences in the hemispheres demonstrable by carotid arteriography. *N Engl J Med* 1972;287:168-170
3. LeMay M. Morphological cerebral asymmetries of modern man, fossil man, and nonhuman primate. *Ann NY Acad Sci* 1976;280:349-366
4. McRae DL, Branch CL, Milner B. The occipital horns and cerebral dominance. *Neurology* 1966;18:95-98
5. Strauss E, Fitz C. Occipital horn asymmetry in children. *Ann Neurol* 1980;8:437-439

Reply

We thank Dr. LeMay for her attention to our recent article and acknowledge her contributions to the current understanding of cerebral asymmetries. As we pointed out, methodologic limitations in our study and in others prevent rigorous assertion of left right temporal asymmetry as normal. The mass of accumulated data, some of which is cited by Dr. LeMay, seems to be consistent with our finding that the left Sylvian fissure is normally larger than the right. Perhaps MR or sonography will offer us the opportunity to study true normals.

David Seidenwurm
C. Roger Bird
Dieter Enzmann
W. H. Marshall
Stanford University Medical Center
Stanford, CA 94305