



Providing Choice & Value

Generic CT and MRI Contrast Agents



**FRESENIUS
KABI**

CONTACT REP

AJNR

**Cardiac-gated local coil MR imaging of the
carotid neck bifurcation.**

D L Daniels, J B Kneeland, W D Foley, A Jesmanowicz, W
Froncisz and J S Hyde

AJNR Am J Neuroradiol 1986, 7 (6) 1036-1037

<http://www.ajnr.org/content/7/6/1036.citation>

This information is current as
of July 5, 2025.

Cardiac-Gated Local Coil MR Imaging of the Carotid Neck Bifurcation

David L. Daniels,¹ J. Bruce Kneeland, W. Dennis Foley, Andrzej Jesmanowicz, Wojciech Froncisz,² and James S. Hyde

The value of duplex Doppler sonography as a noninvasive technique for evaluating the carotid neck vessels has been well documented [1–4]. The sensitivity and specificity of duplex Doppler sonography in the detection of high-grade stenosis (greater than 80%) approximates 90% [1]. However, duplex Doppler sonography has several limitations. Plaque ulceration cannot be detected reliably, even with high-frequency short-focused transducers [1]. Furthermore, in some circumstances, it cannot distinguish between a patent internal carotid artery with high-grade stenosis and an occluded vessel [2]. Finally, if no signal is detected in the narrowed internal carotid artery, the patent external carotid artery may be mistaken for it [3]. MR imaging with local (surface) coils has the potential to detect carotid ulceration and stenosis noninvasively because of the negligible signal produced by rapidly flowing blood and the high resolution obtained with local coils. Large plaques have been seen in the aorta [5] and other large vessels, [6] and the identification of plaques in neck vessels would be of potential significance. In the past our attempts at MR imaging of neck vessels has not been optimal due to flow-related artifacts. We used local coils in conjunction with cardiac gating to improve anatomic resolution and minimize flow artifacts.

Materials and Methods

Three volunteers, ages 20–30 years old, underwent MR imaging of their carotid neck bifurcations. In addition, we imaged the right carotid neck bifurcation in a patient who, 2 days before the MR study, had a digital subtraction angiogram that showed an ulcer. The angiogram was performed via transfemoral approach with catheterization of the right common carotid artery.

MR imaging was performed with a General Electric Signa MR system operating at 1.5 T, using a counter-rotating-current loop-gap resonator as a local receiver coil with the body coil as the transmitter. The local coil consists of two loops, each with a 5-cm diameter. The properties of this coil and similar ones have been previously described [7, 8]. These coils are intrinsically decoupled (i.e., they do not receive) from the circularly polarized (quadrature) transmitted RF waves of

the Signa system. The 5-cm coil was placed directly on the skin of the lateral surface of the subject's neck with the subject supine, his head and neck in a three-sided plastic holder. Data were acquired with a 2DFT multisection technique using a 128×256 matrix, a 16-cm field of view, two excitations, and 3-mm thick sections with a 1-mm gap. ECG gating was used with the trigger set to 9 msec from the R wave. The ECG signal was transmitted from the patient by cable to a cardiac monitor (78351A, Hewlett-Packard, Menlo Park, CA), which in turn triggered the pulse sequences. The repetition time (TR) was determined by the R-R interval; the echo-delay time (TE) was 20 msec.

Results and Discussion

In the three normal volunteers, the carotid neck bifurcations were seen with minimal flow artifact, although some artifact was seen on sections obtained during diastole, when the velocity of flowing blood was rather low. No evidence of vessel narrowing or ulceration was seen in any of the volunteers. In one volunteer, the proximal part of the external carotid artery was shown in an image adjacent to that of the proximal internal carotid artery. In the patient's MR study, an ulcer crater with negligible signal was identified at the posterior wall of the origin of the internal carotid artery that correlated with the opacified crater shown in a digital subtraction angiogram (Fig. 1). In addition, MR identified an adjacent localized area of carotid wall thickening attributable to atherosclerotic plaque. The high signal intensity from the plaque may be due to its lipid content.

For evaluating the carotid bifurcations with MR, further work is needed to optimize scanning parameters and local coils. With cardiac gating, the optimal timing of the pulse trigger from the R wave must be evaluated in order to minimize flow artifacts. In addition, the value of different scanning planes must be studied. For example, oblique imaging probably will be required to evaluate carotid bifurcations in which the proximal internal and external carotid arteries are not in the same parasagittal plane or in which the plaque is eccentrically located. The sensitivity of MR relative to other

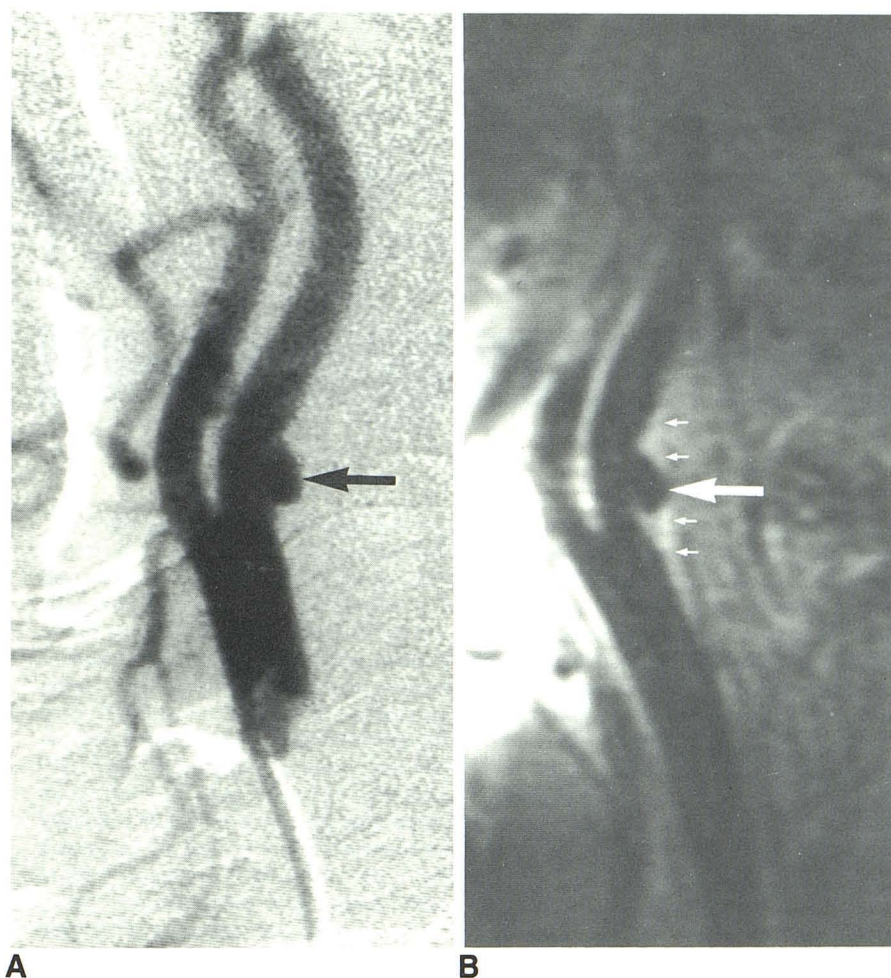
Received April 25, 1986; accepted after revision July 3, 1986.

¹ All authors: Department of Radiology, Medical College of Wisconsin, Froedtert Memorial Lutheran Hospital, 9200 West Wisconsin Ave., Milwaukee, WI 53226. Address reprint requests to D. L. Daniels.

² On leave from the Department of Biophysics, Jagiellonian University, Krakow 31-120, Poland.

AJNR 7:1036–1037, November/December 1986 0195–6108/86/0706–1036 © American Society of Neuroradiology

Fig. 1.—Carotid ulcer (large arrow) in corresponding lateral digital subtraction angiographic (A) and parasagittal cardiac-gated local coil MR (B) images. Ulcer projecting posteriorly from proximal internal carotid artery opacifies in A and has negligible signal in B. Note plaque (small arrows in B) that marginates ulcer. (The MR image was obtained 400 msec from R wave.)



imaging techniques for detecting vessel ulceration and stenosis remains to be determined. MR may prove to be an effective noninvasive screening test for atherosclerotic disease in neck vessels.

REFERENCES

1. Jacobs NM, Grant EG, Schellinger D, Byrd M, Richardson JD, Cohan SL. Duplex carotid sonography: criteria for stenosis, accuracy, and pitfalls. *Radiology* **1985**;154:385-391
2. Fell G, Phillips DJ, Chikos FM, Harley JD, Thiele BL, Strandness DE Jr. Ultrasound duplex scanning for disease of the carotid artery. *Circulation* **1981**;64:1191-1195
3. Zwiebel WJ, Crummy AB. Sources of error in Doppler diagnosis of carotid occlusive disease. *AJR* **1981**;137:1-12, *AJNR* **1981**;2:231-242
4. Prendes JL, McKinney WM, Buonanno FS, Jones AM. Anatomic variations of the carotid bifurcations affecting Doppler scan interpretation. *JCU* **1980**;8:147-150
5. Herfkens RJ, Higgins CB, Hricak H, et al. Nuclear magnetic resonance imaging of atherosclerotic disease. *Radiology* **1983**;148:161-163
6. Wesbey GE, Higgins CB, Amparo EG, Hale JD, Kaufman L, Pogany AC. Peripheral vascular disease: correlation of MR imaging and angiography. *Radiology* **1985**;156:733-739
7. Froncisz W, Jesmanowicz A, Kneeland JB, Hyde JS. Counter rotating current local coils for high resolution magnetic resonance imaging. *Mag Res Med* **1986**;3:590-603
8. Kneeland JB, Carrera GF, Middleton WD, et al. Rotator cuff tears: preliminary application of high-resolution MR imaging with counter rotating current loop-gap resonators. *Radiology* **1986**;160:695-699