



## Get Clarity On Generics

Cost-Effective CT & MRI Contrast Agents



FRESENIUS  
KABI

WATCH VIDEO

# AJNR

## **Intracavernous aneurysms: treatment by proximal balloon occlusion of the internal carotid artery.**

J Raymond and J Théron

*AJNR Am J Neuroradiol* 1986, 7 (6) 1087-1092

<http://www.ajnr.org/content/7/6/1087>

This information is current as  
of August 11, 2025.

# Intracavernous Aneurysms: Treatment by Proximal Balloon Occlusion of the Internal Carotid Artery

Jean Raymond<sup>1,2</sup>  
Jacques Théron<sup>1</sup>

Seven patients with intracavernous aneurysms were treated by proximal balloon occlusion of the carotid artery, with no attempt to preserve carotid blood flow. After a 15-minute occlusion trial, two balloons were detached proximal to the neck of these aneurysms. Major clinical improvement occurred in six patients and no procedure-related complications were encountered (the follow-up period was 4–14 months). Because these aneurysms arise proximal to major collateral pathways, proximal carotid occlusions via endovascular techniques are simple and safe and carry with them little risk of thromboembolism.

Endovascular procedures using balloon catheters have introduced alternative methods of treating difficult neurosurgical problems, including the treatment of giant aneurysms or aneurysms located in inaccessible sites [1–5]. Until recently, the accepted form of therapy for these lesions was carotid artery ligation with or without extracranial-intracranial by-pass. Balloon occlusion of the neck of aneurysms at all sites, with preservation of the parent artery [6] and “balloon trapping” [5] are now possible and offer distinct advantages in certain circumstances. Intracavernous aneurysms, however, are specific lesions [7] where a simplified approach—the endovascular application of the “Hunterian principle” [8] (i.e., ligation of the parent artery)—has resulted in safe, effective treatment.

The purpose of this study is to clarify some of the controversy regarding indications, technique, complications, and effectiveness of the endovascular approach as applied to intracavernous aneurysms.

## Material and Methods

Seven patients referred for treatment of aneurysms of the cavernous segment of the internal carotid artery were studied by CT with and without contrast enhancement (2 ml/kg Conray 60%). The angiographic examination included four-vessel angiograms with cross compression to assess the morphologic status of the circle of Willis and to exclude significant atherosclerotic involvement of the contralateral carotid artery or the presence of additional aneurysms.

Premedication with two divided doses of 650 mg aspirin (administered 15 and 3 hr before embolization), systemic heparinization with 2,000 units once the catheter was well secured, and protamine reversal at the end of the procedure, were routinely used. The femoral arterial route was used for embolization using local anesthesia only. Latex balloons (0.8 × 0.3 × 0.8 mm; Balt, 10, rue Croix Vigneron, 95160 Montmorency, France) were tied to a single lumen 2F polyethylene catheter (0.3 × 0.5 mm; Habia, S.A. Route de Châlons sur Marne, 51210 Montmirail, France) with elastic ligatures.

Guiding catheters (8F) were used to introduce the balloon catheters and for control angiography during embolization. The balloons were inflated with Hexabrix 30%. The position of the balloon was determined by partial balloon opacification.

Once positioned in the cervical, petrous, or proximal cavernous segments of the internal carotid artery, the balloon was inflated and occlusion verified by angiography. Patients were

Received October 25, 1985; accepted after revision March 24, 1986

<sup>1</sup>Department of Radiology, Montreal Neurological Hospital, 3801 University St., Montreal, Quebec, Canada H3A 2B4.

<sup>2</sup>Department of Radiology, Hôpital Saint-Luc, 1058 St. Denis St., Montreal, Quebec, Canada H2X 3J4. Address reprint requests to J. Raymond.

**AJNR 7:1087–1092, November/December 1986**  
0195–6108/86/0706–1087

© American Society of Neuroradiology



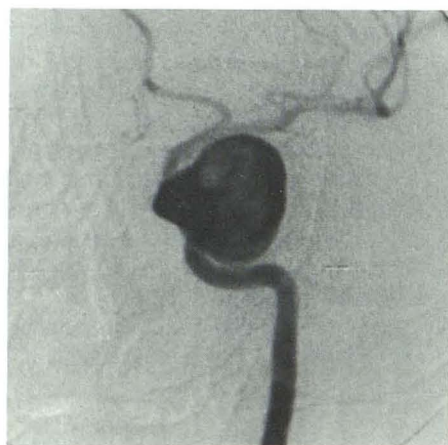closely monitored clinically for approximately 15 min to test for tolerance to the occlusion. The balloon was then detached by traction on the catheter. A second balloon was then detached proximal to the first. The patients were instructed to take 325 mg aspirin every day,

indefinitely.

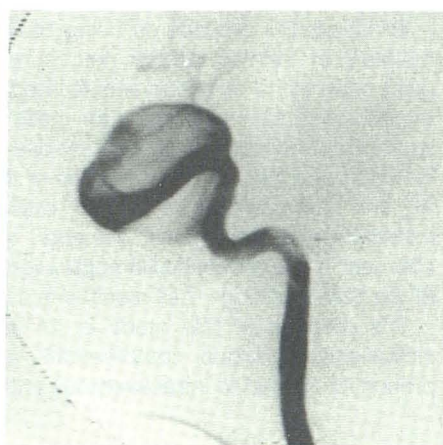Follow-up examinations, 4 to 14 months after embolization, included careful clinical assessment, plain radiographs, CT with and without contrast enhancement, and digital angiography. The latter

TABLE 1: Balloon Embolization of Cavernous Carotid Aneurysms

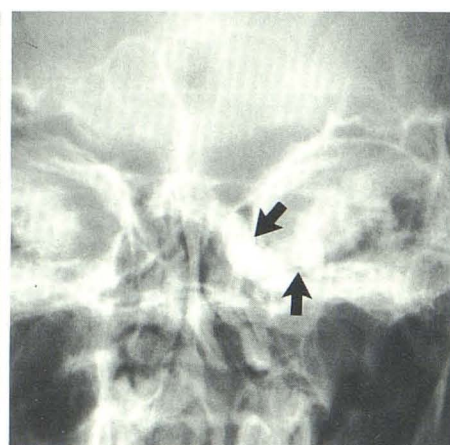
Case No.	Age/Gender	Presentation	Approximate Size (mm)	Follow-up (months)	Clinical Evolution	Follow-up CT
1	26/F	Partial III–VI palsy 5 mo post/trauma	25 × 20	14	Complete recovery	None
2	67/M	Pain, proptosis, total ophthalmoplegia	20 × 10	11	Marked improvement, minimal residual proptosis, and III CN paresis	Rim enhancement
3	66/F	Pain, proptosis, III–IV–VI palsy	25 × 25	8	Marked improvement, no proptosis, residual III–VI palsy	Rim enhancement
4	24/F	Pain, proptosis, total ophthalmoplegia	50 × 35	8	Marked improvement, residual proptosis, minimal residual III–VI CN paresis	Collapse
5	80/F	Pain, partial VI palsy	25 × 15	6	Complete recovery	Not visualized
6	68/F	Pain, total ophthalmoplegia, diabetic retinopathy, blindness	40 × 35	5	No pain, otherwise unchanged	Rim enhancement
7	79/M	Pain, proptosis, total ophthalmoplegia	12 × 20	4	No pain, III–VI still improving at follow-up, minimal residual proptosis	Rim enhancement



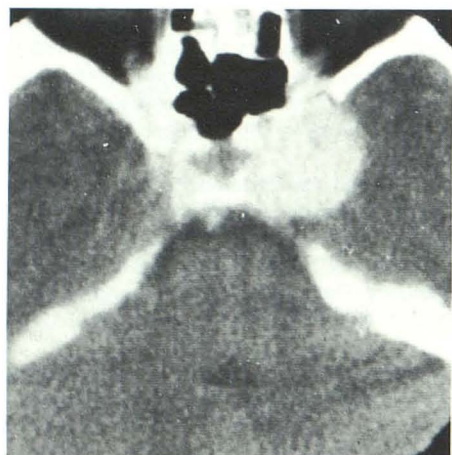
A



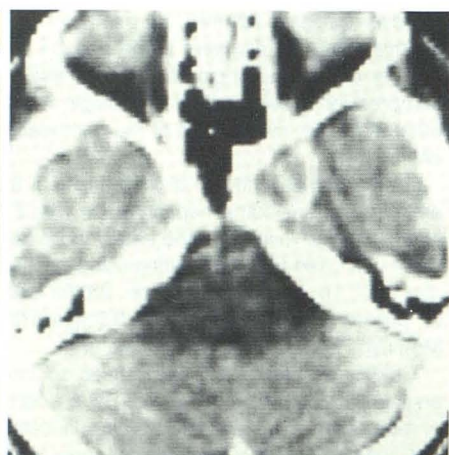
B



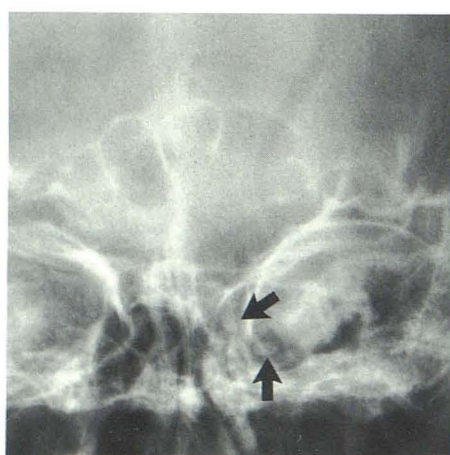C



G



H



I



included late phases to exclude opacification of aneurysms by collateral routes and was performed by aortic arch injection with 4F pigtail catheters introduced via a right brachial approach.

## Results

The clinical presentations and approximate size of the lesions are summarized in Table 1. There were five women and two men, aged 24 to 80 years old, presenting with classical symptoms of intracavernous aneurysms: severe retroorbital pain, proptosis, and extraocular muscle palsies.

Pain relief was the most rapid and constant benefit, occurring in all patients with this symptom (six of six). Proptosis decreased (in three of four patients) or disappeared (in one of four patients). There was complete recovery in both patients with partial extraocular muscle palsy (two of two). In patients with total ophthalmoplegia, the evolution was more varied: unchanged (one of four patients), partial recovery (one of four patients), improved at follow-up (one of four patients), and virtually complete recovery (one of four patients).

At follow-up angiography, the aneurysms remained unopacified in all patients (seven of seven) despite delayed views after aortic arch injections (Fig. 1). Carotid thrombosis, insofar as it can be evaluated by arch angiography, seemed to extend

up to the first functional collateral pathway beyond the aneurysm: ophthalmic artery (in four of seven patients), posterior communicating artery (in one of seven patients), and carotid bifurcation (in two of seven patients) (see Discussion).

Thrombosis of the aneurysm was documented by "rim enhancement" without luminal opacification in all cases (four of four) where the enhancing lumen was seen by CT before surgery. In one patient spectacular collapse of the calcified giant lesion was evident by plain films and CT (Fig. 2). In all other patients, a significant change in the external diameter of the "mass lesion" was difficult to document. The latex balloons had deflated to varying degrees in all patients at the time of follow-up skull radiographs. None had migrated.

There was no spontaneous ischemic event during the 4 to 14 months after embolization.

## Discussion

The development of balloon catheters has allowed the use of an intraluminal approach to vascular lesions at the base of the brain [1-6, 9, 10]. With refinements in technique, obliteration of aneurysms with preservation of the parent artery [4, 6] and "balloon trapping" [5] have become possible. These efforts have sometimes resulted in distal embolization of

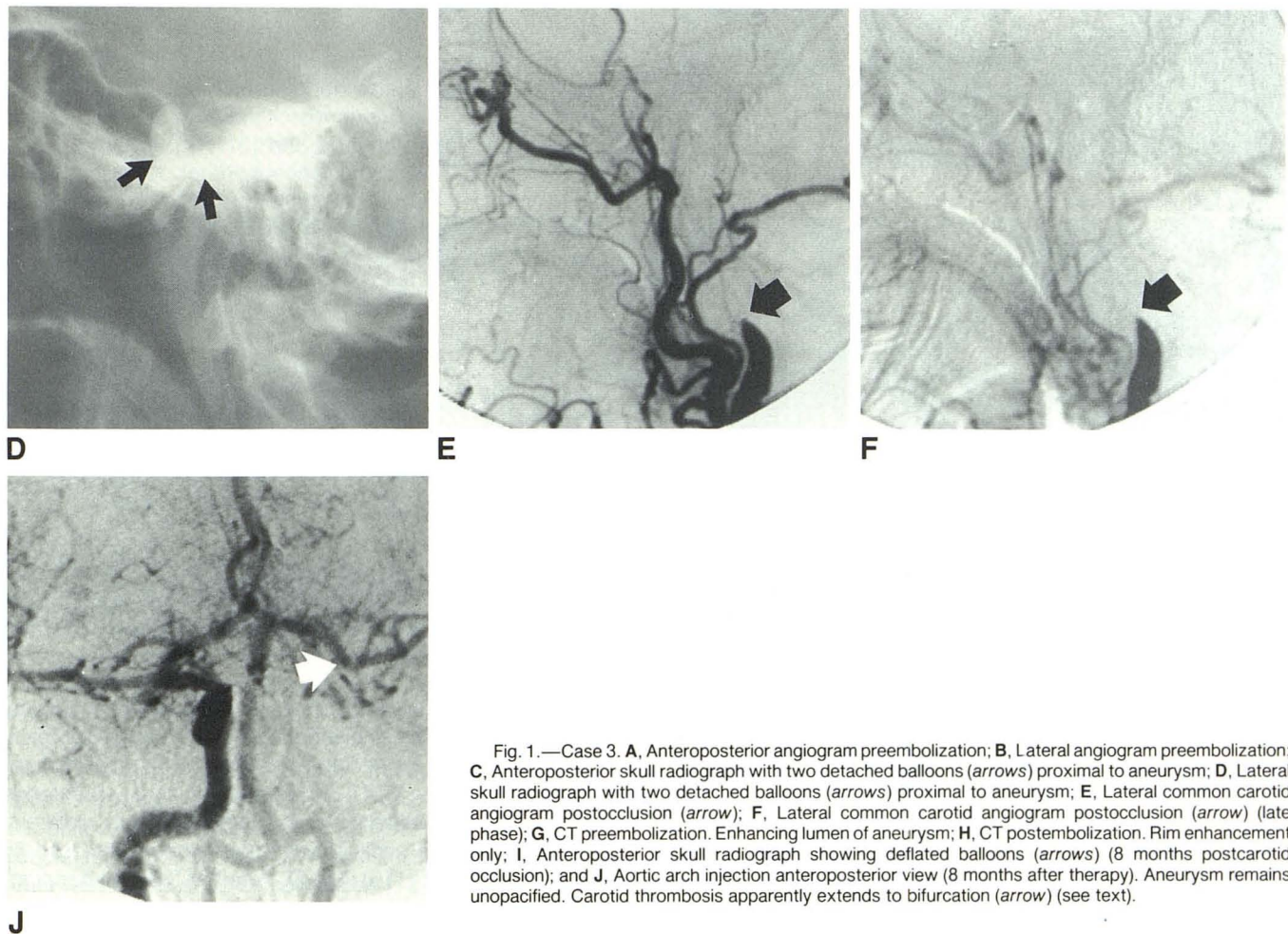


Fig. 1.—Case 3. A, Anteroposterior angiogram preembolization; B, Lateral angiogram preembolization; C, Anteroposterior skull radiograph with two detached balloons (arrows) proximal to aneurysm; D, Lateral skull radiograph with two detached balloons (arrows) proximal to aneurysm; E, Lateral common carotid angiogram postocclusion (arrow); F, Lateral common carotid angiogram postocclusion (arrow) (late phase); G, CT preembolization. Enhancing lumen of aneurysm; H, CT postembolization. Rim enhancement only; I, Anteroposterior skull radiograph showing deflated balloons (arrows) (8 months postcarotid occlusion); and J, Aortic arch injection anteroposterior view (8 months after therapy). Aneurysm remains unopacified. Carotid thrombosis apparently extends to bifurcation (arrow) (see text).



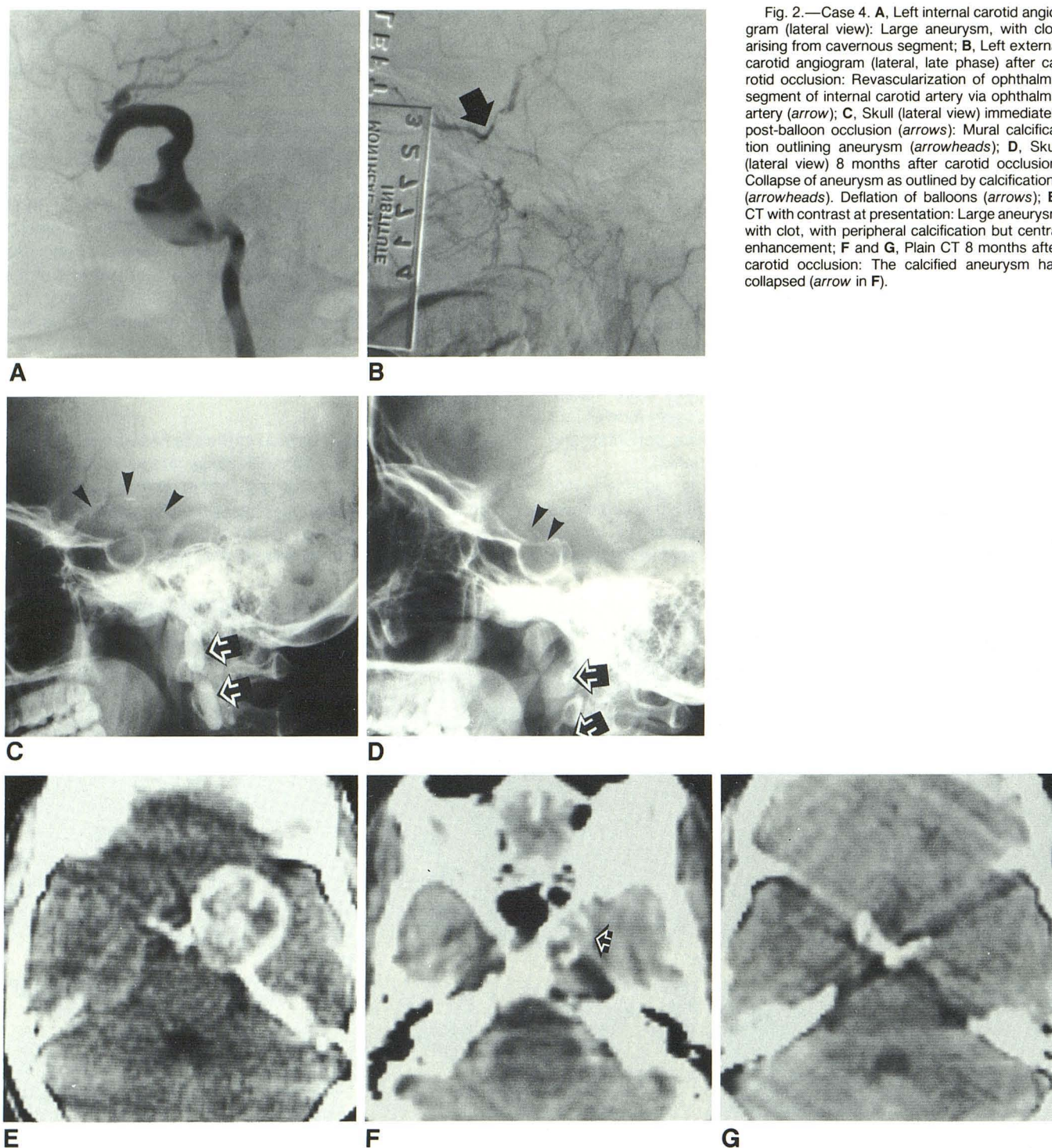


Fig. 2.—Case 4. **A**, Left internal carotid angiogram (lateral view): Large aneurysm, with clot, arising from cavernous segment; **B**, Left external carotid angiogram (lateral, late phase) after carotid occlusion: Revascularization of ophthalmic segment of internal carotid artery via ophthalmic artery (arrow); **C**, Skull (lateral view) immediately post-balloon occlusion (arrows): Mural calcification outlining aneurysm (arrowheads); **D**, Skull (lateral view) 8 months after carotid occlusion: Collapse of aneurysm as outlined by calcifications (arrowheads). Deflation of balloons (arrows); **E**, CT with contrast at presentation: Large aneurysm with clot, with peripheral calcification but central enhancement; **F** and **G**, Plain CT 8 months after carotid occlusion: The calcified aneurysm has collapsed (arrow in **F**).

intraaneurysmal clots [4, 11] and aneurysmal rupture [9]. Furthermore, carotid preservation is usually an impossible goal with giant aneurysms, since the neck often includes the parent artery [4, 5, 8]. Occlusion of the carotid artery immediately at the neck or trapping may present considerable technical difficulty [5]. These techniques carry the same risks of entering the aneurysm and are unnecessary for most intracavernous aneurysms [4, 8, 11, 12]. The location of these

intracavernous aneurysms does not allow a direct surgical approach [13], but, of all giant aneurysms, they are precisely those that most likely become thrombosed by proximal carotid artery occlusion [8, 12–15] because thrombosis extends from the site of occlusion to the first significant collateral branch, beyond the neck of cavernous aneurysms, usually the ophthalmic artery [16] (Fig. 2). Whether “balloon trapping” would prevent delayed embolic episodes is a theoretical ad-



vantage [5] which, in our opinion, does not warrant the risk of entering the aneurysm. After complicated initial attempts at aneurysmal obliteration with preservation of carotid blood flow, Debrun et al. [4] suggested that permanent occlusion of the carotid artery might be a safer alternative, and they eventually followed this course as a second step when they treated three of four cavernous aneurysms. We sacrificed the internal carotid artery as the first step, always keeping the balloon well below the neck of cavernous aneurysms. This avoided a number of complications, corroborating Debrun's predictions.

Technical aspects that differ from one report to another, besides the site of detachment, are balloon content and number of balloons used. We have inflated the balloons with contrast material only. Deflation occurs with time once the carotid artery is thrombosed, as noted in all our patients. We have routinely detached two balloons in order to ensure complete occlusion should one balloon deflate prematurely before organization of the thrombus [17] (Figs. 1 and 2). Although balloon rupture is a possibility, this holds no clinical significance provided that metal markers, tantalum powder, silicone, or methylmetacrylate—all potential embolic materials—are not used [4, 9] and that there is no distal migration of the first balloon.

Since we have purposely eliminated the possibility of preserving the parent artery, our method is, in principle, similar to ligation of the carotid artery and therefore subject to the same criticism discussed at length in the neurosurgical literature [13–15, 18–21]. The major drawback of surgical ligation has been the risk of ischemic complications, observed in 20 to 75% of cases [11, 18] and attributed to either cerebral hypoperfusion or thromboembolization [22]. While similar complications could be expected with balloon occlusion, none of our patients suffered an ischemic event. This may be explained in part by a difference in the patient populations; i.e., large surgical series usually include patients at risk for spasm after subarachnoid hemorrhage [13, 18–20]. When cavernous aneurysms are considered separately, the ischemic complications are less numerous but still more frequent than they have been in our experience [8, 11–15]. Our follow-up periods are relatively short, but 95% of incidents after surgical ligation occur within the first week [11, 18]. We believe the relative safety of the endovascular method may be due to the fact that events leading to thromboembolism [22]—such as long periods of carotid subocclusion with the Silverstone clamp, incomplete ligation, and sudden recanalization, as well as the trauma of exploration and dissection [8, 11, 12, 19, 20]—are avoided.

A common objection to balloon-occlusion techniques is the possible lifetime risk of cerebrovascular insufficiency due to acute irreversible interruption of blood flow through the internal carotid artery. Although the theoretical benefits of the frequently suggested preocclusion extracranial-intracranial by-pass seem sound, this procedure has inherent immediate risks, unnecessarily increases the complexity of treatment in most patients [11, 23], has not always succeeded in decreasing the rate of ischemic complications [12, 15, 23, 24], and has yet to be proven of value in the management of occlusive

cerebrovascular disease [25]. We believe that such preocclusion by-pass surgery is indicated only in patients who have an intolerance to transient balloon occlusion, a situation that was not encountered in our series. A variety of methods for assessing the functional status of the collateral circulation prior to surgical ligation has been advocated, but none is infallible [11, 14, 18, 19, 22–24]. The "Glasgow technique" [26] carries with it an unacceptable rejection rate (24–40%), while still not preventing ischemia in 15% of selected cases. Furthermore, the complication rate for the test procedure alone seems inordinately high [14, 26]. In view of all the uncertain factors remaining in the understanding of cerebrovascular diseases, we seriously question whether a single measurement in an operating room found to be above an arbitrary mathematical value can predict long-term prognosis. The tolerance test most acceptable to us and others [1, 4, 5, 11] consists of a trial occlusion in a closely monitored conscious patient, since it is easily performed by balloon catheters and immediately reversible.

Clinical evolution after our procedure has been most gratifying in six patients; specifically, pain relief was continuous and patients recovered from partial oculomotor and abducens palsies although residual deficits were often present if ophthalmoplegia had been total at the time of surgery, as reported in other series [27]. In one patient (case 6), there was total blindness due to diabetic retinopathy, glaucoma, optic atrophy, and cataracts, and pain relief was the only benefit documented.

Clinical benefits after carotid occlusion probably relate to thrombosis, as demonstrated by CT in four of our cases [28]. While there was a minimal change in overall aneurysm size, we believe there was sufficient size decrease to relieve compression on adjacent structures. A substantial collapse of the aneurysm was documented by CT in only one patient (Fig. 2).

Our patients' progress was best followed by clinical parameters. Digital angiography by aortic arch injections, performed on an out-patient basis, was better accepted by both patients and referring physicians owing to its simplicity and reduced rate of complications. However, the angiographic anatomy was suboptimally assessed. Retrograde flow through the ophthalmic artery probably prevented an extension of the carotid thrombus beyond the aneurysm in all our cases and this flow was clearly visualized in four patients. Thrombotic extension further than that generally seen may explain the nonopacified carotid segments in the other cases. It seems more probable that the nonvisualized segments were patent but functionally hypoplastic and by-passed by physiologically more important collateral pathways, thus remaining undetected by our angiographic technique.

Statistical analysis of our results is difficult because of the small number of patients with intracavernous aneurysms [12]. In addition, such patients should be considered separately from those with giant aneurysms at other sites, a distinction not made in most published reports on the management of these lesions. Nevertheless, this approach resulted in therapeutic success similar to or better, and with fewer complications, than that reported elsewhere using en-



dovascular [3-5, 9-11, 17] and traditional neurosurgical methods, including progressive reversible clamping combined with prophylactic by-pass [8, 11-15, 19-24]. Based on this clinical experience, we would favor proximal balloon occlusion of the carotid artery as the treatment of choice of giant intracavernous aneurysms.

# REFERENCES

- Serbinenko FA. Balloon catheterization and occlusion of major cerebral vessels. *J Neurosurg* 1974;41:125-145
- Serbinenko FA. Six hundred endovascular neurosurgical procedures in vascular pathology. *Acta Neurochir (Wien)* 1979;28:310-311
- Fox AJ, Vinuela FA, Pelz DM, et al. Use of detachable balloon occlusion for the treatment of unclippable cerebral aneurysms (abstr) *AJNR* 1984;5:664
- Debrun G, Fox A, Drake G, Peerless S, Girvin J, Ferguson G. Giant unclippable aneurysms: treatment with detachable balloons. *AJNR* 1981;2:167-173
- Berenstein A, Ransohoff J, Kupersmith M, Flamm E, Graeb D. Transvascular treatment of giant aneurysms of the cavernous carotid and vertebral arteries. Functional investigation and embolization. *Surg Neurol* 1984;21:3-12
- Romodanov AP, Shcheglov VI. Intravascular occlusion of saccular aneurysms of the cerebral arteries by means of detachable balloon catheter. *Tech Standrds Neurosurg* 1983;9:25-49
- Morley TP, Barr HWK. Giant intracranial aneurysms: diagnosis, course and management. *Clin Neurosurg* 1969;16:73-94
- Drake CG. Giant intracranial aneurysms: Experience with surgical treatment in 174 patients. *Clin Neurosurg* 1979;26:12-95
- Scialfa G, Vaghi A, Valsecchi F, Bernardi L, Tonon C. Neuro-radiological treatment of carotid and vertebral fistulas and intracavernous aneurysms: Technical problems and results. *Neuroradiology* 1982;24:13-25
- Taki W, Handa H, Yamagata S, et al. Balloon embolization of a giant aneurysm using a newly developed catheter. *Surg Neurol* 1979;12:363-365
- Sindou M, Keravel Y. Les anévrysmes géants intracrâniens: approches thérapeutiques. *Neurochirurgie* 1984;30(suppl 1):75-110
- Pia HW, Zierski J. Giant cerebral aneurysms: a review of clinical picture, diagnosis and management with illustrative cases. *Neurosurg Rev* 1982;5:117-148
- Sundt TM, Piepgras DG. Surgical approach to giant intracranial aneurysms: operative experience with 80 cases. *J Neurosurg* 1979;51:731-742
- Giannotta SL, McGillicuddy JE, Kindt GW. Gradual carotid artery occlusion in the treatment of inaccessible internal carotid artery aneurysms. *Neurosurgery* 1979;5(4):417-421
- Gelber BR, Sundt TM. Treatment of intracavernous and giant carotid aneurysms by combined internal carotid ligation and extra to intracranial by-pass. *J Neurosurg* 1980;52:1-10
- Castaigne P, Lhermitte F, Gauthier JC, et al. Internal carotid occlusion: a study of 61 instances in 50 patients with post-mortem data. *Brain* 1970;93:231-258
- Théron J. Cas inhabituels de lésions vasculaires du siphon carotidien intracaverneux traités par sonde de Fogarty. *J Neuroradiol* 1980;7:183-191
- Nishioka H. Report on the cooperative study of intracranial aneurysms and subarachnoid hemorrhage: results of the treatment of intracranial aneurysms by occlusion of the carotid artery in the neck. *J Neurosurg* 1966;25:660-682
- Tytus JS, Reifel E, Spencer MP, Burnett LL, Hungerford LN. Common carotid ligation for intracranial aneurysms: results in 26 cases. *J Neurosurg* 1970;32:63-73
- Odom GL, Tindall GT. Carotid ligation in the treatment of certain intracranial aneurysms. *Clin Neurosurg* 1968;15:101-116
- Countee RW, Vijayanathan T, Hubschmann OR, Chavis P. Carotid ligation for recurrent ischemia due to inaccessible carotid obstruction: examination of the rationale of this treatment. *J Neurosurg* 1980;53:491-499
- Landolt AM, Millikan CH. Pathogenesis of cerebral infarction secondary to mechanical carotid artery occlusion. *Stroke* 1970;1:52-62
- Hopkins LN, Grand W. Extracranial-intracranial arterial by-pass in the treatment of aneurysms of the carotid and middle cerebral arteries. *Neurosurgery* 1979;5(1):21-31
- Diaz FG, Ausman JI, Pearce JE. Ischemic complications after combined internal carotid artery occlusion and extracranial-intracranial anastomosis. *Neurosurgery* 1982;10(5):563-570
- The EC/IC By-Pass Study Group. Failure of extracranial-intracranial arterial bypass to reduce the risk of ischemic stroke. Results of an international randomized trial. *N Engl J Med* 1985;313(19):1191-1200
- Jawad K, Miller JD, Wyper DJ, Rowan JO. Measurement of CBF and carotid artery pressure compared with cerebral angiography in assessing collateral blood supply after carotid ligation. *J Neurosurg* 1977;46:185-196
- Kupersmith MJ, Berenstein ISC, Ransohoff J, Flamm ES. Percutaneous transvascular treatment of giant carotid aneurysms: neuro-ophthalmologic findings. *Neurology* 1984;34:328-335
- Pinto RS, Kricheff II, Butler AR, Murali R. Correlation of computed tomographic, angiographic, and neuropathological changes in giant cerebral aneurysms. *Radiology* 1979;132:85-92