



Cervicomedullary hematoma: diagnosis by MR.

M Naseem, S B Zachariah, J Stone and E Russell

AJNR Am J Neuroradiol 1986, 7 (6) 1096-1098

<http://www.ajnr.org/content/7/6/1096.citation>

This information is current as
of July 31, 2025.

Cervicomedullary Hematoma: Diagnosis by MR

Mohammad Naseem,¹ S. B. Zachariah,² J. Stone,³ and E. Russell⁴

CT is often useful for diagnosing primary or secondary brainstem hematoma. However, subacute hemorrhage may be isodense with the normal brain substance, causing a false negative CT study. MR tends to be positive during this phase of hemorrhage. We present an unusual case of an intramedullary hematoma that was not detected by CT but was detected by MR. MR has shown great promise as a neuro-radiologic tool in difficult situations by virtue of its excellent tissue-contrast resolution, a lack of bone artifacts, and direct multiplanar imaging capability [1]. The lack of signal from bone has the advantage that neighboring brain structures, particularly those in the posterior fossa, are not obscured by the linear bone artifacts common to CT scans [2].

Primary hemorrhages of the brainstem commonly involve the pons, less frequently the cerebral peduncle, and rarely, the medulla oblongata [3]. Primary bulbar hemorrhage is usually first identified at autopsy. To our knowledge, there is no known reported case of cervicomedullary hematoma in which antemortem diagnosis was established by any imaging technique. In our case, CT failed to show the lesion but MR clearly identified the hematoma. Timely surgical intervention with evacuation of the hematoma resulted in marked post-operative functional recovery.

Case Report

A 21-year-old right-handed woman was admitted with persistent hiccups, nausea, headache, and generalized weakness of 5 days duration and difficulty in swallowing for the past 2 days. She denied any fever and vomiting.

Shortly after admission, a lumbar puncture revealed 20 WBC/high-power field with 60% polyps and 40% lymphs, and 7500 RBC/high-power field. The patient was empirically treated for tuberculosis. A second lumbar puncture was normal. Electroencephalography revealed background slowing (6–7 Hz) with intermittent frontotemporal delta wave-burst activity. CT brain scans on the day of admission (not shown) were normal; however, the lowest cut was at the level of the lower pons. Bilateral vertebral angiography was normal (Fig. 1). Within 36 hr, the patient became unresponsive and quadriplegic. Generalized tonic clonic seizures developed. Respiratory embarrassment led to tracheostomy. An MR study was performed (Fig. 2), and

T1-weighted short spin-echo images (TR=500 msec, TE=30 msec) showed a very high signal mass within the central medulla consistent with subacute hemorrhage.

A repeat CT examination of the posterior fossa and the upper cervical spine (Fig. 3) revealed slight dilatation of the cervicomedullary junction. The night before surgery, the patient developed a fever of 104°F, so the surgery was postponed. Blood cultures showed staphylococcus epidermidis, and she was started on oxacillin. She was still drowsy and quadriparetic. A portable chest X-ray showed pneumonia in the left lung base. After slight improvement in her general condition, the patient was rescheduled for surgery.

Under general anesthesia, a suboccipital craniotomy and C1–C2 laminectomy were done. The cervicomedullary junction was discolored and bulging. With the aid of an operating microscope, a small myelotomy was made in the right posterior column. Brownish smoky fluid (subacute hemorrhage) was released. The dura was closed with a graft. The patient quickly awakened and began moving all extremities spontaneously. A repeat bilateral vertebral angiogram was normal. She was transferred to a rehabilitation unit, where she showed continued improvement. She is currently ambulatory without assistance.

Discussion

Hematomyelia is defined as a focal extravasation of blood within the substance of the spinal cord, resulting in a nonextending, expansile, limited saccular clot [4]. Hematomyelia can be primary or secondary. The cause of primary hematomyelia is either unknown or due to capillary telangiectasis. The most common cause of secondary hematomyelia is vascular malformation. Other predisposing conditions include poliomyelitis, toxic states, blood dyscrasia (especially when associated with purpura), asphyxia as a sequelae of severe convulsions, and spinal cord injury [5].

A similar classification can be applied to brainstem hematoma, but no such grouping is clearly stated in the literature. Brainstem hematomas can be defined as subependymal or intraaxial. Intraaxial hematomas are not clinically distinguishable from intrinsic brainstem tumors, which are generally not considered suitable for surgery. Primary spontaneous hematomas constitute 13% of the cases in one series [6]. The

Received November 5, 1984; accepted after revision February 23, 1985

¹ Department of Radiology, Cook County Hospital, 1835 W. Harrison St., Chicago, IL 60612. Address reprint requests to J. Naseem.

² Department of Medicine, Division of Neurology, Cook County Hospital, Chicago, IL 60612.

³ Department of Surgery, Division of Neurosurgery, Cook County Hospital, Chicago, IL 60612.

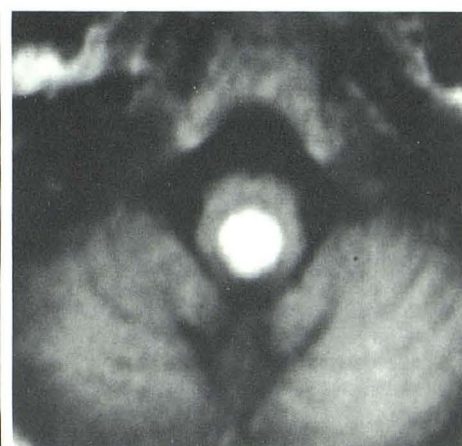
⁴ Department of Radiology, Section of Neuroradiology, Rush-Presbyterian-St. Luke's Hospital, 1753 W. Congress, Chicago, IL 60612.

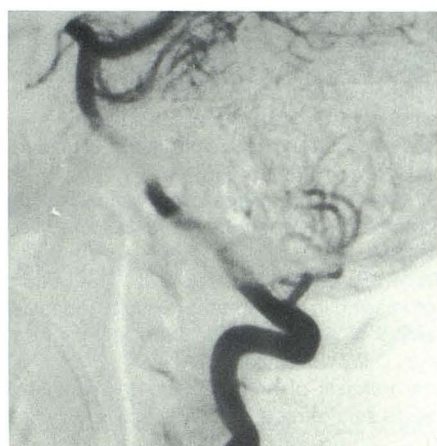
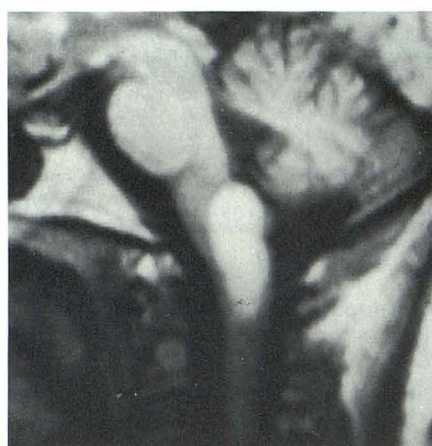
Fig. 1.—Lateral view of vertebral arteriogram shows normal findings.

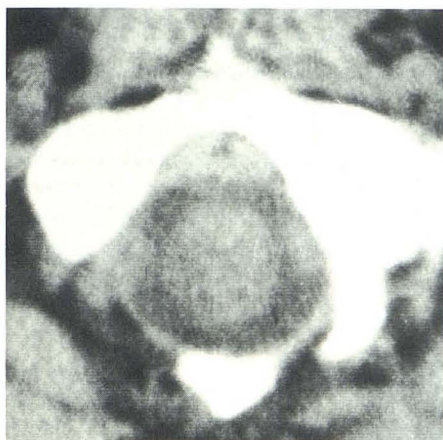


A

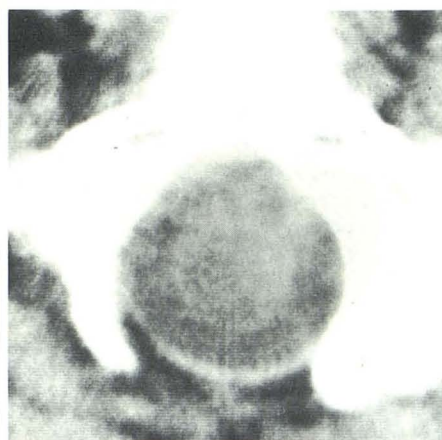


B

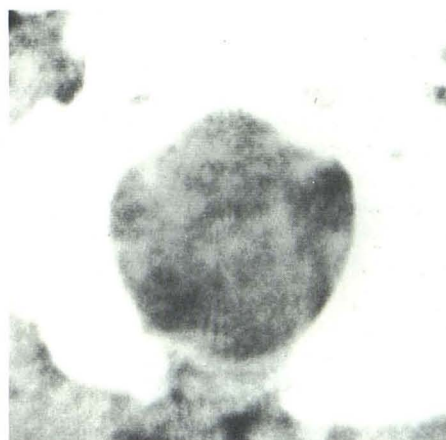
Fig. 2.—**A**, Sagittal T1-weighted MR image (TR = 500 msec; TE = 30 msec) through pons and medulla shows area of high signal density in region of medulla extending into cervicomedullary junction. **B**, Axial T1-weighted MR image above foramen magnum level clearly demonstrates high-intensity lesion with T1 and T2 values consistent with blood. The medullary lesion is slightly posterior and in midline.



A



B



C

Fig. 3.—Noncontrast CT at level of foramen magnum (slice thickness 5 mm with 2-mm overlap between consecutive slices) shows diffuse swelling of medulla and cervicomedullary junction. **A**, Foramen magnum-C1 junction; **B**, Foramen magnum; **C**, Level slightly above **B**.

rostral parts of the brainstem are mostly affected because vascular malformations are more frequent in this region [7]. Medullary hematomas are extremely rare and the pathogenic mechanisms of primary hematomas are not clear [8].

We do not have complete pathologic proof of a bleeding source, but it seems likely that the hematoma was due to the rupture of a microaneurysm of one of the penetrating branches of the basilar or vertebral arteries [7] as suggested by Cole and Yates [9] (though they described a pontomedullary hematoma).

The pathologic examination did not reveal any capillary telangiectasis in our patient. A similar case is described by Donald and Lysia [10].

MR is clearly superior to CT for the identification of sub-

acute hemorrhage. At the time that blood clot is isodense to brain on CT, T1-weighted MR images show very high signal. The only other tissue exhibiting such characteristics on MR is fat. Lipoma is not of serious consideration in the presence of acute intramedullary brainstem expansion, as in this case. MR has also been shown to be superior to CT for the detection of subacute subdural hematoma [11], although acute hemorrhages, which are dense on CT studies, may be less obvious on MR [11].

While the exact figures are unknown, there are isolated case reports with good postoperative results after the evacuation of intramedullary hematoma [7, 12]. An early diagnosis of hematomyelia with successful postoperative results are obtained in six of nine cases in one series [13].

ACKNOWLEDGMENT

We thank Berna Davis for her assistance in manuscript preparation.

REFERENCES

1. Older GM, Steiner RE. Clinical NMR imaging of the brain. *AJNR* **1982**;3:459-80, *AJR* **1982**;139:215-236
2. Gwan Go K, Van Dijk P, Luiten AL, et al. Interpretation of nuclear magnetic resonance tomograms of the brain. *J Neurosurg* **1983**;59:574-584
3. Pendefunda GH, Nemteanu E, Logofatu S. Spontaneous hematoma of the medulla oblongata. *Neurol Psychiatr (Bucur)* **1976**;14:117-181
4. Austin G. *The spinal cord: basic aspects and surgical considerations*, 2nd ed. Springfield, IL: Thomas, **1972**
5. Merrit HH. *Hematomyelia: a textbook of neurology*, 5th ed. Philadelphia: Lea & Febiger, **1973**
6. Richardson JC, Einhorn PW. Primary intracerebral hemorrhage. *Clin Neurosurg* **1963**;9:114-128
7. Obrador S, Dierssen G, Odoriz BJ. Surgical evacuation of a pontine-medullary hematoma: case report. *J Neurosurg* **1970**;33:82-84
8. Mastaglia FL, Edis B. Medullary hemorrhage: a report of two cases. *J Neurol Neurosurg Psychiatry* **1962**;32:221-225
9. Cole FM, Yates PO. The occurrence and significance of intracranial microaneurysm. *J Pathol* **1967**;93:393-411
10. Donald FF, Lysia SF. Symptomatic capillary telangiectasis of the brainstem without hemorrhage: report of an unusual case. *Neurology* **1970**;20:341-346
11. Zimmerman RD, Robert S, Samuel G, Deck MDF. The value of magnetic resonance imaging in head trauma (exhibit). Presented at the annual meeting of the Radiological Society of North America, Washington, D.C., November **1984**
12. Kempe LG. Surgical removal of an intramedullary hematoma simulating Wallenberg's syndrome. *J Neurol Neurosurg Psychiatry* **1964**;27:78-80
13. Kitahara T, Miyasakay NSG. An operated case of cervical spontaneous hematomyelia (abstr). *No To Shinkei* **1982**;10(6):675-679