



Get Clarity On Generics

Cost-Effective CT & MRI Contrast Agents

 FRESENIUS
KABI

[WATCH VIDEO](#)

AJNR

The ascending pharyngeal artery: a collateral pathway in complete occlusion of the internal carotid artery.

D M Pelz, A J Fox, F Viñuela, J E Dion and L Agnoli

AJNR Am J Neuroradiol 1987, 8 (1) 177-178

<http://www.ajnr.org/content/8/1/177.citation>

This information is current as
of August 7, 2025.

cavernous sinuses acute inflammation, granulation tissue, and thrombus surrounded the nerves and internal carotid arteries. The left carotid artery was intact, but focally inflamed. The right internal carotid artery was focally necrotic, acutely inflamed and ruptured, with hemorrhage emanating from the defect.

Discussion

We are not aware of any instances of air within the cavernous sinus in a normal patient or after trauma. Our case demonstrates several of the reported findings in cavernous sinus thrombosis including bulging of the lateral walls, irregular low-attenuation filling defects within the cavernous sinus, and proptosis (Fig. 1).

It is unclear whether the air within the sinus originated from a gas-forming organism or via direct extension from one of the sinuses via the veins. The organisms that were cultured from the blood and sinus postmortem can be associated with gas formation. The presence of a large amount of fat within the cavernous sinus was reported by Bachow et al. [4] in patients with Cushing disease. Careful measurement of the CT HU will discriminate between the two, since fat has a value of minus 60 HU, whereas air, as in our case, has a value of minus 200 HU or greater.

Narrowing or occlusion of the carotid artery associated with cavernous sinus thrombosis has been well documented in the literature [2, 5]. In addition, aneurysms associated with septic emboli to the cerebral vasculature have been reported. However, a mycotic aneurysm involving the cavernous carotid artery secondary to bacterial invasion of the wall is a previously unrecognized complication. It is likely that a septic embolus from this aneurysm led to the infarction. While angiography in the diagnosis of cavernous sinus thrombosis is of limited value, it may be indicated to exclude such aneurysm formation or even carotid occlusion, particularly in cases of cerebral infarction.

John T. Curnes
Jeff L. Creasy
Robert L. Whaley
James H. Scatliff

University of North Carolina School of Medicine
Chapel Hill, NC 27514

REFERENCES

1. Ahmadi J, Keane JR, Segall HD, Zee C. Observations pertinent to septic cavernous sinus thrombosis. *AJNR* 1985;6:755-758
2. Segall HD, Ahmadi J, McComb JG, Zee CS, Becker TS, Han JS. Computed tomographic observations pertinent to intracranial venous thrombotic and occlusive disease in childhood. *Radiology* 1982;143:441-449
3. Clifford-Jones RE, Ellis CJK, Stevens JM, Turner A. Cavernous sinus thrombosis. *J Neurol Neurosurg Psychiatry* 1982;45:1092-1097
4. Bachow TB, Hesselink JR, Aaron JO, Davis KR, Taveras JM. Fat deposition in the cavernous sinus in Cushing disease. *Radiology* 1984;153:135-136
5. Matthew NT, Abraham J, Taori GM, Iyer GV. Internal carotid artery occlusion in cavernous sinus thrombosis. *Arch Neurol* 1971;24:11-16

The Ascending Pharyngeal Artery: A Collateral Pathway in Complete Occlusion of the Internal Carotid Artery

The ascending pharyngeal artery is the smallest branch of the external carotid artery [1], but it is one of the most important branches because of the structures it supplies and the collateral pathways in

which it participates. This report describes two cases in which common carotid angiography showed complete occlusion of the internal carotid artery at its origin. Subsequent vertebral angiography in both cases showed reconstitution of this vessel several millimeters above the origin by the ascending pharyngeal artery, which had an unusual origin from the internal carotid artery [2]. Endarterectomy as a technical option was feasible in both cases because the occluded segments were only millimeters in length.

The first patient, a 59-year-old man, presented 5 days before admission with a sudden paresis of the right arm and leg. Angiography revealed complete occlusion of the left internal carotid artery with a small, smooth stump (Fig. 1A). A left vertebral arteriogram demonstrated reconstitution of the left internal carotid artery just above the occlusion (Fig. 1B). Collateral supply was from muscular branches of the vertebral artery, which anastomosed with muscular branches of the ascending pharyngeal artery. This vessel, which originated from the proximal internal carotid artery, maintained patency of the carotid artery throughout its length (Fig. 1C).

The second patient, a 61-year-old man, had experienced an episode of light headedness and left-sided weakness 1 month before admission. Angiography revealed bilateral internal carotid artery occlusions and the left vertebral study showed reconstitution of a patent left internal carotid artery via the ascending pharyngeal artery, which again originated from the proximal internal carotid artery.

In both cases, the ascending pharyngeal arteries functioned as important collateral pathways, maintaining patency of proximally occluded internal carotid arteries. The continued patency was made possible by the unusual origin of the ascending pharyngeal artery from the internal carotid artery in both cases.

The ascending pharyngeal artery most commonly arises from the posterolateral aspect of the proximal external carotid artery, close to the origin of the lingual artery and just below that of the occipital artery [3]. There are several variations in its point of origin, the most common being (a) from the carotid bifurcation in the angle between the internal and external carotid arteries, (b) from the internal carotid artery above its origin, sometimes paired with the occipital artery, and (c) from the external carotid artery, combined with the occipital artery or just above it. The anterior branch of this vessel supplies pharyngeal and palatine tissues. The posterior branch gives important meningeal supply to the skull base and muscular branches to the prevertebral muscles. These muscular branches can anastomose with branches originating from the occipital and vertebral arteries and it was these muscular anastomoses from the vertebral artery that provided the collateral channels in our two cases.

It is well known that it is important to perform vertebral angiography in cases of proximal common carotid occlusion, since vertebral-to-occipital artery collaterals may keep the ipsilateral internal carotid artery patent [4]. Similarly, one should be aware of potential collateral pathways through anatomic variants of the ascending pharyngeal artery. Vertebral angiography, therefore, should be considered in cases of proximal internal carotid artery occlusion when the ascending pharyngeal artery has not been clearly identified as a branch from the ipsilateral external carotid artery on the common carotid angiogram.

David M. Pelz
Allan J. Fox
Fernando Viñuela
Jacques E. Dion
L. Agnoli

University Hospital, University of Western Ontario
London, Ontario, Canada N6A 5A5

REFERENCES

1. Salamon G, Faure J, Raybaud C, Grisoli F. The external carotid artery. In: Newton TH and Potts DG, eds. *Radiology of the skull*

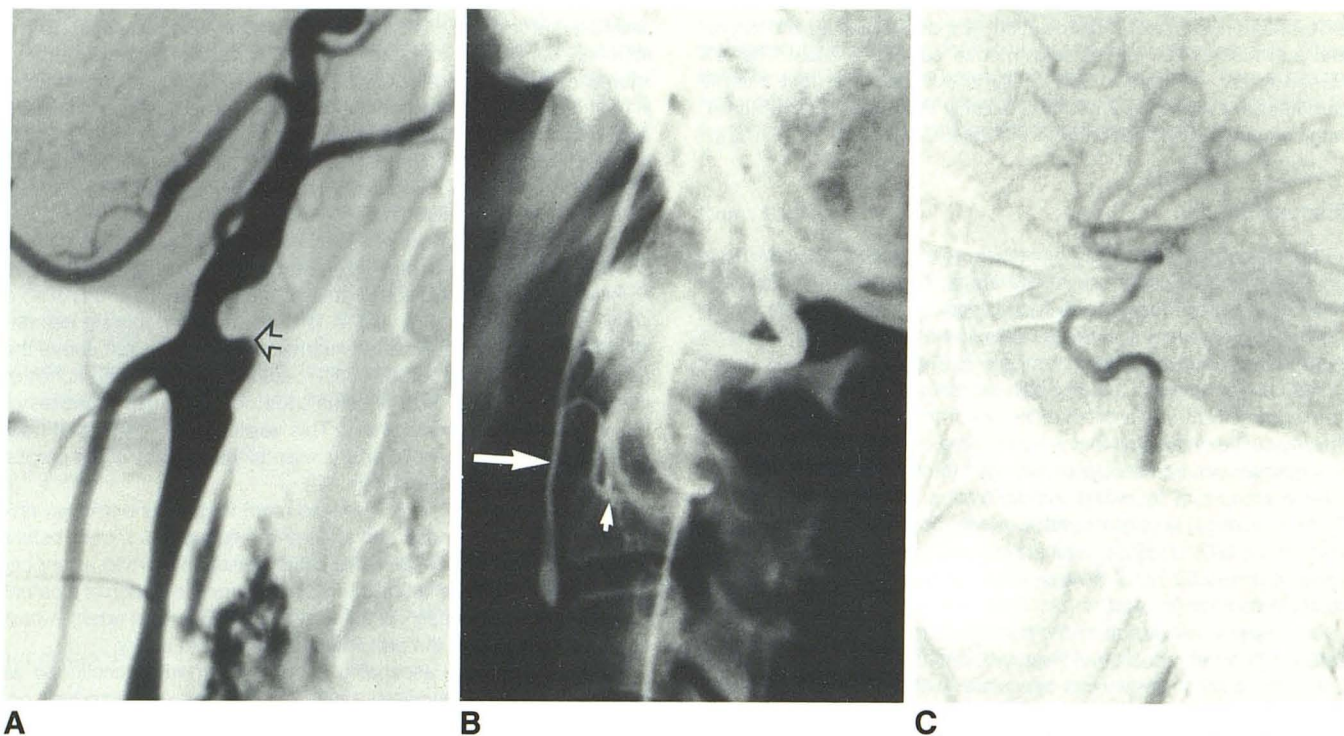


Fig. 1.—A, Case 1. Lateral left common carotid arteriogram shows complete occlusion of left internal carotid artery at its origin (arrow). B, Lateral left vertebral arteriogram. Muscular collaterals from vertebral artery anastomose with muscular branches of ascending pharyngeal artery (small arrow). There is reconstitution of left internal carotid artery (large arrow) via ascending pharyngeal artery. C, A late film in the series shows patency of intracranial portion of left internal carotid artery.

and brain. Vol 2. St. Louis: Mosby, 1974:1254–1258

2. Djindjian R, Merland JJ. Normal super-selective arteriography of the external carotid artery. In: *Super-selective arteriography of the external carotid artery*, 1st ed. Heidelberg: Springer-Verlag, 1978:14–17
3. Lasjaunias P, Moret J. The ascending pharyngeal artery: normal and pathological radioanatomy. *Neuroradiology* 1976;11:77–82
4. Lasjaunias P. The pharyngo-occipital collateral pattern. In: *Craniofacial and upper cervical arteries. Collateral circulation and angiographic protocols*. Baltimore: Williams & Wilkins, 1983: 55–64

MR Imaging of Moyamoya in Neurofibromatosis

Intracranial arterial occlusions in patients with neurofibromatosis have been well described in the literature [1–4]. We describe the MR imaging appearance of moyamoya changes in a patient with carotid occlusive disease due to neurofibromatosis.

Case Report

A 4-year-old black girl was admitted to the hospital in 1981 with a history of dragging of the left arm and leg since the morning of admission. Neurologic examination confirmed a moderate left hemiparesis. The child and her mother both had multiple large cafe-au-lait spots. CT showed an area of decreased attenuation in the right basal ganglia with abnormal enhancement. Cerebral angiography was performed during this hospital admission. Gradual improvement of the patient's left hemiparesis occurred. The patient was readmitted at

age 5, again with a 2-day history of gradually progressing left-sided weakness. CT scan showed multiple focal infarcts in both cerebral hemispheres. One month later, gradually increasing right-sided weakness and an expressive aphasia developed. An MR study was obtained 4 years after her last stroke.

Discussion

Primary cerebral arterial stenotic and occlusive disease is a well-known but relatively infrequent manifestation of neurofibromatosis. The typical angiographic findings consist of smooth constricting lesions and/or occlusions involving the supraclinoid internal carotid arteries and proximal arterial segments of the circle of Willis. The collateral circulation, which consequently develops, is provided by corticocortical-end artery anastomotic pathways, transdural external-internal carotid communications, and proliferation and hypertrophy of deep perforating vessels in the basal ganglia and thalami. These latter vessels produce a telangiectatic collection of small capillary and arterial vessels at the base of the brain, which has been described as having a moyamoya or misty or hazy appearance [5, 6]. This constellation of angiographic findings was originally described as moyamoya disease in children and young adults of Japanese origin. A moyamoya pattern of vascular changes has since become recognized, however, in a wide variety of patients with cerebral arterial occlusions at a young age, including patients with meningitis, sickle-cell disease, neurofibromatosis, and other neurocutaneous syndromes.

In the present case, carotid angiography revealed smooth stenosis of the supra clinoid segment of the right internal carotid and high-