



Discover Generics

Cost-Effective CT & MRI Contrast Agents



[VIEW CATALOG](#)

AJNR

Radiographic Characteristics of Skull Fractures Resulting from Child Abuse

Clifford J. Meservy, Richard Towbin, Robert L. McLaurin, Patricia A. Myers and William Ball

AJNR Am J Neuroradiol 1987, 8 (3) 455-457

<http://www.ajnr.org/content/8/3/455>

This information is current as of September 11, 2025.

Radiographic Characteristics of Skull Fractures Resulting from Child Abuse

Clifford J. Meservy^{1,2}
 Richard Towbin^{1,4}
 Robert L. McLaurin^{3,4}
 Patricia A. Myers⁵
 William Ball^{1,4}

Radiographic characteristics of skull fractures in 39 cases of documented child abuse were compared with skull fractures in 95 cases of accidental injury to determine if differential features could be identified. All children were less than 2 years old. Emergency room and hospital records for these patients were also reviewed. The results of this study show that clinical features did not provide any clues as to whether the children had been injured by abuse or by accident. However, it was found that multiple fractures, bilateral fractures, and fractures crossing sutures occurred significantly more often in abuse cases than in accidental injury. When such fractures are present, abuse should be suspected.

The ability to identify child abuse constitutes an important concern to those involved in the medical care of children. Estimates of the number of cases of physical abuse occurring yearly in the United States range from 585,000 [1] to 1.7 million [2]. Studies show that at least 10% of children under 5 years old who are brought to the emergency room with alleged accidents have actually suffered nonaccidental trauma [3]. Since as many as 65% of all abuse cases are initially seen in the emergency room [4], the first step in correctly identifying abuse is to train hospital staff members to recognize abuse indicators. Radiographic findings of suspected child abuse have been described in the literature [5–7]. The importance of these findings is enhanced when features are identified that enable one to differentiate injuries occurring in abuse from those occurring in accidental injury. This differentiation gives the radiographic studies great import from the clinical, social, and medicolegal standpoints. Previous reports have not described the differential features between the radiographic appearance of skull fractures that result from abuse and those that result from accidental injury [8–11]. Skull fractures in abused children have been described as simple linear fractures most commonly occurring in a parietooccipital location. Depressed, comminuted, and diastatic fractures are uncommon. However, Hobbs [12] has recently reported that skull fractures resulting from child abuse often have features that make the skull radiograph an important asset in differentiating suspected child abuse from accidental trauma. We reviewed 134 pediatric cases of skull fracture to determine if Hobbs' observations are reproducible in a nonselected population.

Subjects and Methods

Radiographs of skull fractures in 134 children under 2 years of age were reviewed. The injuries all occurred between January 1981 and December 1985. Of this group, 39 had skull fractures resulting from abuse and 95 suffered accidental injury. Suspected abuse cases were referred to the multidisciplinary child abuse team for assessment. The major criteria for referral included (1) inadequate, unlikely, or no explanation of the child's injury, (2) history of injury inconsistent with the child's development, (3) discrepancy in history given by caretakers or other family members, (4) multiple injuries or injuries of various ages, (5) past history of suspicious injuries or previous abuse reports, (6) delay in seeking medical treatment, (7) the

This article appears in the May/June 1987 issue of *AJNR* and the July 1987 issue of *AJR*.

Received July 22, 1986; accepted after revision October 7, 1986.

¹ Department of Radiology, University of Cincinnati College of Medicine, Cincinnati, OH 45229.

² Present address: Department of Radiology, LeBonheur Children's Medical Center, 848 Adams Ave., Memphis, TN 38103. Address reprint requests to R. Towbin.

³ Department of Neurosurgery, University of Cincinnati College of Medicine, Cincinnati, OH 45229.

⁴ Department of Pediatrics, University of Cincinnati College of Medicine, Cincinnati, OH 45229.

⁵ Department of Social Service, Children's Hospital Medical Center, Cincinnati, OH 45229.

AJNR 8:455–457, May/June 1987

0195–6108/87/0803–0455

© American Society of Neuroradiology

child's response to medical examination, since an abused or neglected child frequently accepts procedures in a passive manner, and (8) parent-child interactions suggesting lack of parental concern.

Motor vehicle accidents were not included, as these events are quite easily identified and would not be confused with abuse. Therefore, all patients included in this study were initially suspected to be possible victims of abuse. Children who did not meet the criteria established for identification of abuse were presumed to have sustained accidental injury. However, we have no absolute criteria for identification of accidental injury. It is possible, therefore, that cases of undetected abuse may have been included in the group of accidental injury cases.

With rare exceptions, accidental injury occurred by falling down stairs; by being dropped while carried; or by falling from a raised surface, such as a changing table, couch, or bed.

Skull fractures were evaluated for site, size, number, depression, configuration, and patient age at time of fracture. The classification of configuration was described by Hobbs [12]. He described both a single linear and complex type of fracture. A single linear fracture is a single unbranched line in straight, zigzagged, or angled configuration. A complex fracture consists of two or more distinct fractures of any type or a single fracture with multiple components. Branched linear fractures are included in this category.

The incidence of each parameter was examined in the two groups of patients. The results were subjected to statistical analysis, and *p* values were determined.

The emergency room and hospital records were reviewed for the entire group of 39 abused infants and a random series of 42 accidentally injured infants. The purpose of this review was to determine if there were any distinguishing features on clinical presentation that might serve as clues to the method of trauma. The specific features noted included the neurologic state on arrival (especially the level of consciousness), external evidence of trauma about the head and neck, and the presence or absence of retinal hemorrhages.

Results

Thirty-nine cases of abuse and 95 cases of accidental injury were included in the study. Eighty-five percent of each group was under 12 months old. Owing to the presence of multiple fractures, there were 56 total fractures in the abused population and 104 in the accidentally injured children. Fractures ranged in length from 1 to 12 cm in both groups. The parietal bone was the most common site of fracture in both groups, occurring in 49 of 56 (87.5%) abused children and 95 of 104 (91.3%) of those accidentally injured.

No significant differences between the effects of abuse and accidental injury were identified with regard to (1) nonparietal fracture, (2) depressed fracture, (3) diastatic fracture ≥ 3 mm, and (4) complex fracture (Table 1).

Despite these similarities of skull fracture, we found three

characteristics that were more frequent after trauma of abuse than after accidental injury. These characteristics were (1) multiple fractures, (2) bilateral fractures (Fig. 1), and (3) fractures that cross sutures (Fig. 2 and Table 2).

Clinical features reviewed did not provide any clues as to whether the individual had been injured by abuse or by accident. All but three of the abused infants were conscious on admission although a few were reported to have mild lethargy or irritability. Of the accidentally injured patients, one was comatose on arrival. In both groups the most common external signs of trauma were scalp swelling and discoloration in the parietal region. Scalp lacerations were rarely seen in either group. Depression of the skull was usually not detected until radiologic study because of overlying hematoma. Retinal hemorrhages were seen initially in one abused infant and in one case of accidental injury. It was not surprising that retinal hemorrhages were not more common in the abused infants since this characteristically occurs in the "shaken baby" syndrome, which is usually not associated with skull fracture.

Review of the presenting and follow-up social histories from the caretakers of abused children indicated that in 33% of cases no history of trauma could be determined (i.e., "I just found him that way"). In a surprising percentage of cases (15%) some history of specific abuse or neglect was elicited (i.e., "I think my boyfriend might have hurt him"). Other histories included falling from a bed, couch, or other low surface. Fairly frequently, the history was conflicting; less commonly, it was inconsistent or changed (Table 3).

Discussion

The skull radiograph has been of use in clinical and legal matters for identification of the presence of skull fractures but until recently has been considered of little value in differentiating abuse from accidental injury. Hobbs has reported specific characteristics that he found to occur more frequently in abuse than in accidental injury. These include: (1) depressed fractures, (2) diastatic fractures ≥ 3 mm in width, (3) nonparietal fractures, (4) fractures having the complex configuration, (5) multiple calvarial fractures, (6) bilateral fractures, and (7) fractures that cross sutures. Abuse is suggested by the presence of one or more of these features. He stated that most of his cases of abuse had more than two of these features, while most of his cases of accidental injury had none. However, no statistical information was given to support his conclusions. He also reported that a depressed occipital fracture is virtually pathognomonic of abuse.

Hobbs' study appears to be biased toward severe abuse. The study included 29 cases of abuse of which 13 were obtained through the Department of Forensic Medicine. Six of the remaining 16 cases also were fatal. Our group of patients represents a more typical cross section of less severely injured children seen at a community hospital.

In contrast to Hobbs' observations, our results indicate that there are no significant differences between the appearance of skull fractures in abuse and accidental injury with regard to (1) depressed fractures, (2) diastatic fractures ≥ 3 mm, (3) nonparietal fractures, and (4) fractures having the complex

TABLE 1: Fracture Characteristics of No Statistical Significance

	Abuse (n = 39)	Accidental Injury (n = 95)	<i>p</i> Value
Nonparietal fracture	1 (2.6%)	6 (6.3%)	0.6461
Depressed fracture	6 (15.4%)	12 (12.6%)	0.8842
Diastatic fracture ≥ 3 mm	6 (15.4%)	14 (14.8%)	0.8640
Complex fracture	9 (23.1%)	12 (12.6%)	0.2116

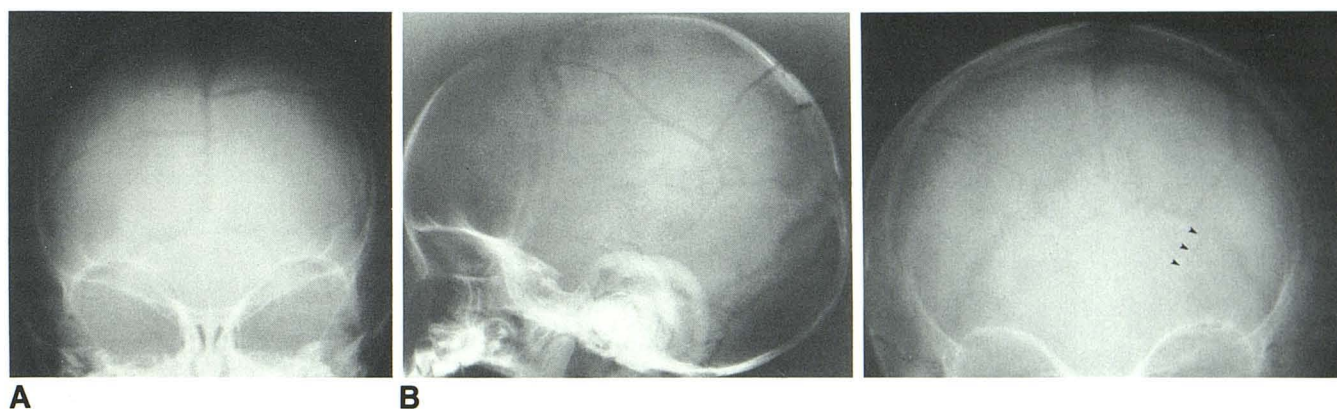


Fig. 1.—8-month-old abused boy. Anteroposterior (A) and lateral (B) skull radiographs reveal multiple, bilateral parietal fractures.

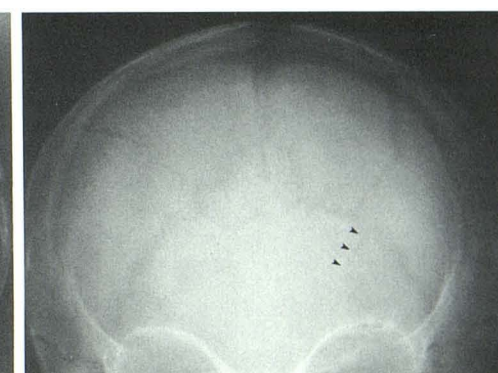

Fig. 2.—6-month-old abused girl. Multiple, bilateral skull fractures. Left parietal fracture crosses lambdoid suture (arrowheads).

TABLE 2: Fracture Characteristics of Statistical Significance

	Abuse (n = 39)	Accidental Injury (n = 95)	p Value
Multiple fractures	12 (30.8%)	9 (9.5%)	0.0036
Bilateral fractures	7 (18%)	5 (3.2%)	0.0395
Fractures crossing sutures	10 (25.6%)	9 (9.5%)	0.0264

TABLE 3: History Given in 39 Cases of Suspected Child Abuse

Description	n
No history of trauma	13 (33.3%)
History of fall from bed, couch, or other low surface	10 (25.6%)
Conflicting history that later appeared to be abusive	7 (17.9%)
History indicating abuse or neglect	6 (15.3%)
Inconsistent or changed history	3 (7.6%)

configuration. Our one patient with a depressed occipital fracture sustained this in accidental injury.

Several of the characteristics described by Hobbs were reproduced in our study. In spite of his apparent bias toward severe abuse, we concur with Hobbs in his opinion regarding the differential significance of certain radiologic features. These features are (1) multiple fractures, (2) bilateral fractures, and (3) fractures that cross suture lines. These occurred much more frequently in abuse and were found to be statistically significant with p values $< .05$.

The clinical presentation was of no help in distinguishing whether the infant had been injured by abuse or by accident.

Frequently, there was either no stated history of trauma or only a minor fall. We therefore conclude that one must suspect abuse when skull fractures are identified that are multiple, bilateral, or cross suture lines. This suspicion is greatly enhanced when there is no history of trauma or when only a minor fall is reported. Awareness of the characteristics of abuse and a well-defined hospital protocol for suspicious cases is essential for identification.

REFERENCES

1. The American Humane Association, Child Protective Division. *National analysis of official child neglect and abuse reporting 1982*. Denver: American Humane Association, 1982
2. Straus MA. Family patterns and child abuse in a nationally representative sample. *Child Abuse Negl* 1979;3:213-225
3. Schmitt B. *The child protection team handbook*. New York: Garland STPM Press, 1978:23-24
4. Deitz S, Shetty M, Cary T. Child abuse: a physician's guide. *Generics* 1985;1(3):15-22
5. Caffey J. Multiple fractures in the long bones of infants suffering from chronic subdural hematoma. *AJR* 1946;56:163-173
6. Silverman FN. The roentgen manifestations of unrecognized skeletal trauma in infants. *AJR* 1953;69:413-427
7. Kempe CH, Silverman FN, Steele BF, et al. The battered child syndrome. *JAMA* 1962;181:105-112
8. Merten DF, Osborne DRS, Radkowski MA, Leonidas JC. Craniocerebral trauma in the child abuse syndrome: radiological observations. *Pediatr Radiol* 1984;14:272-277
9. Merten DF, Radkowski MA, Leonidas JC. The abused child: a radiological reappraisal. *Radiology* 1983;146:377-381
10. Helfer RE, Slovis TL, Black M. Injuries resulting when small children fall out of bed. *Pediatrics* 1977;60:533-535
11. Silverman FN. Unrecognized trauma in infants, the battered child syndrome and the syndrome of Ambrose Tardieu. *Radiology* 1973;104:337-350
12. Hobbs CJ. Skull fracture and the diagnosis of abuse. *Arch Dis Child* 1984;59:246-252