



## Discover Generics

Cost-Effective CT & MRI Contrast Agents



FRESENIUS  
KABI

WATCH VIDEO

# AJNR

## Cervicocephalic fibromuscular dysplasia and fenestration of the vertebral artery.

Y Numaguchi, M S Fleming and E F Vargas

*AJNR Am J Neuroradiol* 1987, 8 (3) 573-574

<http://www.ajnr.org/content/8/3/573.citation>

This information is current as  
of June 25, 2025.

cerebral and anterior communicating arteries. The coils remained in the same position (arrow in Fig. 2).

The use of transvascular methods to occlude the internal carotid artery in treating giant aneurysms is advantageous compared with surgical ligation or progressive clamping of the vessel because the occlusion may be realized more distally, which reduces the length of the thrombus, and because the procedure may be performed in an alert patient, testing his condition during a temporary occlusion. Furthermore, since it is generally believed that the ischemic events occurring after iatrogenic carotid occlusion are of embolic origin, there are no advantages in performing a gradual closure that increases the risk of dislodgement of emboli.

In those cases in which a complete, abrupt, proximal occlusion of the internal carotid artery is required, the stainless steel coil is, perhaps, the most suitable device; it is fast, safe, simple, and stable. There is no advantage under such conditions for using detachable balloons, which require larger catheters, are more expensive, are not always available, tend to deflate, and exert a less thrombogenic effect. Hence, the steel coils might be preferred both in an emergency and when a detachable balloon is not available, as well as in all cases in which the purpose is only to close the carotid artery proximally.

The usefulness of extracranial-intracranial bypass as a preamble to carotid artery occlusion is disputable, especially in young patients. The natural pathways of supply are usually more effective than any bypass, compensating for the perfusion deficiency in the carotid territories, as a complete angiographic exploration and a temporary occlusion of the artery may demonstrate. The problem is obviously quite different when the preoperative evaluation discloses that the physiological short-term anastomoses are unable to supply the new needs, making a bypass operation obligatory. The risk of another operation that is even more invasive than the principal one and the questionable short-term prophylactic effect on ischemia, are important issues that still need to be resolved, as shown by Braun et al. [1]. Despite a well-functioning superficial temporal artery to middle cerebral artery (STA-MCA) bypass, performed at a suitable time (just before the carotid ligation), ischemia developed in the cerebral carotid territory. Recent reports, carefully reviewed by Heros [3] in his article detailing the experience of 30 neurosurgeons, actually suggest that a patent extracranial-intracranial bypass graft is not sufficient to protect the hemisphere against the effect of thromboembolism. On the contrary, a recently performed bypass operation may prevent us from carrying out the more effective prophylactic measure, which is systemic anticoagulation.

Renato Spaziante  
Universita Degli Studi Di Napoli  
Napoli, Italy 80131

## REFERENCES

1. Braun IF, Hoffman JC Jr, Casarella WC, Davis PC. Use of coils for transcatheter carotid occlusion. *AJNR* 1985;6:953-956
2. Spaziante R, De Chiara A, Iaccarino V, Stella L, Benvenuti D, Giamundo A. Intracavernous giant fusiform aneurysm of the carotid artery treated with Gianturco coils. *Neurochirurgia (Stuttgart)* 1986;29:34-41
3. Heros RC. Thromboembolic complications after combined internal carotid ligation and extra- to intra-cranial bypass. *Surg Neurol* 1984;21:75-79

## Abbreviated Reports

### Cervicocephalic Fibromuscular Dysplasia and Fenestration of the Vertebral Artery

Fibromuscular dysplasia (FMD) of the cervicocephalic arteries is not rare; more than 400 cases have been reported. FMD's association

with aneurysms or arteriovenous malformations has been documented [1]. However, FMD's association with fenestration or partial duplication of the cervicocephalic artery has not been reported in the scientific literature.

## Case Report

A 65-year-old hypertensive woman was admitted for evaluation of intermittent transient dysesthesia of the right side of her face and right upper extremity. A physical examination on admission revealed no significant neurologic abnormalities, nor was any significant abnormality detectable on CT of the brain.

Bilateral carotid and left vertebral angiograms and an arch aortogram showed the "string of beads" appearance and tubular stenosis characteristic of FMD in the internal carotid and vertebral arteries (Fig. 1A). A small saccular aneurysm was also noted in the cavernous segment of the right internal carotid artery. In addition to these findings, there was localized fenestration in the left vertebral artery at the level of the third and fourth cervical vertebrae (Fig. 1B).

## Discussion

Cervicocephalic FMD most frequently involves the internal carotid artery. Characteristically, angiography reveals a "string of beads" appearance or tubular stenosis, which is pathognomonic of FMD. FMD of the cervicocephalic artery is frequently associated with intracranial aneurysms in 39-51% of cases [1].

Fenestration of the vertebral arteries is observed in 0.2-5% of cases on angiography or at autopsy. It is more frequently reported in Japan [2-4]. The association of fenestration of the vertebral artery and intracranial aneurysms has been observed in approximately 20% of cases [4].

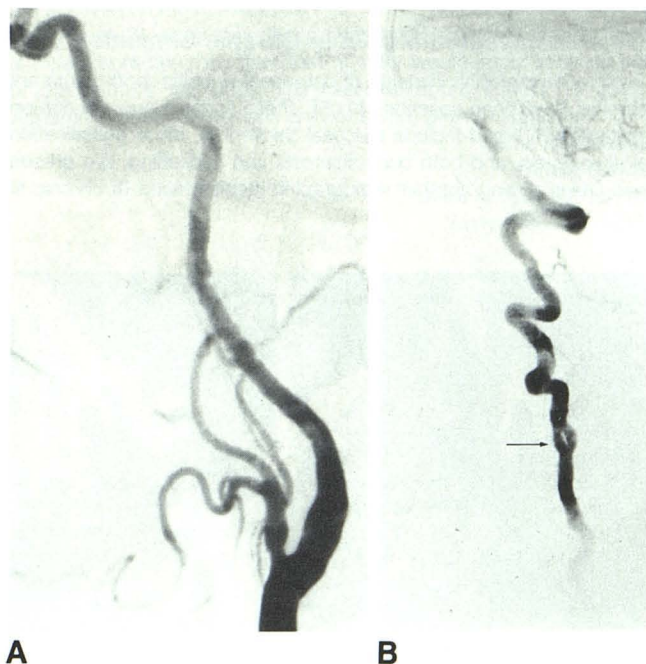


Fig. 1.—A, Common carotid angiograms, left lateral projections, reveal characteristic "string of beads" appearance of fibromuscular dysplasia involving cervical portions of internal carotid arteries.

B, Left vertebral angiogram, lateral projection, shows localized fenestration of vertebral artery at level of third and fourth cervical vertebrae (arrow).



However, our search of the literature failed to disclose any report of FMD associated with fenestration of the cervicocephalic arteries; therefore, it is presumed that the association observed in the present patient was incidental. The clinical significance of fenestration of the vertebral artery has not been determined. An aneurysm susceptible to rupture may arise in the proximal portion of the fenestration as in the basilar, internal carotid, or intracranial arteries [5-7]. Fenestration without an aneurysm is probably innocuous, although fenestration may become a nidus for clot formation [2].

Yuji Numaguchi  
Mark S. Fleming  
Eugenio F. Vargas  
Tulane University Medical Center  
New Orleans, LA 70112

## REFERENCES

1. Mettinger KL, Ericson K. Fibromuscular dysplasia and the brain. Observation on angiographic, clinical and genetic characteristics. *Stroke* 1982;13:46-57
2. Takahashi M, Kawanami H, Watanabe N, Matsuoka S. Fenestration of the extracranial vertebral artery. *Radiology* 1970;96:359-360
3. Kowada M, Yamaguchi K, Takahashi H. Fenestration of the vertebral artery with a review of 23 cases in Japan. *Radiology* 1972;103:343-346
4. Miyazaki S, Kamata K, Yamaura A. Multiple aneurysms of the vertebro-basilar system associated with fenestration of the vertebral artery. *Surg Neurol* 1981;15:192-195
5. Hoffman WF, Wilson CB. Fenestrated basilar artery with an associated saccular aneurysm. Case Report. *J Neurosurg* 1979;50:262-264
6. Yock DH. Fenestration of the supraclinoid internal carotid artery with rupture of associated aneurysm. *AJNR* 1984;5:634-636
7. Matsumura M, Nojiri K. Ruptured anterior communicating artery aneurysms associated with fenestration of the anterior cerebral artery. *Surg Neurol* 1984;22:371-376

## CT of Inspissated Mucus in Chronic Sinusitis

Many radiographic findings of paranasal sinusitis, both acute and chronic, have been described [1-3]. These findings are well demonstrated by CT and include mucosal thickening, sinus opacification, air-fluid levels, and both bony sclerosis and thickening. We present two cases having another radiographic manifestation of chronic si-

nusitis that is best shown by CT. In each case the sinuses had areas of high attenuation on CT with densities of about 105 to 125 H that were found to be secondary to inspissated mucus at surgery.

## Case Reports

### Case 1

A 25-year-old woman was evaluated because of a long history of recurrent allergic and infectious rhinosinusitis associated with polyposis. Plain radiographs revealed opacification of the frontal, ethmoid, and maxillary sinuses. CT without contrast enhancement revealed peripherally located soft-tissue density caused by mucosal thickening and polyposis in the sinuses (Fig. 1). Sharply demarcated regions of high density were identified centrally in the ethmoid and maxillary sinuses. A soft-tissue mass was seen in the left nasal airway. The patient underwent a left polypectomy, bilateral Caldwell-Luc procedures, and bilateral transantral and transnasal ethmoidectomies.

### Case 2

A 22-year-old woman was evaluated because of a long history of chronic sinusitis. The physical examination revealed severe edema of the nasal turbinates and mucopurulent material in the right nasal cavity. Plain radiographs revealed prominent opacification of the paranasal sinuses. CT without contrast enhancement showed areas of mucosal thickening and polyposis in the frontal, ethmoid, and maxillary sinuses (Fig. 2). Centrally located areas of high density were identified. The patient underwent bilateral transorbital ethmoidectomy, frontal sinusotomy, and bilateral Caldwell-Luc procedures.

In each case, at surgery the ethmoid and maxillary sinuses were found to be packed with inspissated mucus that had the consistency of putty. Pathologic examination revealed inspissated mucus and polypoid inflammatory tissue with no calcification. Cultures and smears did not reveal bacterial or fungal infection.

## Discussion

These cases show an additional radiographic finding of chronic sinusitis caused by inspissated mucus. The increased density of this material relative to that of mucosal thickening or fluid is best shown by CT and would not be appreciated by plain radiographic methods.

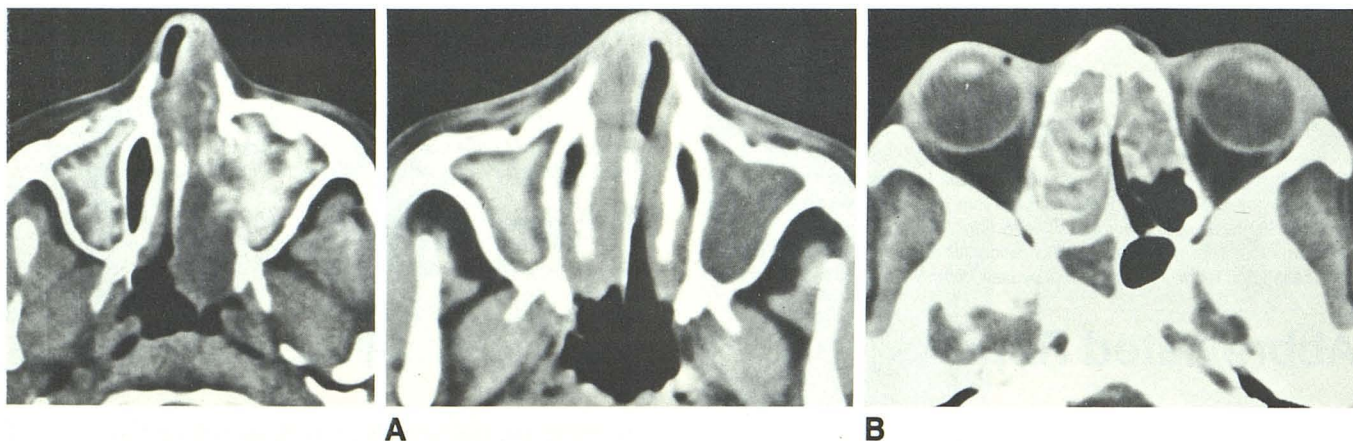


Fig. 1.—Axial CT scan shows areas of high attenuation in both maxillary sinuses and protrusion of soft-tissue mass from left maxillary sinus into nasal airway.

Fig. 2.—A, Axial CT scan shows central high density in right maxillary sinus with surrounding mucosal thickening. Left maxillary sinus contains soft-tissue density material. There is soft-tissue thickening in nasal airway.  
B, Axial CT shows high-density areas in ethmoid sinus with soft-tissue opacity of right side of sphenoid sinus.