



Get Clarity On Generics

Cost-Effective CT & MRI Contrast Agents



FRESENIUS
KABI

WATCH VIDEO

AJNR

CT diagnosis of an atypical nasopharyngeal teratoma in a newborn.

M O Senac, Jr and H D Segall

AJNR Am J Neuroradiol 1987, 8 (4) 710-712

<http://www.ajnr.org/content/8/4/710.citation>

This information is current as
of August 23, 2025.

CT Diagnosis of an Atypical Nasopharyngeal Teratoma in a Newborn

Melvin O. Senac, Jr.,¹ and Hervey D. Segall

Nasopharyngeal teratoma, commonly known as an epignathus, is a rare congenital malformation found in newborns. Diagnosis is usually straightforward, with calcifications seen within the mass. However, we encountered a neonate with a noncalcified cystic mass protruding from the oral cavity. The question was raised clinically as to whether this could be a basal encephalocele. CT led to the correct diagnosis of this unusual entity.

Case Report

A 4-hour-old boy was transferred to our hospital for increasing respiratory distress. Apgars were 8 at 1 min and 9 at 5 min, and he required no resuscitation. At delivery, the infant was noted to be in mild respiratory distress and had a large cystic mass filling and protruding from the oral cavity. Examination revealed an 8–9 cm cystic mass that appeared to be arising from the hard palate. There was no soft palate, and the mandibular and maxillary ridges were widened. Increasing respiratory distress over the next few hours prompted a tracheostomy. Standard radiographs revealed a homogeneous mass with no visible calcifications or osseous elements. Clinically, fluid was dripping from the lesion, thus raising the question of a CSF leak. With lack of calcifications radiographically, a diagnosis of either an encephalocele or an unusual teratoma with CSF communication was considered.

Furthermore, analysis of the fluid dripping from the lesion revealed a glucose level of 47 mg/dl consistent with what one would see in CSF. CT scans revealed a large mass projecting from the oral cavity, primarily cystic in nature (Figs. 1 and 2). There were several factors against the diagnosis of an encephalocele: First, there were no bony defects, particularly involving the sphenoid; second, the fluid within this mass showed CT numbers of approximately 20 H higher than CSF; third, there was a solid aspect to this mass, which enhanced after contrast administration; and finally, the lesion was clearly separate from cerebral tissue. Collectively, these CT findings allowed us to make the preoperative diagnosis of a teratoma.

The patient underwent transoral, transpalatal excision of the mass. The tumor was attached via a broad stalk to the roof of the mouth and was difficult to dissect. The soft palate was grossly distorted. There was no evidence of cerebral communication. Gross pathologic examination of the mass revealed a reddish 5.5 × 4.2 × 2 cm cystic lesion with no areas of calcification. Fluid analyzed from the cystic mass at surgery revealed a total protein of 161 mg/dl. This level is

higher than one normally sees in CSF and probably accounts for the higher CT numbers. Microscopically, the wall was composed of a mixture of skin, respiratory epithelium, tooth germ, choroid plexus, salivary gland, and abundant neural tissue. No malignant germ cell components were noted.

Discussion

Teratomas, defined as true tumor composed of multiple tissues foreign to the part in which it arose, have been classified into four types: dermoids, teratoids, teratomas, and true epignathi. Nasopharyngeal teratomas have previously been called epignathi by many; however, most in fact are of the dermoid type according to Ewing's classification [1]. Teratomas of the nasopharynx are a rare congenital malformation occurring more commonly in females, with a ratio estimated at 6:1 [2]. Malignant change has not been reported as opposed to sacrococcygeal teratomas, in which malignancy is estimated at 10% in cases diagnosed at birth and at 91% in those diagnosed after age 2 months [3, 4]. Teratomas arising from the nasopharynx usually cause grotesque distortion and, in many cases, airway obstruction. There is often deformity of the maxilla with a midline cleft, since the mass restricts formation of the hard palate.

In utero, the mother may demonstrate polyhydramnios secondary to obstruction of the fetal pharynx. At birth, there are usually symptoms of respiratory distress and, if the airway is compromised, a tracheostomy must be performed before radiographic studies and eventual surgery.

Radiographic diagnosis of a teratoma arising from the nasopharynx usually can be made on a conventional lateral radiograph. Characteristically, a mass with calcification and/or ossification is seen arising from the oral cavity with gross deformity of the maxilla (Fig. 3). The origin of these tumors is thought to be similar to that of sacrococcygeal teratomas since they lie in an area that remains active in embryologic differentiation until well along into fetal life [5]. Calcifications are present in at least 60% of sacrococcygeal teratomas, but to our knowledge no data concerning the frequency of calcifications and/or ossifications on radiographs have ever been presented in nasopharyngeal teratomas. The radiologic liter-

Received April 18, 1985; accepted after revision August 7, 1985.

¹ Both authors: Department of Radiology, Childrens Hospital of Los Angeles, P. O. Box 54700, Los Angeles, CA 90054-0700. Address reprint requests to M. O. Senac, Jr.

ature contains little information on these teratomas; a few scattered case reports in the surgical literature describe calcifications or osseous structures seen readily on standard radiographs. Three other nasopharyngeal teratomas have

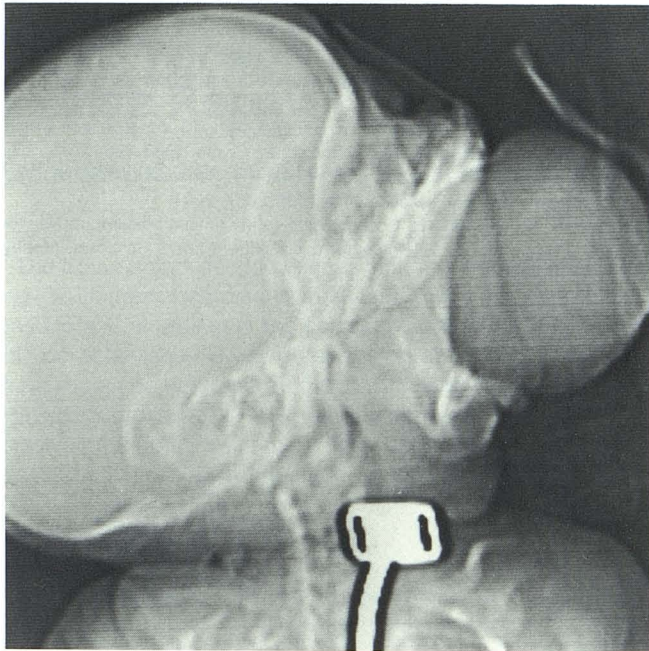


Fig. 1.—Scout view. Large soft-tissue mass is seen protruding from oral cavity.

been seen at our hospital over the past 10 years and all showed obvious calcification.

This case was unusual in that no calcification or ossification was seen grossly or radiographically. Further complicating the diagnosis was the leakage of fluid by the cystic mass suggesting an anterior encephalocele clinically. Since others

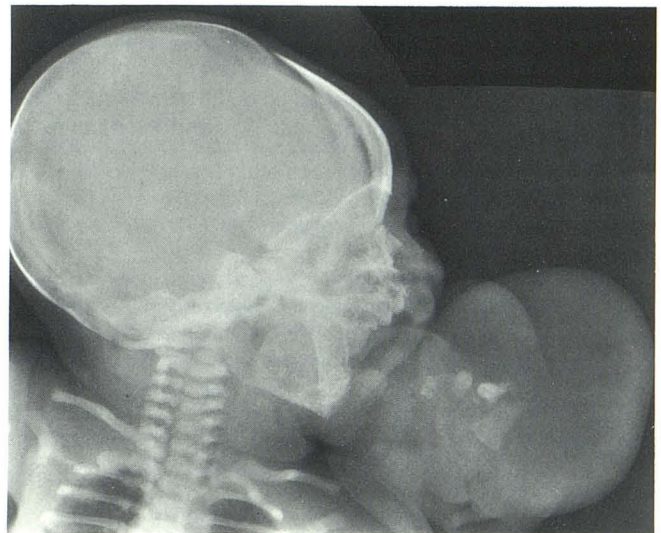


Fig. 3.—Nasopharyngeal teratoma in another patient. Lateral radiograph shows more typical appearance with teeth.

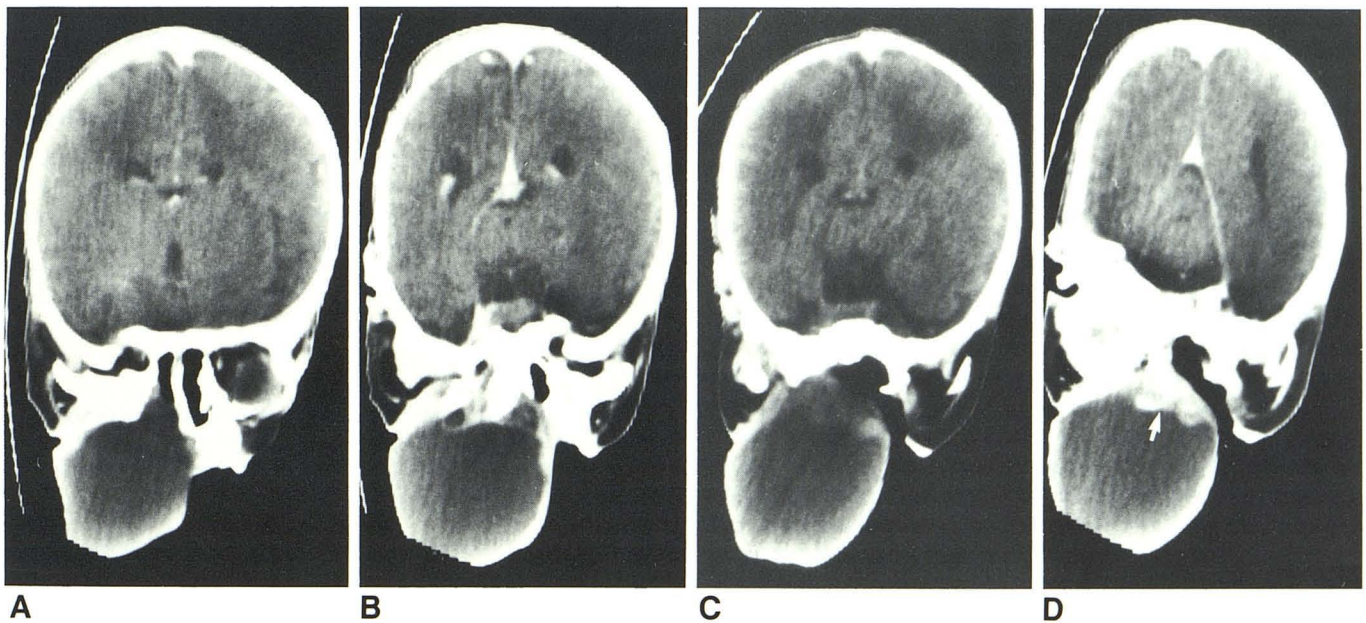


Fig. 2.—Near coronal CT. Images are displayed from anterior to posterior.
 A, Postcontrast CT section through anterior portion of mass. Note extension into nasal cavity with a defect in palate and maxilla.
 B, Section through sphenoid bone and floor of middle cranial fossa demonstrates no osseous defect. Temporal lobe tissue and adjacent subarachnoid spaces are normal.
 C, Precontrast scan through posterior portion of mass shows compromise of nasopharyngeal airway.
 D, Matching postcontrast scan at similar level shows a solid, enhancing component (arrow) at posterior superior margin of lesion that is of higher density than cerebral tissue. Cystic component of lesion is of higher density than CSF.

have alluded to transphenoid encephaloceles protruding from the oral cavity [6, 7], differentiation from a nasopharyngeal teratoma with a patent craniopharyngeal canal that would allow the subarachnoid space to communicate with the mass [1] was obviously important presurgically.

In those rare instances in which differentiation between an anterior encephalocele and a nonossified nasopharyngeal teratoma is required, we feel that CT is helpful. In our case we were able to demonstrate that the fluid was of higher density than CSF; furthermore, no defect in the skull base or sphenoid bone was seen to indicate a basal encephalocele. Thus, CT appears able to identify the type of pathologic process and to demonstrate the gross anatomic disturbances associated with teratomas before surgical excision and eventual reconstructive surgery.

REFERENCES

1. Wilson JW, Gehweiler JA. Teratoma of the face associated with a patent canal extending into the cranial cavity (Rathke's pouch) in a three-week-old child. *J Pediatr Surg* **1970**;5:349-358
2. Foxwell PB, Kelham BH. Teratoid tumors of the nasopharynx. *J Laryngol Otol* **1958**;72:647-657
3. Heroman WH, Golden SM, Yudit WM. Nasopharyngeal teratoma in the newborn. *Ear Nose Throat J* **1980**;59:203-207
4. Werner JL, Taybi H. Presacral masses in childhood. *AJR* **1970**;109:403-409
5. Raffensperger JG. Teratomas. In: Raffensperger JG, ed. *Swenson's pediatric surgery*. New York: Appleton-Century-Crofts, **1980**:366-375
6. Hendrick EB. Encephaloceles. In: Wilkins RH, Rengachary SS, eds. *Neurosurgery*. New York: McGraw-Hill **1985**:2087-2091
7. Pollock JA, Newton TH. Encephalocele and cranium bifidum. In: Newton TH, Potts DG, eds. *Radiology of the skull and brain*. St. Louis: Mosby, **1971**:634-647