



## Get Clarity On Generics

Cost-Effective CT & MRI Contrast Agents

**FRESENIUS  
KABI**

[WATCH VIDEO](#)

# AJNR

## **Atrial Ventricular Diverticulum: Sonographic Diagnosis**

Michael G. Karnaze, Gary D. Shackelford and Charles L. Abramson

*AJNR Am J Neuroradiol* 1987, 8 (4) 721-723

<http://www.ajnr.org/content/8/4/721.citation>

This information is current as  
of August 11, 2025.

# Atrial Ventricular Diverticulum: Sonographic Diagnosis

Michael G. Karnaze,<sup>1</sup> Gary D. Shackelford, and Charles L. Abramson

Diverticulum of the lateral ventricle is an uncommon occurrence in patients with hydrocephalus [1–5]. Confusing this entity with similar-appearing abnormalities such as arachnoid cysts, cystic neoplasms, or the trapped fourth ventricle must be avoided to ensure proper management [6–8]. Although the pathologic and CT features have been described [1], the sonographic appearance is not widely known. Given the role that cranial sonography has assumed in evaluating the neonatal brain, it is essential that sonographers recognize this unusual entity. We report two cases of lateral ventricular diverticulum diagnosed with sonography, one with CT correlation.

## Case Reports

### Case 1

A 2½-month-old girl was evaluated for an enlarged head. The infant had weighed 3340 g at birth following a full-term pregnancy complicated by persistent vaginal bleeding, and the mother had noted the child's head to be large during early infancy. Physical findings at presentation included an enlarged head, bulging of the anterior fontanelle, split sutures, mild right esotropia, and downward gaze. CT showed marked dilatation of the lateral and third ventricles, a nondilated fourth ventricle, and a large cystic structure in the region of the quadrigeminal cistern (Fig. 1A). A lateral ventricular diverticulum was suspected, although an arachnoid cyst was also considered as a possible diagnosis. Cranial sonography revealed a communication between the "cyst" and the trigone of the left lateral ventricle, confirming the abnormality to be a ventricular diverticulum (Figs. 1B and 1C). A shunt catheter was placed in the right frontal horn. Postoperative sonograms showed no immediate resolution of the hydrocephalus or diverticulum. CT 6 weeks after shunting showed a mild decrease in the hydrocephalus and no change in the size of the diverticulum.

### Case 2

A newborn premature infant girl with an estimated gestational age of 27 weeks and a birth weight of 830 g was noted on the second day of life to have multiple petechiae, bleeding from puncture sites, and prolonged prothrombin and partial thromboplastin times. Physical examination was otherwise normal except for mild right esotropia. Sonography showed a large hemorrhage in the region of the head of the right caudate nucleus, which progressed to involve the right lateral ventricle and periventricular white matter. Dilatation of the

lateral ventricle and periventricular white matter. Dilatation of the lateral ventricles developed and a follow-up sonogram on the 14th day of life demonstrated a diverticulum of the left lateral ventricle and dilatation of the lateral ventricles (Fig. 2). The patient later developed a large porencephalic cyst communicating with the right lateral ventricle, and a ventriculoperitoneal shunt was inserted at age 3 months. Postoperative sonography showed a decrease in the ventricular dilatation and disappearance of the ventricular diverticulum.

## Discussion

Ventricular diverticulum is a recognized complication of hydrocephalus and has been reported to occur at a variety of locations. A diverticulum can arise from the third ventricle at its posterior recess, floor, or anteriorly at the lamina terminalis, and also from the lateral ventricle at its trigone [1–4]. Lateral ventricular diverticulum can also occur at the site of needle puncture of a dilated lateral ventricle [5]. Spontaneous rupture of the diverticulum or of a dilated ventricle into the subarachnoid space, termed ventriculocisternostomy, is known to occur, sometimes with resolution of hydrocephalus [2–4]. Ventricular diverticula may reach a size of 7 cm and may be unilateral or bilateral [1]. Their true prevalence is unknown.

The anatomic basis of lateral ventricular diverticulum has been well described by Naidich et al. [1]. The superomedial wall of the atrium of the lateral ventricle is formed by the splenium of the corpus callosum, which is thinned, elevated, and displaced posteriorly as the atrium expands in hydrocephalus. The crus of the fornix—which, along with the alveoli of the hippocampus, forms the inferomedial atrial wall—is thinned and displaced inferiorly. The alveoli are stretched between the elevated splenium and depressed crus. This region of the alveoli and the crus of the fornix becomes progressively thinned and lies medial to the free edge of the tentorium and superior to the incisura. Focal dehiscence of this thin alveolar-crural sheet creates an ostium in the inferomedial atrial wall through which pia and CSF can protrude. Separated from the subarachnoid space by this thin pial covering, the resulting diverticulum may extend downward through the incisura. This may result in displacement of the fourth ventricle inferiorly, the quadrigeminal plate and pineal anteroinferiorly, and the straight sinus and tentorium posterosuperiorly.

This article appears in the July/August 1987 issue of *AJNR* and the September 1987 issue of *AJR*.

Received September 15, 1986; accepted after revision January 8, 1987.

<sup>1</sup>All authors: Mallinckrodt Institute of Radiology, 510 South Kingshighway Blvd., St. Louis, MO 63110. Address reprint requests to G. D. Shackelford.

*AJNR* 8:721–723, July/August 1987 0195–6108/87/0804–0721 © American Society of Neuroradiology



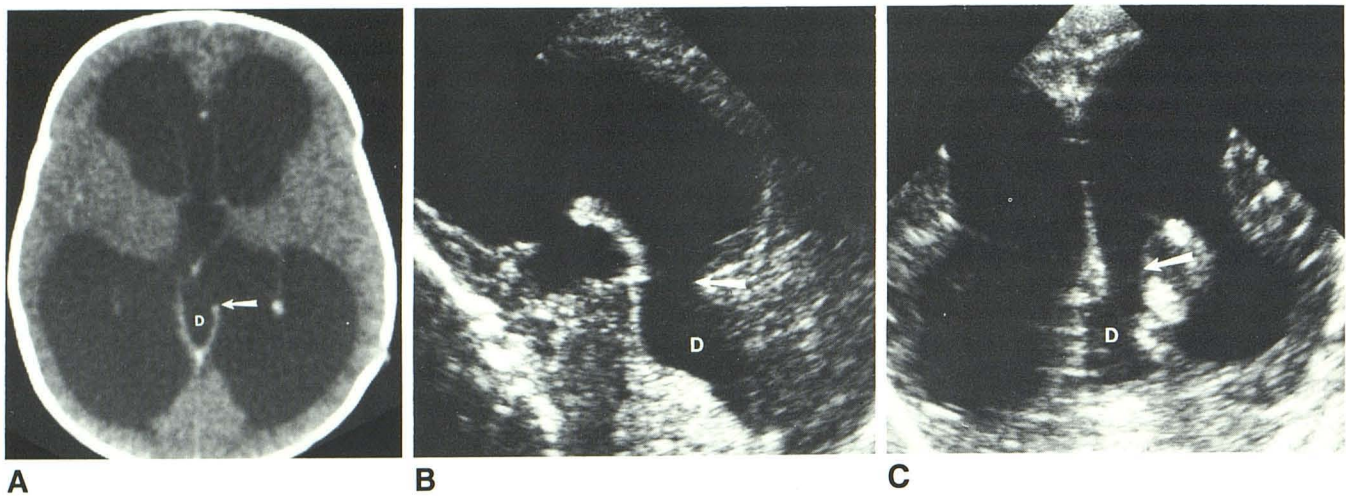


Fig. 1.—Case 1.

A, Axial contrast-enhanced CT with 4-mm collimation shows dilatation of lateral and third ventricles. Anterior edge of left tentorial band is shortened, typical of lateral ventricular diverticulum (arrow). D = diverticulum.

B, Sagittal sonogram through dilated left lateral ventricle shows this diverticulum (D) and its point of communication with lateral ventricle (arrow). Diverticulum extends posteroinferiorly from trigone and is seen superior to cerebellum.

C, Coronal image clearly shows communication of diverticulum (D) with left lateral ventricle (arrow).

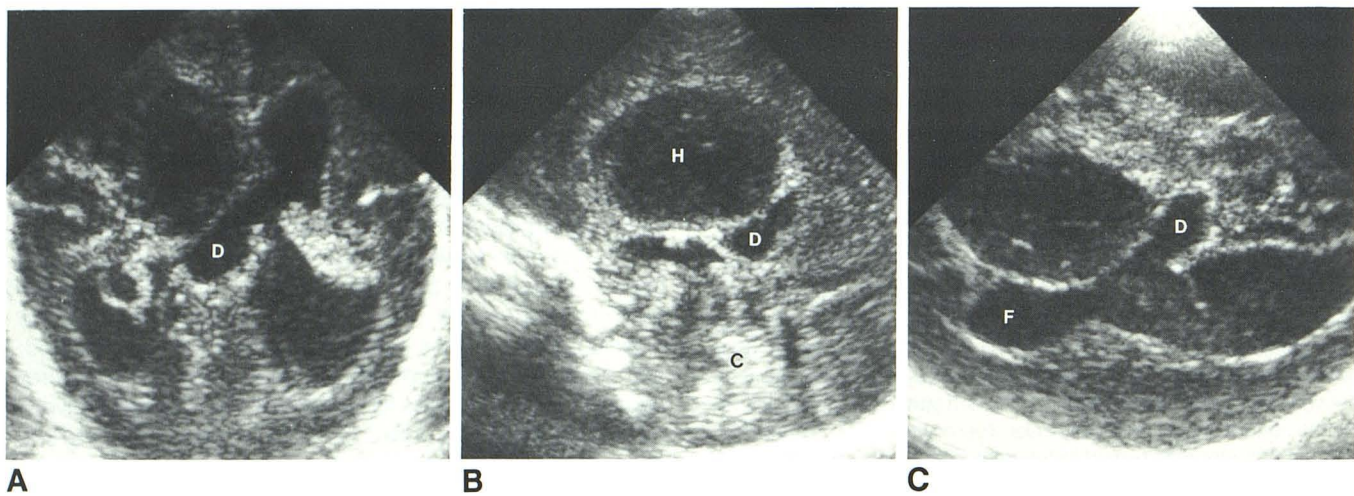


Fig. 2.—Case 2.

A, Coronal sonogram through trigone shows diverticulum (D) extending from left lateral ventricle.

B, Midsagittal scan shows that diverticulum (D) lies superior to cerebellum (C) and tentorium. H = hemorrhage.

C, Axial scan clearly defines communication between diverticulum (D) and left lateral ventricle. F = frontal horn of lateral ventricle.

In our two cases, sonography revealed hydrocephalus and an asymmetrical cystic structure extending from the inferomedial aspect of the trigone. The point of communication of the diverticulum with the trigone was clearly evident in both our cases, but has not always been identified with CT [1]. This communication could be seen on sonography with careful sagittal and coronal scanning but was more clearly demonstrated in the axial plane in the one case in which axial scanning was performed (Fig. 2C). Coronal scans displayed the relationship of the diverticulum to the tentorium in both cases, although the location of the diverticulum superior to

the tentorium in the second case was better shown on sagittal images (Figs. 2A and 2B).

Lateral ventricular diverticula, which are secondary to hydrocephalus and can be treated by shunting, must be differentiated from entities that can cause hydrocephalus, such as arachnoid cysts and cystic neoplasms [6]. The dilated posterior recess of the third ventricle, trapped fourth ventricle, or trapped posterior recess of the third ventricle may also be mistaken for a lateral ventricular diverticulum [7, 8]. A dilated posterior third ventricular recess communicates with the third ventricle. The trapped fourth ventricle and the less common

trapped posterior third ventricle typically occur following shunting of hydrocephalus [7, 8]. Cystic tumors may show an associated soft-tissue mass. Arachnoid cysts may be more symmetric than diverticula and do not have a communication with the lateral ventricle [6]. It is the absence of this communication with the lateral ventricle and the presence of intact ventricular walls that differentiate all of these abnormalities from a lateral ventricular diverticulum.

In summary, diverticulum of the lateral ventricle is an uncommon complication of hydrocephalus, but one that must be recognized by the sonographer. A diverticulum should not be confused with other abnormalities, some of which can cause hydrocephalus and thus have different therapeutic implications. We have described two cases in which sonography was diagnostic by depicting the actual communication between the diverticulum and the lateral ventricle.

#### REFERENCES

1. Naidich TA, McLone DG, Hahn YS, Hanaway J. Atrial diverticula in severe hydrocephalus. *AJNR* **1982**;3:257-266
2. Tandon PK, Harkmark W. Spontaneous ventriculocisternostomy with relief of obstructive hydrocephalus. *Neurology* **1959**;9:699-703
3. Miller CF, White RJ, Roski RA. Spontaneous ventriculo-cisternostomy. *Surg Neurol* **1981**;54:98-100
4. Liss L, Mervis L. Spontaneous ventriculostomy through lamina terminalis with arrest of hydrocephalus. *J Neurosurg* **1965**;23:211-213
5. Grainger RG, Lorber J. Development of ventricular diverticula following ventricular puncture in hydrocephalic infants. *Acta Radiol* **1963**;1:569-576
6. Lee BCP. Intracranial cysts. *Radiology* **1979**;130:667-674
7. Scotti G, Musgrave MA, Fitz CR, Harwood-Nash DC. The isolated fourth ventricle in children. *AJR* **1980**;135:1233-1238
8. Babcock DS, Han BK. *Cranial ultrasonography of infants*. Baltimore: Williams & Wilkins, **1981**:154