



## Discover Generics

Cost-Effective CT & MRI Contrast Agents



FRESENIUS  
KABI

WATCH VIDEO

# AJNR

## **Balloon embolization of a traumatic carotid-ophthalmic pseudoaneurysm with control of the epistaxis and preservation of the internal carotid artery.**

S Tantana, T J Pilla, E E Awwad and K R Smith

This information is current as of June 18, 2025.

*AJNR Am J Neuroradiol* 1987, 8 (5) 923-924  
<http://www.ajnr.org/content/8/5/923.citation>

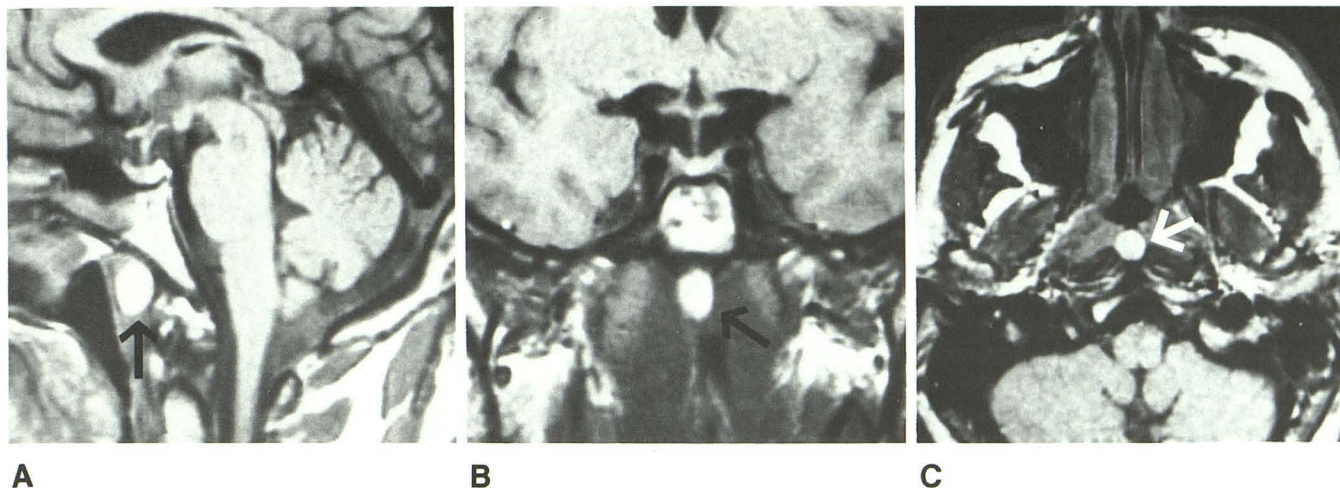
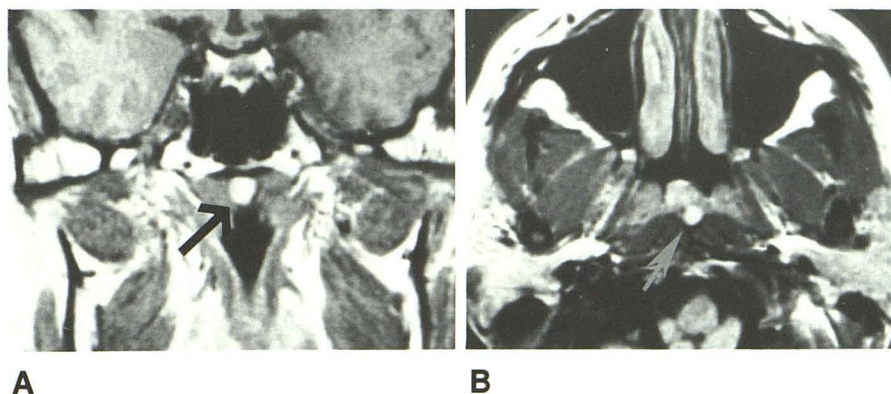


Fig. 1.—A-C, Sagittal (A), coronal (B), and transaxial (C) MR images show Thornwaldt cyst (arrows) as a round, high-signal midline lesion in nasopharyngeal vault on T1-weighted sequences. TR = 800 msec, TE = 20 msec at 1.5 T.

Fig. 2.—A and B, Coronal (A) and transaxial (B) views of Thornwaldt cysts (arrows) in two patients. Small cyst in B posterior to nasopharyngeal mucosa lies in midline between the right and left longus capitis. TR = 800 msec, TE = 20 msec at 1.5 T.



attenuation, nonenhancing mass within the posterior nasopharynx in the midline [1]. T1-weighted MR images (Figs. 1 and 2) reveal a round, high-signal lesion in the same location. The high signal is caused by the loculated concentrated mucus and inflammatory debris; MR has a greater sensitivity and specificity for these changes than has been previously available from other diagnostic imaging examinations.

William J. Ford  
Betty S. Brooks  
Taher El Gammal  
Medical College of Georgia  
Augusta, GA 30912

#### REFERENCES

1. Weber AC. Pathology of nasopharynx. In: Taveras J, Ferrucci JT, Jr, eds. *Radiology: diagnosis/imaging/intervention*, 3rd ed. Philadelphia: Lippincott, 1986:97.
2. Potter GD III, Bryan RN, Hanafee WN, Som PM, Weber AL, Weinberg PE. Case 18: questions 69 through 72. In: Theros EG, Harris JH Jr, eds. *Disorders of the head and neck (third series) syllabus*. Chicago: F. H. Young, 1985:334-353.
3. James AE Jr, MacMillan AS Sr, MacMillan AS Jr, Momose KJ. Thornwaldt's cyst. *Br J Radiol* 1968;41:902-904.

#### Balloon Embolization of a Traumatic Carotid-Ophthalmic Pseudoaneurysm with Control of the Epistaxis and Preservation of the Internal Carotid Artery

Epistaxis resulting from rupture of a traumatic cavernous carotid aneurysm has been treated with surgery or balloon trapping of the pseudoaneurysm and subsequent sacrifice of the internal carotid artery [1-3]. We report a case in which a traumatic carotid-ophthalmic aneurysm was occluded while the internal carotid artery was preserved.

#### Case Report

A 10-year-old boy was evaluated for repeated epistaxis. He had a previous history of severe closed head injury, with basilar skull fracture resulting in blindness in his left eye. Cerebral arteriogram showed a 10 × 12 × 18 mm lobulated aneurysm of the left carotid-ophthalmic artery (Fig. 1A). Intravascular balloon embolization was performed 24 days after the last episode of epistaxis. A 2-mm silicone balloon was detached within the pseudoaneurysm, and carotid blood flow was preserved (Fig. 1B). The procedure was performed by using



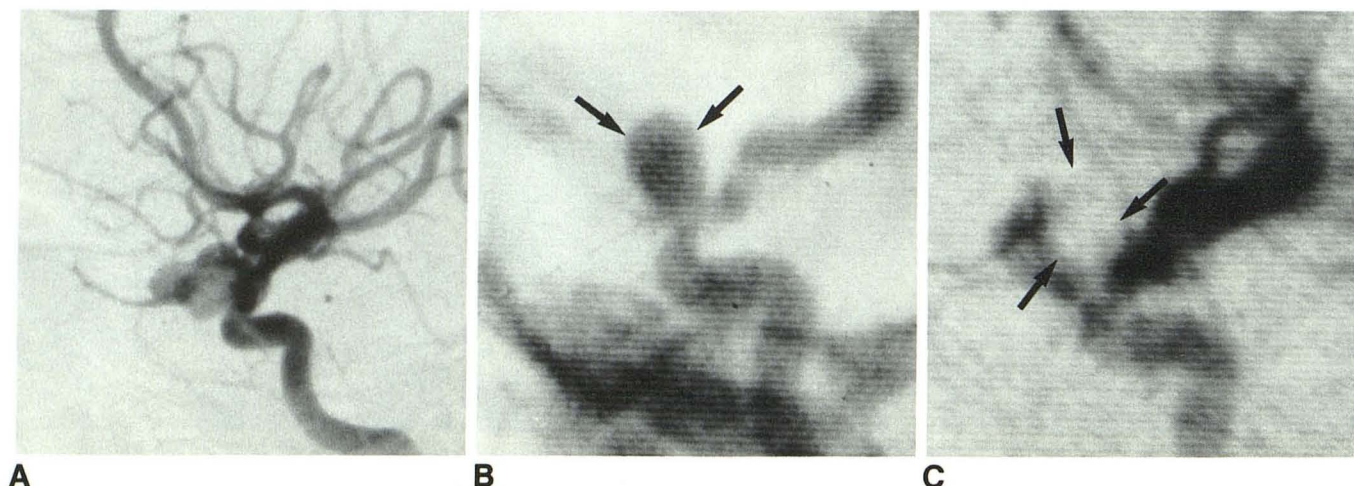


Fig. 1.—A, Lateral arteriogram shows lobulated pseudoaneurysm of cavernous portion of left internal carotid artery projecting anteriorly and inferiorly into sphenoid sinus.

B, Single selected frame from preembolization digital subtraction angiography was superimposed on real-time fluoroscopic image during embolization procedure. Balloon (arrows) was guided into pseudoaneurysm, inflated, and detached.

C, On postembolization digital subtraction angiogram, some filling of pseudoaneurysm remains anterior to balloon (arrows). Balloon was detached, occluding opening while preserving carotid flow.

digital subtraction angiography. Postembolization angiography showed greater than 50% of the aneurysm occupied by the balloon (Fig. 1C). A repeat arteriogram at 3 months showed no change in the size of the residual aneurysm. More importantly, thrombus was seen extending into the sphenoid sinus. The patient remained asymptomatic at the 6-month follow-up.

## Discussion

Intravascular balloon occlusion of the internal carotid artery has proved to be an effective technique in the treatment of internal carotid artery aneurysms [3–6]. The balloons can be introduced through a femoral-cerebral angiographic catheter system, one above the aneurysm and one below, effecting trapping and occlusion of carotid blood flow. The technique eliminates the need for an open operation, but a bypass from the superficial temporal artery to the middle cerebral artery still is needed in cases in which marginal cross-circulation is present. Direct obliteration of the aneurysm and preservation of carotid blood flow would be the ideal technique, but this combination rarely has been achieved. Because of the marginal cross-circulation in our case, we decided to obliterate the pseudoaneurysm rather than occlude the internal carotid artery by trapping the pseudoaneurysm. The preembolization digital subtraction angiographic image was used as a “road map” and was superimposed on the real-time fluoroscopic image, allowing visualization of the pseudoaneurysm. The balloon was inflated only to a point at which occlusion of the aneurysm was present, thereby eliminating any possibility of rupture.

The exact time at which embolization of a pseudoaneurysm can be performed safely is unknown; however, we would not recommend balloon occlusion of a newly formed pseudoaneurysm. Sufficient time should be allowed for the pseudoaneurysm to develop a thick wall. In addition, if the presenting clinical symptomatology is epistaxis, occlusion of the sphenoidal part of the aneurysm must be confirmed and any residual aneurysm observed by means of repeat arteriography. If this cannot be done, entrapment of the aneurysm is recommended, even if a bypass from the superficial temporal artery to the middle cerebral artery must be performed to prevent further epistaxis from the pseudoaneurysm.

Supranee Tantana

Thomas J. Pilla

Eric E. Awwad

Kenneth R. Smith

St. Louis University Medical Center

Cardinal Glennon Children's Hospital

St. Louis, MO 63104

## REFERENCES

1. Chambers EF, Rosenbaum AE, Norman D, Newton TH. Traumatic aneurysms of cavernous internal carotid artery with secondary epistaxis. *AJNR* 1981;2:405–409
2. Ming-Ying L, Chun-Jen S, Yeou-Chih W, Shin-Han T. Traumatic intracavernous carotid aneurysm with massive epistaxis. *Neurosurgery* 1985;17:569–570
3. McGrail KM, Heros RC, Debrun G, Beyerl BD. Aneurysm of the ICA petrous segment treated by balloon entrapment after EC-IC bypass. *J Neurosurg* 1986;65:249–252
4. Debrun G, Fox A, Drake C, Peerless S, Girvin J, Ferguson G. Giant unclippable aneurysms: treatment with detachable balloons. *AJNR* 1981;2:167–173
5. Tsai FY, Matovich V, Hieshima G, et al. Percutaneous transluminal angioplasty of the carotid artery. *AJNR* 1986;7:349–358
6. Hieshima GB, Higashida RT, Halbach VV, Cahan L, Goto K. Intravascular balloon embolization of a carotid-ophthalmic artery aneurysm with preservation of the parent vessel. *AJNR* 1986;7:916–918

## Ossification of the Posterior Longitudinal Ligament Diagnosed by MR

Ossification of the posterior longitudinal ligament (OPLL) is an uncommon, though not rare, disease of unknown etiology that occurs in approximately 0.2% of Caucasians [1]. The condition is much more common among Japanese, in whom the prevalence is about 2.0% [2]. Resnick et al. [3] found an association between diffuse idiopathic skeletal hyperostosis (DISH) and OPLL; OPLL occurred in 50% of patients with DISH. The significance of OPLL lies in the possibility of spinal cord compression by the ossified/calcified and hypertrophied