



Get Clarity On Generics

Cost-Effective CT & MRI Contrast Agents



FRESENIUS
KABI

WATCH VIDEO

AJNR

Nontraumatic lobar intracerebral hemorrhage: CT/angiographic correlation.

D J Loes, W R Smoker, J Biller and S H Cornell

AJNR Am J Neuroradiol 1987, 8 (6) 1027-1030

<http://www.ajnr.org/content/8/6/1027>

This information is current as
of August 13, 2025.

Nontraumatic Lobar Intracerebral Hemorrhage: CT/Angiographic Correlation

Daniel J. Loes¹
 Wendy R. K. Smoker²
 José Biller³
 Steven H. Cornell¹

Cerebral angiography in patients with nontraumatic lobar intracerebral hemorrhage may or may not uncover the underlying cause of the disorder. The CT and cerebral angiographic studies of 67 consecutive patients with nontraumatic lobar intracerebral hemorrhage were reviewed to assess the relationship between CT pattern and location of hemorrhage and the frequency of diagnostic angiographic findings. Origins of these hematomas were also determined and correlated with radiographic findings. CT revealed 26 temporal, 18 frontal, 17 parietal, three occipital, and three multiple lobar hematomas. Thirty-three patients had "pure" lobar hematomas, 12 had coexistent intraventricular hemorrhage, 12 had associated subarachnoid hemorrhage, and 10 had both intraventricular and subarachnoid hemorrhage accompanying their lobar hematomas. Angiographic findings were diagnostic in 29 cases (43%). In the presence of accompanying subarachnoid hemorrhage, angiographic findings were diagnostic in 17 (77%) of 22 patients; in its absence, angiography was diagnostic in 12 (27%) of the remaining 45 patients. Diagnostic angiograms were also more frequent in the presence of a frontal or temporal lobar hematoma than with a parietal or occipital lobar hematoma.

While CT patterns do influence the frequency of diagnostic angiographic findings, cerebral angiography is recommended in all patients with otherwise unexplained non-traumatic lobar intracerebral hemorrhage.

Lobar intracerebral hemorrhage (ICH), defined as supratentorial hemispheric parenchymal bleeding located outside the deep nuclear structures, accounts for 10–32% of nontraumatic intracranial bleeding [1]. Lobar hematomas stem from a wide variety of origins, including aneurysms, arteriovenous malformations (AVMs), bleeding diatheses, primary or metastatic tumors, cortical or dural venous thromboses, cerebral amyloid angiopathy, sympathomimetic drugs, and systemic hypertension [2–10]. The advent of CT has permitted prompt recognition of ICH. In the absence of known intracranial disease or a bleeding diathesis, cerebral angiography has been recommended in patients with nontraumatic lobar hematomas to search for an underlying origin [11]. The purpose of our study was to assess the diagnostic value of cerebral angiography with respect to CT pattern and location of hemorrhage in patients with nontraumatic lobar ICH, and to correlate the radiographic findings with the underlying origins of the lobar hematomas.

Subjects and Methods

We retrospectively reviewed the clinical records and radiologic studies of all patients with nontraumatic lobar ICH who were referred for cerebral angiography at the University of Iowa Hospitals from July 1, 1981, to June 30, 1986. All patients with known intracranial disease or a possible traumatic history were excluded. Other exclusions included CT evidence of basal ganglionic, thalamic, brainstem, or cerebellar hemorrhage; pure subarachnoid hemorrhage (SAH); pure intraventricular hemorrhage (IVH); or hemorrhagic infarction. Two patients who underwent surgical hematoma evacuation prior to angiography were also dismissed from the study. Our study did not include lobar hematomas in patients with bleeding diatheses,

Received February 18, 1987; accepted after revision April 22, 1987.

¹ Department of Radiology, University of Iowa Hospitals and Clinics, Iowa City, IA 52242. Address reprint requests to D. J. Loes.

² Department of Radiology, University of Utah School of Medicine, Salt Lake City, UT 84132.

³ Department of Neurology, University of Iowa College of Medicine, Iowa City, IA 52242.

AJNR 8:1027–1030, November/December 1987

0195–6108/87/0806–1027

© American Society of Neuroradiology

as none of these individuals were referred for cerebral angiography.

All patients had unenhanced CT exams 0–15 days prior to cerebral angiography. Angiograms were performed with percutaneous transfemoral technique. Selective arterial injections were done on the basis of CT location of the lobar hematoma. The filming sequence routinely included two exposures per second for 4 sec, followed by one exposure per second for 6 sec to facilitate visualization of the venous system. The data collected and tabulated for each patient included CT location of the lobar hematoma, presence or absence of coexisting intraventricular and/or subarachnoid hemorrhage, angiographic findings, and underlying origin based on available clinical, radiologic, surgical, and pathologic data. Hypertension was defined according to criteria established by the 1984 report of the Joint National Committee on Detection, Evaluation, and Treatment of High Blood Pressure [12]. Some of the examinations reviewed for this study were obtained from patients previously described [11, 13].

Results

Over the 5-year interval, 67 patients had cerebral angiography for nontraumatic lobar ICH. Patients included 34 men and 33 women, ranging in age from 6 to 84 years, with a mean age of 52 years. Fifty-two (78%) angiograms were performed within 24 hr of diagnosis by CT. There were no serious complications (death, stroke, or arterial thromboses) secondary to angiography. Surgical or pathologic studies of the hematomas were available in 43 cases (64%).

Angiography was diagnostic, or provided valuable diagnostic information to aid in the search for an underlying cause of lobar ICH, in 29 patients (43%) (Table 1). Diagnostic findings included 17 aneurysms, seven AVMs, two cases of a neovascular mass, two cases of superior sagittal sinus thrombosis, and one case of multifocal segmental arterial dilatation and narrowing with contrast extravasation compatible with a "vasculitis." The latter patient was a 24-year-old postpartum woman who was eventually found to have metastatic choriocarcinoma. The two cases of a neovascular mass were both found to be malignant gliomas upon pathologic examination. Of the 17 aneurysms, all were saccular except for one mycotic aneurysm in a distal middle cerebral artery branch. Diagnostic

angiographic findings were less frequent in patients older than 70 years (Fig. 1).

Thirty-three patients had "pure" lobar ICH (i.e., without coexistent IVH or SAH), 12 patients had associated IVH, 12 patients had accompanying SAH, and 10 patients had both SAH and IVH associated with their lobar hematomas. "Pure" lobar hematomas and lobar ICH accompanied by IVH had a lower frequency of diagnostic angiographic findings than did lobar hematomas with SAH (Table 2). Of the 22 patients with lobar ICH and associated SAH, angiography was diagnostic in 17 cases (77%). In the absence of SAH, diagnostic angiographic findings were present in only 12 (27%) of 45 cases of lobar ICH.

The epicenters of the lobar hematomas in this series were as follows: temporal lobe (26), frontal lobe (18), parietal lobe (17), occipital lobe (3), two or more locations (3). Diagnostic angiographic findings were more frequent for hematomas originating in the frontal and temporal lobes than for those arising in either the occipital or parietal lobes (Table 3). Superior sagittal sinus thrombosis was found to be the underlying cause in two of the three cases in which multiple lobar hematomas were present on the initial CT examination.

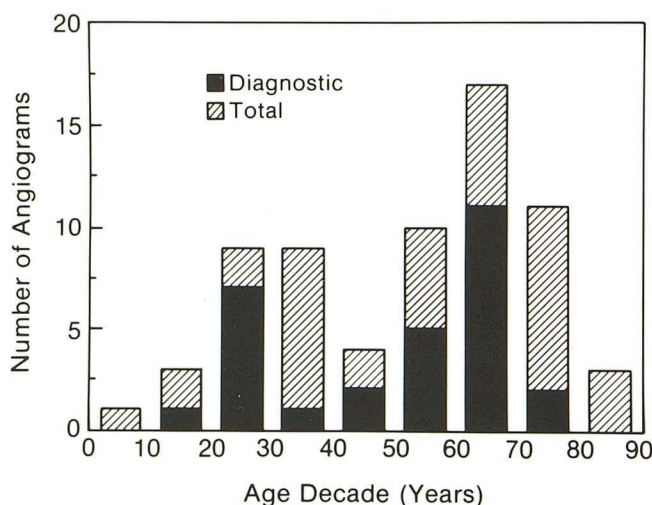


Fig. 1.—Distribution of diagnostic and total cerebral angiograms per age decade in patients with nontraumatic lobar intracerebral hemorrhage.

TABLE 1: Angiographic Findings in 67 Patients with Nontraumatic Lobar Intracerebral Hemorrhage

Negative (normal examination)	4
Nonspecific findings (n = 34)	
Mass effect	30
Slow intracranial flow	1
No intracranial flow	1
"Luxury" perfusion	1
Arterial spasm	1
Diagnostic findings (n = 29)	
Aneurysm	17
(Saccular, 16)	
(Mycotic, 1)	
Arteriovenous malformation	7
Sagittal sinus thrombosis	2
Neovascular mass	2
"Vasculitis" ^a	1

^a Arteriogram revealed multifocal segmental arterial dilatation and narrowing with intraluminal thrombus and contrast extravasation.

TABLE 2: Diagnostic Angiograms with Respect to CT Patterns of Intracerebral Hemorrhage

	Total Cases	Diagnostic Angiograms	% Diagnostic Angiograms
Pure lobar ICH	33	10	30
Lobar ICH + IVH	12	2	17
Lobar ICH + IVH + SAH	10	7	70
Lobar ICH + SAH	12	10	83
Diagnostic angiograms in lobar ICH without SAH:			27%
Diagnostic angiograms in lobar ICH with SAH:			77%

Note.—ICH = intracerebral hemorrhage; IVH = intraventricular hemorrhage; SAH = subarachnoid hemorrhage.

TABLE 3: Diagnostic Angiograms with Respect to CT Location of Lobar Hematoma and CT Pattern of Hemorrhage

	Total Cases	Diagnostic Angiograms	% Diagnostic Angiograms
Frontal lobar ICH			
Pure	9	5	56
+IVH	2	0	0
+IVH + SAH	5	3	60
+SAH	2	1	50
All cases	18	9	50
Temporal lobar ICH			
Pure	7	2	29
+IVH	7	2	29
+IVH + SAH	4	4	100
+SAH	8	8	100
All cases	26	16	62
Parietal lobar ICH			
Pure	13	2	15
+IVH	3	0	0
+IVH + SAH	1	1	100
+SAH	0	—	—
All cases	17	3	18
Occipital lobar ICH			
Pure	3	0	0
+IVH	0	—	—
+IVH + SAH	0	—	—
+SAH	0	—	—
All cases	3	0	0
Multiple lobar ICH			
Pure	1	1	100
+IVH	0	—	—
+IVH + SAH	0	—	—
+SAH	2	1	50
All cases	3	2	67

Note.—ICH = intracerebral hemorrhage; IVH = intraventricular hemorrhage; SAH = subarachnoid hemorrhage.

We found no anatomic explanation for the third case of multiple lobar ICH.

After reviewing available clinical, radiologic, surgical, and pathologic data, definite origins could be determined in 37 of the 67 cases (Table 4). There were 17 aneurysms (range: 19–68 years; mean, 51.4 years), 10 AVMs (range: 13–76 years; mean, 43.7 years), four cerebral metastases (choriocarcinoma, breast carcinoma, melanoma, and renal cell carcinoma; range: 24–55 years; mean, 39.5 years), two malignant gliomas (ages 61 and 65), two pathologically documented cases of cerebral amyloid angiopathy (ages 63 and 70), and two cases of superior sagittal sinus thrombosis (ages 28 and 68). Presumptive origins were found in 17 patients: arterial hypertension in 12 (age range, 34–84 years; mean, 58.8 years); alcohol abuse in four (age range, 35–61 years; mean, 42.5 years), and anticoagulant therapy in one (age 70). This last individual, who was also hypertensive, had a prothrombin time of 19 sec (normal = 10–13 sec) on admission. No underlying origin could be uncovered in 13 cases.

Discussion

CT patterns in nontraumatic lobar ICH influence the frequency of diagnostic angiographic findings. The increased frequency of diagnostic angiograms in patients with associ-

TABLE 4: Origins of Lobar Intracerebral Hemorrhage Based on Clinical, Radiologic, Surgical, and Pathologic Data

Definite (<i>n</i> = 37) (55.2%)	
Aneurysm	17 (25%)
(Saccular, 16)	
(Mycotic, 1)	
Arteriovenous malformation	10 (15%)
Cerebral metastases	4 (6%)
Gliomas	2 (3%)
Cerebral amyloid angiopathy	2 (3%)
Superior sagittal sinus thrombosis	2 (3%)
Presumptive (<i>n</i> = 17) (25.4%)	
Arterial hypertension	12 (18%)
Alcohol abuse	4 (6%)
Anticoagulant therapy ^a	1 (2%)
Undetermined (<i>n</i> = 13) (19.4%)	

^a This individual also had a history of chronic systemic hypertension.

ated SAH on CT can be directly attributed to the higher number of saccular aneurysms in this subgroup. Of the 21 patients with lobar hematomas accompanied by SAH, 14 were secondary to ruptured saccular aneurysms. A lobar hematoma in direct continuity with the sylvian fissure is virtually diagnostic of an aneurysm, especially in the presence of adjacent SAH [10, 14]. Of the seven remaining patients, four were found to have AVMs (two of these were diagnosed only after pathologic examination), one patient was found to have superior sagittal sinus thrombosis, and in two patients, no definite cause could be determined (although systemic hypertension was probably responsible in one of these cases).

An increased frequency of diagnostic angiograms with a frontal or temporal location of the lobar hematoma was noted whether or not there was associated SAH on CT. While this propensity may in part be due to an increased frequency of aneurysms in these regions, this relationship was maintained even when aneurysms were excluded. Disregarding all aneurysms, there were eight diagnostic cerebral angiograms in 27 patients (30%) with frontal or temporal lobar ICH compared with three diagnostic studies in the 20 cases (15%) of parietal or occipital lobar hematomas. We speculate that undiagnosed cerebral amyloid angiopathy (CAA) may have been partially responsible for the decreased frequency of diagnostic angiographic findings in parietal and occipital lobar hemorrhages. Amyloid angiopathy, which is becoming an increasingly recognized cause of nontraumatic, nonhypertensive lobar ICH in the elderly population, appears to have a propensity for the cortical arterioles of the parietal and occipital regions [15]. Diagnosis of CAA can be made only by histologic examination; cerebral angiography is nonspecific [6]. Both the pathologically proved cases of amyloid angiopathy had parietal lobe hematomas. Five of the seven cases of nontraumatic intracerebral hemorrhage due to CAA described by Wagle et al. [6] had parietal or occipital involvement. Amyloid angiopathy may have also contributed to the decreased frequency of diagnostic angiograms observed in patients older than 70 years.

Our data confirm the value of cerebral angiography in the search for an origin of nontraumatic lobar ICH. Diagnostic

findings or valuable diagnostic clues were found in 43% of cases. However, it should be emphasized that nonspecific findings or negative studies do not exclude significant intracranial disease [16, 17]. Three of the four metastatic lesions in this series had nondiagnostic angiograms. Three of the 10 AVMs were diagnosed only by pathologic means. Stagnant flow or thrombosis is thought to be responsible for the non-opacification of some AVMs at arteriography [18].

Several other observations were made. All metastatic lesions in this series presented as "pure" lobar hematomas. Specific origins included melanoma, choriocarcinoma, renal cell carcinoma, and breast carcinoma. In two of the four patients, the spontaneous lobar ICH preceded clinical diagnosis. The literature suggests that metastases of melanoma and choriocarcinoma are most prone to hemorrhage, and that intraventricular and/or subarachnoid extension is not uncommon [3-5, 17].

Cortical or dural venous thrombosis should be considered in the presence of lobar ICH, especially if the hematomas are multiple. While the underlying pathology is actually that of a hemorrhagic venous infarction, one may not be able to distinguish it from a true lobar hematoma on CT. However, "lobar hematoma" is a relatively uncommon CT finding in cases of cerebral venous thrombosis [19, 20]. Cerebral amyloid angiopathy and metastases may also cause multiple lobar intracerebral hemorrhages [5, 21].

Our data agree with other reports that systemic hypertension is not the underlying cause in most nontraumatic lobar hematomas [1, 11]. The majority of lobar hemorrhages in our series had an anatomic explanation, the most common cause being aneurysm or AVM. In the subgroup of "pure" lobar hematomas, 16 of the 33 cases had an anatomic explanation: four AVMs, four metastases, three aneurysms, two primary neoplasms, two cerebral amyloid angiopathy, and one superior sagittal sinus thrombosis. Presumptive nonanatomic causes were found in 10 (30%) of the 33 cases of "pure" lobar ICH: six patients had arterial hypertension and four patients had an alcohol abuse history. Alcohol has been associated with an increased frequency of intracerebral hemorrhage [22]. In seven (21%) of the 33 cases of "pure" lobar hematomas, no underlying cause could be determined.

Cerebral angiography is a valuable diagnostic technique for patients with nontraumatic lobar ICH of uncertain origin. While a higher frequency of diagnostic angiograms can be expected in patients with frontal or temporal lobar hematomas or those with associated SAH, the impact upon patient management of a surgically correctable vascular lesion or a neoplasm warrants consideration of angiography in all cases. Routine long-film sequences are advocated to ensure optimal visualization of venous anatomy in order to identify AVMs or cerebral venous thromboses. A negative or nondiagnostic cerebral angiogram does not exclude significant intracranial disease;

and further diagnostic testing, such as enhanced CT or MR imaging, should be considered for these patients [4, 23, 24].

REFERENCES

1. Ropper AH, Davis KR. Lobar cerebral hemorrhages: acute clinical syndromes in 26 cases. *Ann Neurol* 1980;8:141-147
2. McCormick WF, Rosenfield DB. Massive brain hemorrhage: a review of 144 cases and an examination of their causes. *Stroke* 1973;4:949-954
3. Scott M. Spontaneous intracerebral hematoma caused by cerebral neoplasms. *J Neurosurg* 1975;42:338-342
4. Gildersleeve N, Koo AH, McDonald CJ. Metastatic tumor presenting as intracerebral hemorrhage. *Radiology* 1977;124:109-112
5. Mandybur TI. Intracranial hemorrhage caused by metastatic tumors. *Neurology* 1977;27:650-655
6. Wagle WA, Smith TW, Weiner M. Intracerebral hemorrhage caused by cerebral amyloid angiopathy: radiographic-pathologic correlation. *AJNR* 1984;5:171-176
7. Patel DV, Hier DB, Thomas CM, Hemmati M. Intracerebral hemorrhage secondary to cerebral amyloid angiopathy. *Radiology* 1984;151:397-400
8. Yu YJ, Cooper DR, Wellenstein DE, Block B. Cerebral angitis and intracerebral hemorrhage associated with methamphetamine abuse. *J Neurosurg* 1983;58:109-111
9. Bessen HA. Intracranial hemorrhage associated with phenylcyclidine abuse. *JAMA* 1982;248:585-586
10. Weisberg L. Computerized tomography in intracranial hemorrhage. *Arch Neurol* 1979;36:442-446
11. Toffol GJ, Biller J, Adams HP, Smoker WRK. The predicted value of arteriography in nontraumatic intracerebral hemorrhage. *Stroke* 1986;17:881-883
12. The 1984 report of the Joint National Committee on Detection, Evaluation, and Treatment of High Blood Pressure. *Arch Intern Med* 1984;144:1045-1057
13. Toffol GJ, Biller J, Adams HP Jr. Nontraumatic intracerebral hemorrhage in young adults. *Arch Neurol* 1987;44:483-485
14. Hayward RD, O'Reilly GVA. Intracerebral hemorrhage: accuracy of computerized transverse axial scanning in predicting the underlying etiology. *Lancet* 1976;1:1-4
15. Vinters HV, Gilbert JJ. Cerebral amyloid angiopathy II: the distribution of amyloid vascular changes. *Stroke* 1983;14:924-928
16. Bitoh S, Hasegawa H, Fujiwara M, Sakurai M. Angiographically occult vascular malformations causing intracranial hemorrhage. *Surg Neurol* 1982;17:35-42
17. Zimmerman RA, Bilaniuk LT. Computed tomography of acute intracerebral tumoral hemorrhage. *Radiology* 1980;135:355-359
18. Kramer RA, Wing SD. CT of angiographically occult cerebral vascular malformations. *Radiology* 1977;123:649-652
19. Buonanno FS, Moody DM, Ball MR, Laster DW. Computed cranial tomographic findings in cerebral sinovenous occlusion. *J Comput Assist Tomogr* 1978;2:281-290
20. Bousser MG, Chiras J, Borries J, Castaigne P. Cerebral venous thrombosis: a review of 38 cases. *Stroke* 1985;16:199-213
21. Tucker WS, Bilbao JM, Klodawsky H. Cerebral amyloid angiopathy and multiple intracerebral hematoma. *Neurosurgery* 1980;7:611-614
22. Moorthy G, Price TR, Turhim S, et al. Relationships between recent alcohol intake and stroke type? The NINCDS Stroke Data Bank. *Stroke* 1986;17:62 (abstr)
23. Golden JB, Kramer RA. The angiographically occult cerebrovascular malformation. *J Neurosurg* 1978;48:292-296
24. Lemme-Plaghos L, Kucharczk W, Brant-Zawadzki M, et al. MRI of angiographically occult vascular malformations. *AJNR* 1986;7:217-222, *AJR* 1986;146:1223-1228