



## Get Clarity On Generics

Cost-Effective CT & MRI Contrast Agents

 FRESENIUS  
KABI

[WATCH VIDEO](#)

# AJNR

## The vidian artery in childhood tonsillar hypertrophy.

J R Jenkins

*AJNR Am J Neuroradiol* 1988, 9 (1) 141-143

<http://www.ajnr.org/content/9/1/141>

This information is current as  
of August 18, 2025.

# The Vidian Artery in Childhood Tonsillar Hypertrophy

John R. Jenkins<sup>1,2</sup>

**Cerebral arteriography performed in two children for cerebral pathology incidentally revealed prominent arterial supply to pharyngeal tonsillar tissue arising directly from the internal carotid arteries bilaterally. Embryologic considerations seem to indicate developmental origins of this vessel from early emanations of the first fetal aortic arch. Clinical implications revolve around the possible relation of the vidian artery to serious hemorrhage during or after otherwise uncomplicated tonsillectomy.**

The anomalous anatomic vascular patterns of the cervical carotid system involve variations of both the internal and external carotid arteries [1-10]. This paper deals with instances of symmetric vessels originating from the petrous internal carotid arteries, which supplied the posterosuperior pharyngeal soft tissues in two children with hypertrophied but uninfamed tonsils.

## Subjects and Methods

Two children, ages 4 and 10 years old, were studied with arterial digital subtraction angiography (ADSA) as part of their preoperative evaluation for cerebral mass lesions. One of these patients also had an IV dynamic CT (IVDCT) as part of the work-up. Subsequent clinical investigation revealed no evidence of inflamed or abnormally enlarged tonsillar tissue considering the age of the patients. The two children have continued to be treated and followed for their primary cerebral disease for 1 year without change in status of the initial nasopharyngeal observations as judged by direct examination and static CT.

## Results

The first patient, a 10-year-old girl, had a small arterial branch originating from the distal internal carotid artery bilaterally, coursing anteromedially. A rounded blush was seen extending into the venous phase. No abnormal venous drainage was present. A subsequent lateral radiograph of the nasopharynx revealed prominence of the nasopharyngeal soft tissues compatible with hypertrophied tonsils, a finding that was not considered abnormal for the patient's age (Fig. 1). The second patient, a 4-year-old boy, had identical findings to the first subject on ADSA and static CT. A supplemental IVDCT to further characterize the nasopharyngeal tissue showed the nonspecific rapid enhancement of the hypertrophied tonsils corresponding to the blush observed on the angiogram (Fig. 2).

## Discussion

The normal anatomy of the cervical carotid vascular system, including variants, makes allowance for the vascular structures observed in these two subjects. The fact that these aberrant arteries are bilateral suggests their symmetric developmental nature. The absence of regional clinical disease, which might parasitize an

Received October 20, 1986; accepted after revision August 9, 1987.

<sup>1</sup> Department of Radiology, Section of Neuroradiology, King Faisal Specialist Hospital and Research Centre, Riyadh 11211, Saudi Arabia.

<sup>2</sup> Present address: Huntington Medical Research Institutes, MR Imaging Laboratory, 10 Pico St., Pasadena, CA 91105-3201. Address reprint requests to J. R. Jenkins.

**AJNR 9:141-143, January/February 1988**

0195-6108/88/0901-0141

© American Society of Neuroradiology

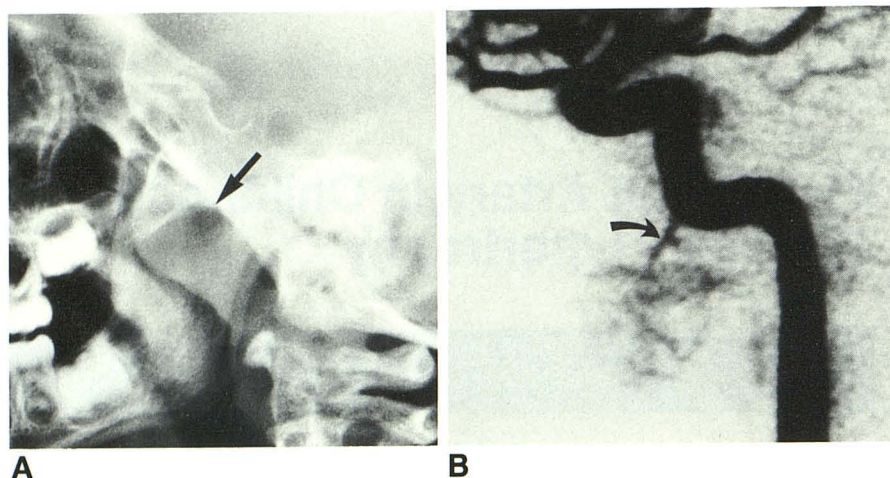


Fig. 1.—10-year-old girl with left hemispheric glioblastoma.

A, Lateral view of nasopharynx shows hyperthrophied adenoid tissue (arrow).

B, Lateral view of arterial digital subtraction angiogram during left internal carotid injection demonstrates single artery supplying the capillary blush, which corresponds to nasopharyngeal tissue seen in A (arrow).

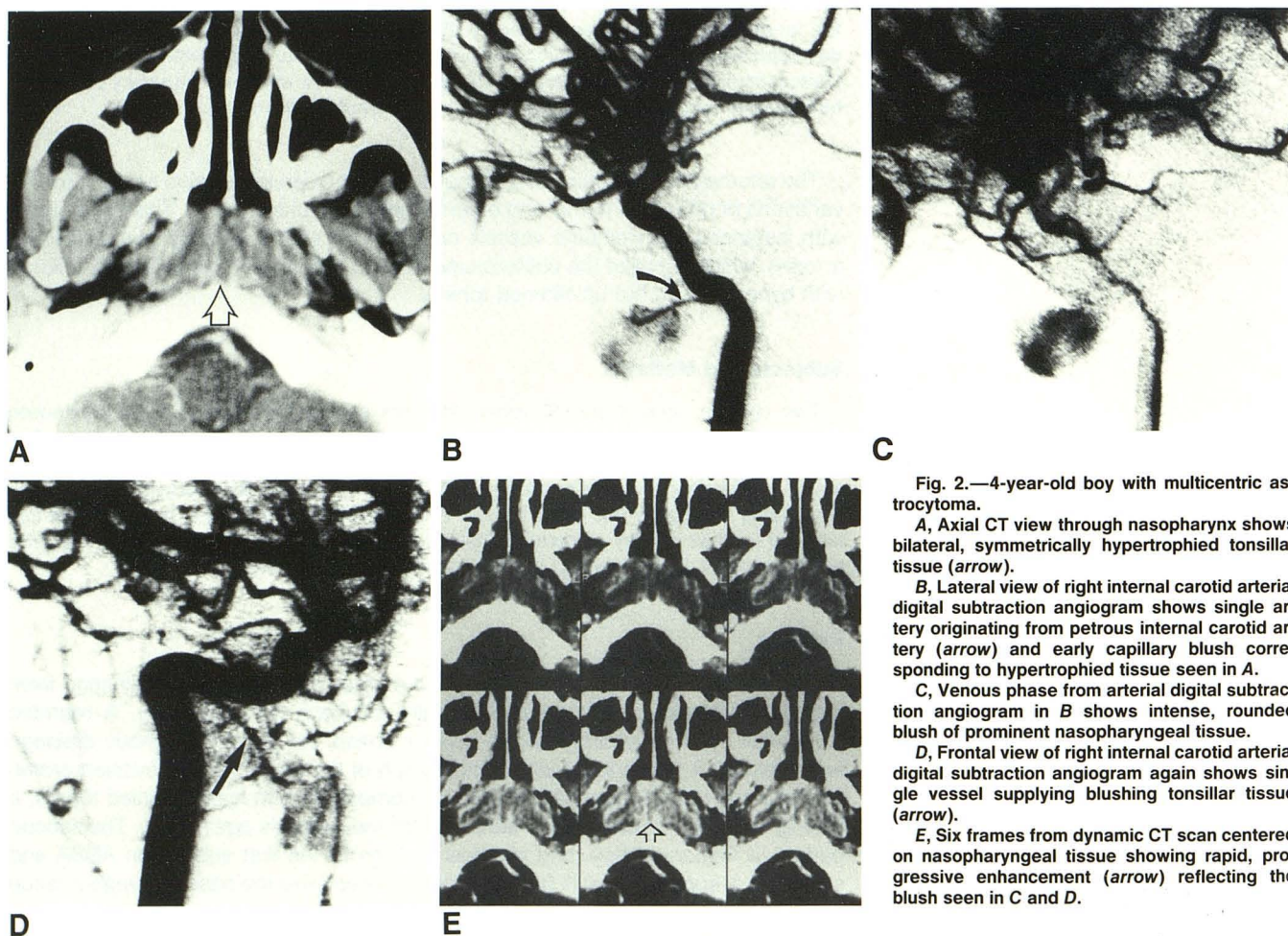


Fig. 2.—4-year-old boy with multicentric astrocytoma.

A, Axial CT view through nasopharynx shows bilateral, symmetrically hypertrophied tonsillar tissue (arrow).

B, Lateral view of right internal carotid arterial digital subtraction angiogram shows single artery originating from petrous internal carotid artery (arrow) and early capillary blush corresponding to hypertrophied tissue seen in A.

C, Venous phase from arterial digital subtraction angiogram in B shows intense, rounded blush of prominent nasopharyngeal tissue.

D, Frontal view of right internal carotid arterial digital subtraction angiogram again shows single vessel supplying blushing tonsillar tissue (arrow).

E, Six frames from dynamic CT scan centered on nasopharyngeal tissue showing rapid, progressive enhancement (arrow) reflecting the blush seen in C and D.

otherwise insignificant blood supply, supports a developmental premise of fetal persistence.

The embryologic development of this area is complex, and begins with the emergence of the fetal aortic arches. At the

4-mm-length fetal stage, the first arch gives rise to the mandibular artery. With partial involution of the mandibular artery by the 5–9-mm stage, the ventral pharyngeal artery assimilates that vessel's distal branch supply. The vestige of the

embryonic mandibular artery gives rise to the small inconstant branches supplying the upper posterior nasopharynx directly from the petrous internal carotid artery, including the adult mandibular artery and the vidian artery. Through a complex series of outgrowths, involutions, and assimilations, first the stapedia artery and finally the external carotid artery take over the remaining major vascular supply of the region [7, 11–14]. Intimate anastomoses between the external carotid system and branches of the internal carotid artery thus exist between corresponding ramifications of the vidian artery with the internal maxillary artery, the ascending pharyngeal artery, and the adult mandibular artery. The observed prominence of the vidian arteries in the current subjects may represent a juvenile anatomic manifestation. Perhaps in certain subjects the hypertrophied tissue in the tonsillar region in childhood maintains varying degrees of fetal circulation. In adulthood, the vidian artery may simply involute with normal regression of the nasopharyngeal lymphoid tissue. This would functionally explain the angiographic absence of this artery in most adults. Furthermore, the radioanatomic observations of this artery in normal and abnormal circumstances in adults confirms its persistence into adulthood, albeit in a variably hypoplastic state [3, 7, 10].

However, the real importance of these observations is clinical. In recent years the indications for tonsillectomy have decreased and have been modified radically [15–18]. This is fortunate in view of the catastrophic and sometimes fatal hemorrhaging not infrequently associated intraoperatively and perioperatively in subjects undergoing simple tonsillectomy [19–25]. It is tempting to postulate that these sometimes fatal hemorrhages are related to prominent vidian arterial circulation. Certainly, large vessels on the order of those shown in the present cases, feeding otherwise innocent if inflamed tonsillar tissue, must be unsuspected by the surgeon. It is easy to understand why serious bleeding might occur if such an enlarged vessel were inadvertently lacerated. Because of its rich anastomotic patterns, bleeding from the vidian artery cannot be controlled by simple ligation of either the external or the internal carotid arteries selectively. After a detailed subtraction angiographic evaluation, endovascular occlusion or even angiographic trapping may be necessary in the treatment of uncontrollable hemorrhaging emanating from this region.

Clearly, further understanding of this anatomic vascular structure in children is indicated. With fewer tonsillectomies being performed, more stringent guidelines being observed, and with broader alternatives available, the possibility of the presence of the infantile vidian artery in surgical candidates warrants consideration. Perhaps in selected cases preoperative angiography should be considered for pediatric patients scheduled for surgery for benign or malignant mass lesions of any origin in the posterior nasopharynx.

## ACKNOWLEDGMENTS

I thank Martha A. Loera for manuscript preparation, Mrs. C. Jenkins for manuscript research, and the Radiology Department of the King Faisal Specialist Hospital for technical assistance with the illustrations.

## REFERENCES

1. Asamoah DK, Foy PM. Some radiological abnormalities of the cervical carotid artery and their clinical significance. *Clin Radiol* 1979;30:593–599
2. Benton JR, Wilson GH. Cerebral angiography: normal anatomy and variations in adults and children. *Semin Roentgenol* 1971;6:17–33
3. Dilenge D, Heon M. The internal carotid artery. In: Newton TH, Potts DG, eds. *Radiology of the skull and brain*, vol. 2. St. Louis: Mosby, 1974:1202–1245
4. Djindjian R, Merland JJ. *Super-selective arteriography of the external carotid artery*. New York: Springer-Verlag, 1978
5. Murie JA, Sheldon CD, Quin RO. Radiographic anatomy of the extracranial carotid artery. *J Cardiovasc Surg* 1985;26:143–146
6. Newton TH. The abnormal external carotid artery. In: Newton TH, Potts DG, eds. *Radiology of the skull and brain*, vol. 2. St. Louis: Mosby, 1974:1275–1332
7. Osborn AG. The vidian artery: normal and pathologic anatomy. *Radiology* 1980;136:373–378
8. Quisling RG, Rhoton AL. Intrapetrous carotid artery branches: radioanatomic analysis. *Radiology* 1979;131:133–136
9. Quisling RG. Intrapetrous carotid artery branches: pathological application. *Radiology* 1980;134:109–113
10. Teal JS, Rumbaugh CL, Segall HD, Bergeron RT. Anomalous branches of the internal carotid artery. *Radiology* 1973;106:567–573
11. Hamilton WJ, Mossman HW. *Human embryology*. Baltimore: Williams & Wilkins, 1972
12. Lasjaunias PL. *Craniofacial and upper cervical arteries*. Baltimore: Williams & Wilkins, 1981
13. Padgett DH. The development of the cranial arteries in the human embryo. *Contrib Embryol* 1948;32:205–261
14. Warwick R, Williams PL. *Gray's anatomy*. Philadelphia: Saunders, 1973
15. Indications for tonsillectomy and adenoidectomy: Phase I. Sponsored by the National Cancer Institute assisted by the Office for Medical Applications of Research, NIH. *Conn Med* 1979;43:791–792
16. Carden TS. Tonsillectomy—trials and tribulations. Report on the National Institutes of Health Consensus Conference on Indications for Tonsillectomy and Adenoidectomy. *JAMA* 1978;240:1961–1962
17. Davidson TM, et al. Tonsillectomy and adenoidectomy—its indications and its problems. *West J Med* 1980;133:451–454
18. Shaikh W, Vayda E, Feldman W. A systematic review of the literature on evaluative studies of tonsillectomy and adenoidectomy. *Pediatrics* 1976;57:401–407
19. Capper WR, Randall C. Post-operative hemorrhage in tonsillectomy and adenoidectomy in children. *J Laryngol Otol* 1984;98:363–365
20. Carmody D, Vamadevan T, Cooper SM. Post tonsillectomy hemorrhage. *J Laryngol Otol* 1982;96:635–638
21. Kumar R. Secondary hemorrhage following tonsillectomy/adenoidectomy. *J Laryngol Otol* 1984;98:997–998
22. Nathan MD, et al. Massive post-tonsillectomy hemorrhage. *South Med J* 1981;74:1153–1156
23. Osguthorpe JD, et al. Internal carotid artery as source of tonsillectomy and adenoidectomy hemorrhage. *Otolaryngol Head Neck Surg* 1981;89:758–762
24. Pratt LW, et al. Tonsillectomy and adenoidectomy: incidence and mortality. *Otolaryngol Head Neck Surg* 1979;87:159–166
25. Roy A, La Rosa CD, Vecchio YA. Bleeding following tonsillectomy. A study of electrocoagulation and ligation techniques. *Arch Otolaryngol* 1976;102:9–10