



## Get Clarity On Generics

Cost-Effective CT & MRI Contrast Agents

**FRESENIUS  
KABI**

[WATCH VIDEO](#)

# AJNR

### **Conventional vs computed radiography: evaluation of myelography.**

P J Yang, G W Seeley, R F Carmody, J F Seeger, M T Yoshino  
and B Mockbee

*AJNR Am J Neuroradiol* 1988, 9 (1) 165-168  
<http://www.ajnr.org/content/9/1/165>

This information is current as  
of August 8, 2025.

# Conventional vs Computed Radiography: Evaluation of Myelography

Peter J. Yang<sup>1</sup>  
 George W. Seeley  
 Raymond F. Carmody  
 Joachim F. Seeger  
 Mark T. Yoshino  
 Brent Mockbee

**A prospective study was performed to compare the diagnostic efficacy of conventional film-screen (FS) imaging with computed radiography (CR) in myelography. Forty examinations were done with both methods. Digital myelography was found to have diagnostic accuracy equal to that of conventional film-screen examinations.**

Digital imaging is becoming widely used in diagnostic radiology, and digital subtraction angiography (DSA) is now generally accepted [1-3]. Several studies have evaluated digital imaging using a computed radiography system for chest examinations [4-10] and for excretory urography [11]. This prospective study uses receiver operating curve analysis [12, 13] to compare the diagnostic accuracy of conventional film-screen radiography (FS) and computed radiography (CR) in myelography.

## Materials and Methods

Digital imaging was performed using the Toshiba Model 201 computed radiography system. Standard (10 × 12 in.) digital imaging plates (matrix: 1670 × 2010 pixels) with a pixel size of 0.15 mm and a maximum resolution of approximately 3.3 lp/mm were used. The imaging plates were exposed using standard radiographic equipment and read by a helium-neon laser. The information was digitized and hard-copy (film) was created for purposes of the study. The hard-copy format for our CR system displays its images at two-thirds the size of the conventional FS radiographs. This system routinely provides unmodified and frequency-modified (edge-enhanced) images side by side, and both types of images were evaluated in all cases (Fig. 1).

The conventional film-screen combination consisted of Dupont 7L film and Dupont Quanta III screens (400 speed system). The measured resolution of this system was 5 lp/mm.

Forty consecutive myelographic examinations were obtained for patients who had consented to both conventional and digital radiography. Nine cervical and 31 thoracolumbar myelograms were performed. All myelograms were done with nonionic water-soluble contrast agents. The FS and CR images were obtained in an alternating manner during each examination.

Four experienced radiologists viewed all of the images in a double-blinded fashion. The examinations were separated into two groups: group A (cases 1-20) and a group B (cases 21-40). Two radiologists read the CR studies from group A and the FS studies from group B, while the other two radiologists read the FS studies from group A and the CR studies from group B. In a subsequent viewing session, the radiologists evaluated the myelographic studies with the method they had not yet seen. These two sessions were separated to determine if there was any viewer bias from seeing the same case a second time with a different method.

Data accumulated included the diagnosis (with a level of certainty), subjective evaluation of image quality, and visualization of normal structures (see Table 1). The correct diagnoses were established using a consensus panel. The diagnostic information was analyzed using receiver operating curves.

There were 18 normal and 22 abnormal myelographic studies. The diagnostic categories

Received January 21, 1987; accepted after revision August 12, 1987.

<sup>1</sup> All authors: Department of Radiology, Division of Neuroradiology, Arizona Health Sciences Center, Tucson, AZ 85724. Address reprint requests to P. J. Yang.

**AJNR 9:165-168, January/February 1988**  
 0195-6108/88/0901-0165

© American Society of Neuroradiology



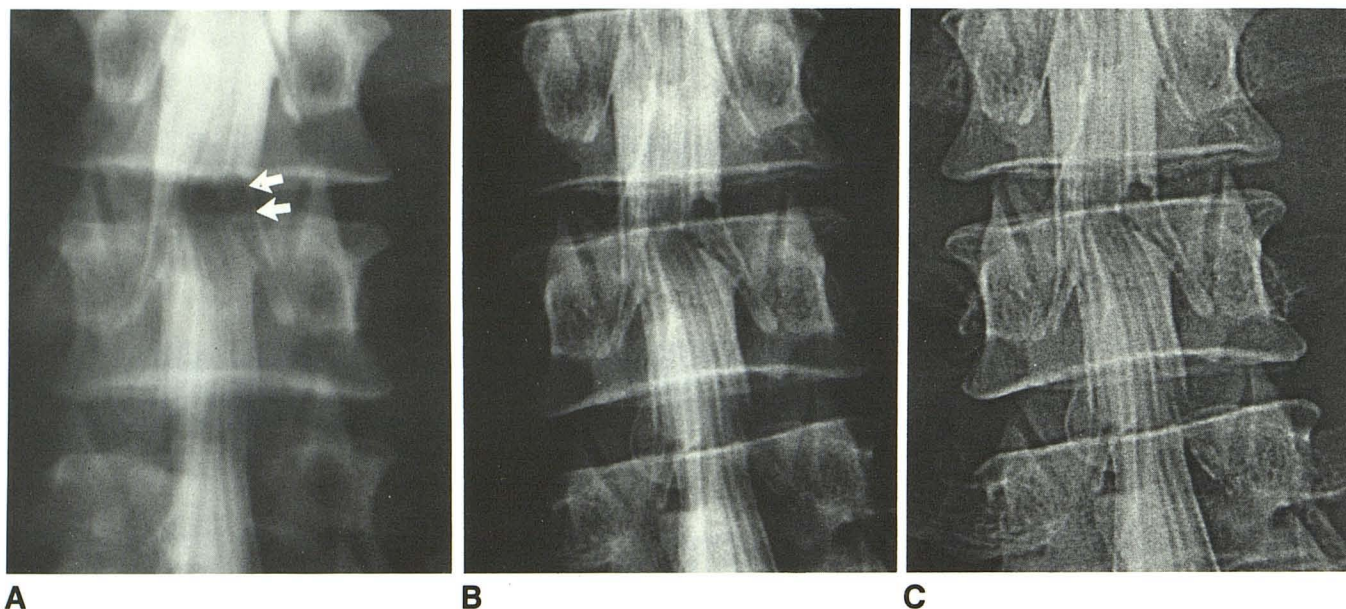


Fig. 1.—A, Film-screen lumbar myelography shows defect from right-sided intradural herniated disk at L4–L5 level (arrows). B, Computed radiography image of same case. C, Frequency-modified (edge-enhanced) image of same case.

TABLE 1: Case Checklist

1. Determine whether study is normal or abnormal by using six-point scale for degree of certainty (1 = abnormal, absolutely certain; 2 = abnormal, relatively certain; 3 = abnormal, guessing; 4 = normal, guessing; 5 = normal, relatively certain; 6 = normal, absolutely certain). If abnormal, characterize and localize abnormality.
2. Evaluate following image-quality characteristics by using four-point scale (1 = not adequate; 2 = minimally adequate; 3 = moderately adequate; 4 = maximally adequate).
  - A. Spatial resolution
  - B. Contrast resolution
  - C. Penetration of contrast column
  - D. Usefulness of frequency-modified image (CR only)
3. Determine visualization of following structures by using four-point scale (1 = not seen; 2 = seen, but not adequate; 3 = seen, adequate; 4 = seen, excellent).
  - A. Thecal sac
  - B. Nerve roots/nerve root sleeves
  - C. Spinal cord/conus medullaris (if applicable)
  - D. Bony structures

in the 22 abnormal studies included spinal stenosis (nine), herniated disk (nine), neoplasm (three), and trauma (one).

## Results

The first statistical analysis evaluated whether there was viewer bias resulting from seeing the cases a second time (with the other imaging method). No significant difference in observer response was noted. Therefore, the responses for the first and second sessions were combined for all subsequent analyses.

The receiver operating curves for the pooled observer responses to both imaging methods are depicted in Figure 2.

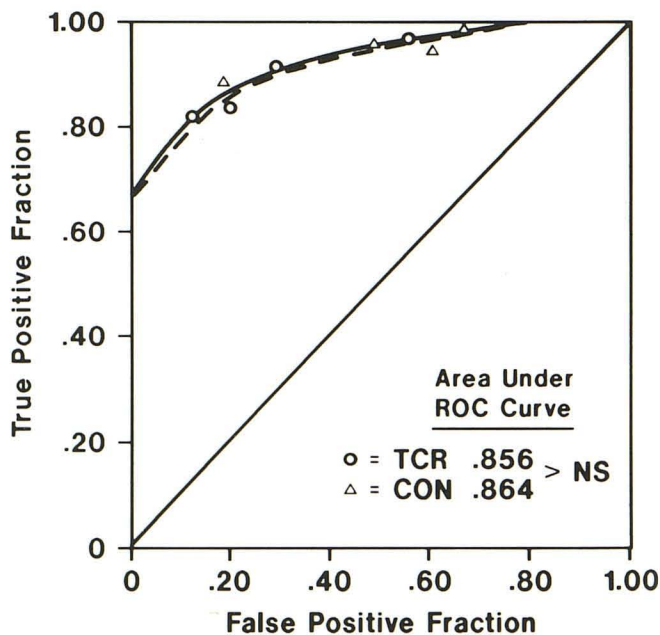


Fig. 2.—Receiver operating curves comparing film-screen (solid line) with computed radiography (dashed line). There is no statistical difference between the two curves.

The area under the curve for the computed radiography was .856 and for the conventional film-screen images it was .864. The difference between the two, using Metz's [13] methods for comparing two receiver operating curves was not significant ( $z = 0.1856$ ). The readers were equally sensitive (CR =



**TABLE 2: Computed Radiography (CR) vs Film-Screen (FS)  $n = 160$  (40 Cases  $\times$  Four Observers)**

	Number of Cases Rated Excellent (CR/FS)	Number of Cases Rated Adequate (CR/FS)	Number of Cases Rated Minimal or Inadequate (CR/FS)
Spatial resolution	121/155	35/5	4/0
Contrast resolution	109/128	39/27	12/5
Penetration of contrast column	134/152	24/7	2/1
Visualization of thecal sac	131/143	27/17	2/0
Visualization of nerve roots	120/138	37/20	3/2
Visualization of nerve root sleeves	89/109	62/44	8/6

.92; FS = .97) and specific (CR = .71; FS = .69) in differentiating the normal from the abnormal studies ( $p < .01$ ).

There were slight differences between the two imaging methods judging from the response patterns of the readers to the section of the checklist (Table 1) dealing with image quality and visualization of normal structures. Analysis of individual items showed a slight shift in observer responses in the following categories: (1) adequacy of spatial resolution; (2) adequacy of contrast resolution; (3) penetration of contrast column; (4) visualization of thecal sac, and (5) visualization of nerve roots and nerve root sleeves. In all categories, the shift in response usually involved a change from a particular case being rated excellent in FS images to being judged adequate on the corresponding CR study (Table 2). However, there was no statistically significant difference in the number of images categorized as inadequate or nondiagnostic when comparing CR and FS using a t-test ( $t = .7977$ ,  $df = 7$ ).

The radiation exposure for conventional radiography was approximately one-third more than that used for the CR imaging. This was based on relative kVp and mAs settings needed to obtain adequate images with each technique using the same radiographic equipment.

## Discussion

Digital radiography has been shown to have potential for imaging the chest and genitourinary systems [3–11]. Barnes et al. [14] reported favorable results using a DSA system for myelography in four infants with spinal dysraphism. However, no systematic prospective study comparing conventional and computed radiography in evaluation of myelography has been reported.

Recent advances have led to an improvement in the quality of digital images. Studies have been performed with systems similar to ours to determine techniques for optimal spatial and contrast resolution with the lowest radiation dose [15–17].

The imaging plates used in this study have a resolution of 3.3 lp/mm, slightly less than the conventional film-screen combination. This is offset by the greater latitude and contrast resolution of the computed system.

The diagnostic accuracy of the two methods was compared using receiver operating curve analysis. Hanley and McNeil [12] derived a method of comparing the area under two receiver operating curves derived from the same sample of patients. Our data indicate there is no statistical difference between the diagnostic accuracy of conventional and com-

puted myelography. With improvements in digital imaging and image manipulation, we suspect that digital radiography will offer advantages when looking at abnormalities defined by low-contrast edges [11, 15].

Analysis of the checklist data showed there was a slight observer preference for conventional radiography in evaluating the following parameters: (1) adequacy of spatial resolution, (2) adequacy of contrast resolution, (3) penetration of contrast column, (4) visualization of thecal sac, and (5) visualization of nerve roots and nerve root sleeves. On the other hand, there was no significant preference when CR was compared with FS in the following categories: (1) visualization of bony structures; (2) visualization of the conus medullaris; and (3) visualization of the spinal cord.

We believe that the subjective preference for conventional radiography is primarily due to reader familiarity with and confidence in conventional studies. In addition, the smaller size of the CR images and the slightly decreased spatial resolution may bias the reader toward film-screen images. However, even with all of these factors, the diagnostic accuracy of CR was equal to FS. It remains to be seen whether our clinical colleagues will accept the smaller images that are produced by our system. Technical improvements, such as enlarged images and increased image manipulation made possible by direct viewing from the monitor, may serve to increase the utility, acceptance, and quality of computed myelography.

In conclusion, film-screen and computed radiography have a similar diagnostic accuracy for myelographic evaluation. There is a slight subjective preference for conventional radiography, most likely reflecting reader familiarity with and confidence in this method as well as the larger size of the FS images. Computed radiography has the advantage of frequency-modified images (which were believed to be useful in over 90% of cases), and the advantage of a reduced radiation dosage when compared with conventional studies.

## ACKNOWLEDGMENT

We thank Leslee Bachelier for manuscript preparation.

## REFERENCES

1. Brant-Zawadzki M, Gould R, Norman D, Newton TH, Lane B. Digital subtraction cerebral angiography by intraarterial injection: comparison with conventional angiography. *AJR* 1983;140:347–353

2. Modic MT, Weinstein MA, Starnes DL, Kinney SE, Duchesneau PM. Intravenous digital subtraction angiography of the intracranial veins and dural sinuses. *Radiology* **1983**;146:383-389
3. Seeger JF, Carmody RF. Digital subtraction angiography of the arteries of the head and neck. *Radiol Clin North Am* **1985**;23:193-210
4. Chakraborty DP, Breatnach ES, Yester MV, Soto B, Barnes GT, Fraser RG. Digital and conventional chest imaging: a modified ROC study of observer performance using simulated nodules. *Radiology* **1986**;158:35-39
5. Fraser RG, Breatnach E, Barnes GT. Digital radiography of the chest: clinical experience with a prototype unit. *RadioGraphics* **1985**;5:415-428
6. Goodman LR, Foley WD, Wilson CR, Rimm AA, Lawson TL. Digital and conventional chest images: observer performance with film digital radiography system. *Radiology* **1986**;158:27-33
7. Lams PM, Cocklin ML. Spatial resolution requirements for digital chest radiographs: an ROC study of observer performance in selected cases. *Radiology* **1986**;156:11-19
8. MacMahon H, Vyborny CJ, Metz CE, Doi K, Sbeti V, Solomon SL. Digital radiography of subtle pulmonary abnormalities: an ROC study of the effect of pixel size on observer performance. *Radiology* **1986**;158:21-26
9. Merritt CRB, Tutton RH, Bell KA, et al. Clinical application of digital radiography: computed radiographic imaging. *RadioGraphics* **1985**;5:397-414
10. Huebener KH. Scanned projection radiography of the chest versus standard film radiography: a comparison of 250 cases. *Radiology* **1983**;148:363-368
11. Fajardo LL, Hillman BJ, Hunter TB, Claypool HR, Westerman BR, Mockbee B. Excretory urography using a computed radiography system. *Radiology* **1987**;162:345-352
12. Hanley JA, McNeil BJ. A method of comparing the areas under receiver operating characteristic curves derived from the same cases. *Radiology* **1983**;148:839-843
13. Metz CE. ROC methodology in radiologic imaging. *Invest Radiol* **1986**;21:720-733
14. Barnes PD, Reynold AF, Galloway DC, Pollay M, Leonard JC, Prince JR. Digital myelography of spinal dysraphism in infancy: preliminary results. *AJNR* **1984**;5:208-211, *AJR* **1984**;142:1249-1252
15. Arnold BA, Scheibe PO. Noise analysis of a digital radiography system. *AJR* **1984**;142:609-613
16. Ishida M, Doi K, Loo LN, Metz C, Lehr JL. Digital image processing: effect on detectability of simulated low-contrast radiographic patterns. *Radiology* **1984**;150:569-575
17. Rimkus D, Baily NA. Patient exposure requirements for high contrast resolution in digital radiographic systems. *AJR* **1984**;142:603-608