



## Get Clarity On Generics

Cost-Effective CT & MRI Contrast Agents



FRESENIUS  
KABI

WATCH VIDEO

# AJNR

## Occlusion of arteriovenous malformations of the cavernous sinus via the superior ophthalmic vein.

M M Teng, W Y Guo, C I Huang, C C Wu and T Chang

*AJNR Am J Neuroradiol* 1988, 9 (3) 539-546

<http://www.ajnr.org/content/9/3/539>

This information is current as  
of August 14, 2025.

# Occlusion of Arteriovenous Malformations of the Cavernous Sinus via the Superior Ophthalmic Vein

Michael Mu Huo Teng<sup>1,2</sup>  
 Wan-Yuo Guo<sup>1</sup>  
 Chun-I Huang<sup>3</sup>  
 Chih-Chiau Wu<sup>4</sup>  
 Tsuen Chang<sup>1</sup>

The treatment of five patients with dural arteriovenous malformations (AVMs) of the cavernous sinus via the superior ophthalmic vein (SOV) is reported. The procedure was performed in one patient after surgical dissection of the SOV. In the other four patients the procedure was performed by transcatheter puncture of the SOV under the guidance of real-time digital subtraction angiography. Complete resolution of the ocular symptoms was achieved in all cases. Angiograms after embolization showed complete obliteration of the malformation in four cases and partial obliteration in one.

This method can cure dural AVMs of the cavernous sinus, with preservation of blood flow in the internal carotid artery. It is particularly indicated when the SOV is enlarged and when (1) dural AVMs of the cavernous sinus are fed by small branches of the internal carotid artery or direct carotid cavernous fistulas with small tears; (2) dural AVMs of the cavernous sinus are fed by multiple branches from both the internal and external carotid arteries, one or both sides; or (3) dural AVMs of the cavernous sinus or direct carotid cavernous fistulas recur after trapping of the internal carotid artery.

Transcatheter puncture and catheterization of the SOV was performed safely with the aid of digital subtraction angiography. The SOV approach was able to treat the fistula with preservation of the internal carotid artery.

Carotid cavernous fistulas (CCFs) occur spontaneously or, more often, secondary to trauma [1], and can generally be classified as either direct or indirect. (1) Direct CCFs arise directly from the internal carotid artery (ICA) and may result from trauma, ruptured intracavernous carotid aneurysms, collagen deficiency syndromes, arterial dissection, direct surgical trauma, and fibromuscular dysplasia [2–6]. (2) Indirect CCFs or dural arteriovenous malformations (AVMs) of the cavernous sinus [4–8] acquire blood supply indirectly from dural branches of the ICA or external carotid artery (ECA). Their causes are often unknown, but they may be associated with pregnancy, sinusitis, trauma, surgical procedures, or cavernous sinus thrombosis [6]. CCFs of the dural AVM type are more common than CCFs caused by rupture of an aneurysm [4].

Dural AVMs of the cavernous sinus (indirect CCFs) usually have such eye symptoms as proptosis, diplopia and limitation of eye movement from cranial nerve palsies, decrease in visual acuity, vascular engorgement of the conjunctiva with redness of the eye, chemosis, and retroorbital pain. Some patients may have bruits. Intracranial hemorrhage is rare in dural AVMs of the cavernous sinus [6, 9]. Spontaneous regression in dural AVMs of the cavernous sinus is not uncommon. Five of 11 cases reported by Newton and Hoyt [7] had spontaneous regression. Three of 18 cases of dural AVMs of the cavernous sinus reported by Vinuela et al. [4] had spontaneous regression.

Among 28 cases of indirect CCFs reported by Halbach et al. [6], 3.6% had cortical venous drainage with symptoms of increased intracranial pressure, 25% had decreased visual acuity, and 10.7% had blindness. Patients with cortical venous drainage or an enlarged cavernous sinus varix are at risk to develop intracranial hemorrhage [6]. Therefore, although most indirect CCFs have a relatively benign

Received May 15, 1987; accepted after revision October 8, 1987.

<sup>1</sup> Department of Radiology, Veterans General Hospital, and National Yang Ming Medical College, Taipei, Taiwan, 11217 Republic of China. Address reprint requests to M. M. H. Teng, Section of Neuroradiology, Department of Radiology, Veterans General Hospital, 201, Section 2, Shih-Pai Rd., Taipei, Taiwan, 11217 Republic of China.

<sup>2</sup> Department of Radiology, National Defense Medical Center, Taipei, Taiwan, 11217 Republic of China.

<sup>3</sup> Department of Neurosurgery, Veterans General Hospital, and National Yang Ming Medical College, Taipei, Taiwan, 11217 Republic of China.

<sup>4</sup> Department of Ophthalmology, Veterans General Hospital, and National Yang Ming Medical College, Taipei, Taiwan, 11217 Republic of China.

**AJNR 9:539–546, May/June 1988**

0195–6108/88/0903–0539

© American Society of Neuroradiology

nature, some need emergent treatment to preserve visual function, relieve increased intracranial pressure, or avoid intracranial hemorrhage [6].

Various methods are used to treat CCFs of both the direct and indirect type. Methods of treatment that can preserve the blood flow in the ICA without craniotomy seem less aggressive. These include carotid jugular compression [5, 6]; embolization with detachable balloons in direct CCFs [2, 3, 10–14]; and superselective embolization of the feeders from the ECA with particulate matter such as Silastic spheres or polyvinyl alcohol (PVA)\* or Gelfoam particles [4, 5, 8, 14]. Not every CCF can be treated effectively with these methods. Embolization of the cavernous sinus via the venous route is another method of treatment. Electrothrombosis or embolization of the cavernous sinus has been described without craniotomy through the inferior petrosal sinus (IPS) [15, 16] or through the superior ophthalmic vein (SOV) [17–20]. Electrothrombosis or embolization of the cavernous sinus through the SOV has been described after surgical dissection and exposure of this vein or the angular vein [17–20]. Transcutaneous puncture of the SOV was not recommended and was difficult to perform before the emergence of modern digital subtraction angiography (DSA) [18].

The article describes the treatment of dural AVMs of the cavernous sinus via the SOV. A new approach is described for catheterization of the SOV by transcutaneous puncture under the guidance of a real-time DSA.

## Subjects and Methods

Embolization of the dural AVM of the cavernous sinus (indirect CCF) via the SOV was performed in five patients, four women and one man. In one case embolization was performed after surgical exposure of the SOV; in the other four embolization was performed by transcutaneous puncture of the SOV under DSA road-map guidance. All embolizations but one were performed with general anesthesia; the last was performed under local anesthesia.

Before embolization, every patient had a complete angiographic study to disclose the feeding arteries and draining pathways. We proceed with embolization when there is any urgent indication for treatment, such as the presence of cortical venous drainage or a cavernous sinus varix, rapid progressive proptosis, rapid or severe visual decline, or symptoms of a major hemorrhage [6]. Other conditions are less urgent indications for treatment: an annoying bruit, the need for reestablishing oculomotor function, intense headache or retroorbital pain, and the desire to achieve a good cosmetic result. For less urgent conditions, we usually begin treatment with carotid jugular compression [5].

Indications for treatment in our patients were cortical venous drainage and cosmetic in case 1, recent diminution of visual acuity in case 5, and severe retroorbital pain in cases 2–4. The three patients (cases 2–4) without cortical venous drainage or recent decline in visual acuity were first treated with carotid jugular compression without effect. The malformation was embolized without prior carotid jugular compression in cases 1 and 5.

For dural AVMs fed by branches of ECA only, we embolized the ECA feeders with superselective catheterization. For dural AVMS fed by inaccessible branches of the ICA or ECA, if an approach through

the IPS was possible, we tried that first. If the IPS approach was not possible or complete obliteration of the AVM was not achieved, we then considered the SOV approach. When the posterior half of the SOV was enlarged and not focally narrowed, we considered the SOV approach to be feasible.

Our standard technique of transcutaneous puncture and catheterization of the superior ophthalmic vein under DSA guidance is described below.

1. Perform control DSA in the Caldwell and lateral views via injection of a common carotid artery or the ascending aorta.

2. Scrub the eyes, forehead, and upper face with 5% povidone-iodine aqua.<sup>†</sup>

3. Bring the orbit on the side of the lesion into the area of the fluoroscope in the Caldwell view. Use the road-map function. Under fluoroscopic guidance, inject contrast material into the artery that shows that AVM or fistula; release the switch, and retain the image with the best opacification of the SOV as a mask for later real-time DSA.

4. Switch on the fluoroscope again; only the SOV will be visible with real-time DSA. Use a needle to point to the SOV and determine the site of the skin incision. With the patient's head held still, make a small incision on the upper eyelid after giving the 2% Xylocaine. Puncture the SOV with a 16-gauge needle under fluoroscopic guidance. With real-time DSA only the needle and the SOV are seen if the patient is still.

5. Once the needle tip enters the SOV, blood comes out of the needle spontaneously. Insert a 0.035-in. (0.089 cm) movable-core guidewire through the needle into the cavernous sinus. Release the real-time DSA function and confirm the location of the guidewire tip with the lateral fluoroscope.

6. With the tip of the guidewire in the cavernous sinus and the core of the guidewire in the most anterior position, replace the needle with a catheter about 20 cm long that has a small curve in its tip. The size of the catheter depends on the type of emboli used. Currently we use a 5-French catheter for introduction of steel coils. Smaller-size catheters such as 3 French can be used for smaller coils.

7. Obtain a cavernous sinus venogram to evaluate the size of the cavernous size and its draining vein.

8. Through the catheter in the SOV, implant emboli in the cavernous sinus. The main emboli used are steel spring coils.<sup>‡</sup> The number and size of the steel coils depend on the size of the cavernous sinus. Gelfoam strips (6 × 20 mm in size) and isobutyl-2-cyanoacrylate (IBCA) are added to ensure immediate complete obliteration of the involved cavernous sinus. The Gelfoam strips are injected one by one into the cavernous sinus with diluted contrast media. We flush the catheter with normal saline until each Gelfoam strip enters the cavernous sinus before injection of the next piece.

9. A postembolization angiogram after injection of the contrast material into the common carotid artery or ascending aorta will show if the treatment is complete or not.

## Results

Obliteration of the dural AVM of the cavernous sinus was complete in four cases and partial in one.

Clinical symptoms before embolization were proptosis (five cases), diplopia or sixth cranial nerve palsy (four cases), retroorbital pain (three cases), chemosis (two cases), protruding vascular mass (one case), bruits (one case), and loss of vision (one case). After embolization, all these symptoms

\* Ivalon.

<sup>†</sup> Betadine.

<sup>‡</sup> Cook, Bloomington, IN.

resolved, except the loss of vision in one case and sixth cranial nerve palsy in one case.

All our patients had some subconjunctival hemorrhage, but it gradually cleared within 1 week. In case 2, obvious eyelid hematoma with ptosis subsided without problem within several days. There were no signs or symptoms suggesting intraorbital hematoma posterior to the globe or decreased visual acuity after the SOV approach. There were no new cases of cranial nerve palsy after embolization.

## Case Reports

### Case 1

A 30-year-old woman was admitted because of a progressively protruding mass over the left eyelid for several years and diplopia for 6 months. A CCF of the dural AVM type was diagnosed 7 years before, at which time an extracranial-intracranial (EC-IC) bypass, trapping of the left ICA, and ligation of the trunk of the ECA were performed. On examination, exophthalmos, sixth cranial nerve palsy, and conjunctival congestion were present. The intraocular pressure of the left eye was 22 mm Hg. Angiograms showed a recurrent dural AVM of the cavernous sinus fed by the ECA bilaterally and the

contralateral ICA. Venous drainage through the cortical vein from the sphenoparietal sinus was noted. After dissection of the SOV by an ophthalmologist, embolization was performed with two coils and an IBCA mixture containing 1 ml IBCA, 0.4 ml Pantopaque, and a small amount of tantalum powder. Angiograms after the embolization showed complete obliteration of the malformation (Fig. 1). The patient went home 4 days later with resolution of the exophthalmos, disappearance of the protruding mass, and normal intraocular pressure (17 mm Hg). The sixth cranial nerve palsy was still present 3 months later when she returned for clinical follow-up.

### Case 2

A 59-year-old man had had protrusion of the right eye and conjunctival congestion for 5 months and diplopia, retroorbital pain, and chemosis for 3 months. Examination revealed exophthalmos, sixth cranial nerve palsy, and marked chemosis with eversion of the inferior conjunctiva. Intraocular pressure was 34 mm Hg, and visual acuity was 6/7.5 in the right eye. Angiograms showed a dural AVM of the cavernous sinus fed by the meningohypophyseal trunk of the right ICA, with drainage to the SOV and the IPS. The meningohypophyseal trunk was too small for the passage of a detachable balloon. The IPS was also too small for catheterization. Thus, the SOV approach was the only way to obliterate the malformation with preservation of the

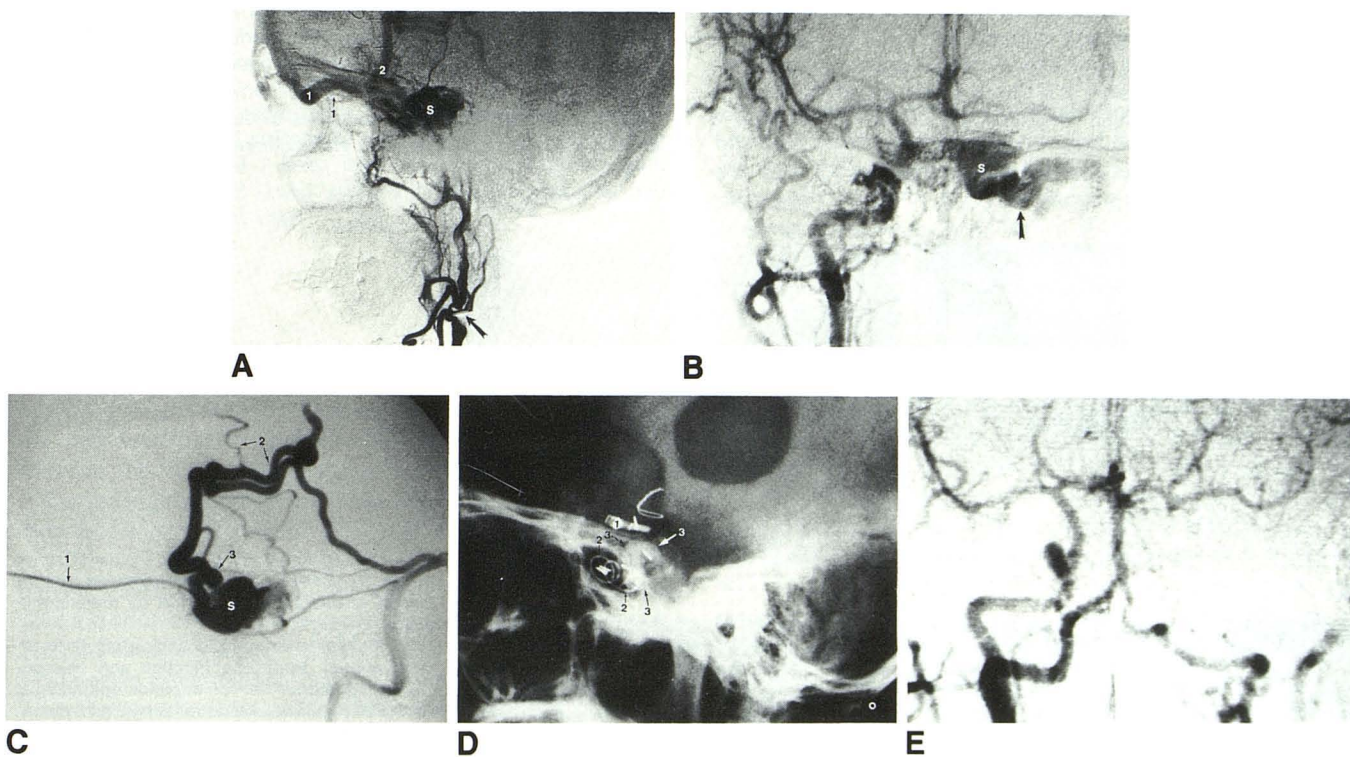


Fig. 1.—Case 1: recurrent dural arteriovenous malformation (AVM) of the cavernous sinus after surgery.

A, Left common carotid angiogram. Internal carotid artery (ICA) is not patent because of previous ligation. Surgical clip applied to main trunk of external carotid artery (ECA) is distal to superior thyroid artery (arrow). Distal ECA was opacified from collateral circulation from superior thyroid artery. There is early opacification of left cavernous sinus (S) with drainage to superior ophthalmic vein (SOV) (1) and filling of cortical vein via sphenoparietal sinus (2).

B, Right common carotid angiogram before embolization (anteroposterior view). Cavernous sinus and SOV (arrow) fill early because of dural AVM.

C, Cavernous sinus venogram after injection of contrast medium into cavernous sinus through catheter (1) in SOV. There is cortical venous drainage (2) from sphenoparietal sinus (3).

D, Plain lateral skull film after embolization. 1 = clip applied on supraclinoid ICA from previous operation; 2 = coils, 3 = isobutyl-2-cyanoacrylate mixture in cavernous sinus.

E, Arterial digital subtraction angiogram after injection of contrast medium into ascending aorta after embolization (anteroposterior view). There is no opacification of cavernous sinus and SOV.

blood flow in the ICA. Surgical dissection of the anterior portion of the SOV or the angular vein was difficult because they were not visible in the angiograms, but the posterior two-thirds of the SOV was dilated. We successfully catheterized the SOV via transcutaneous puncture under DSA guidance and embolized the malformation with two coils and an IBCA mixture containing 0.5 ml IBCA, 0.2 ml Pantopaque, and a small amount of tantalum powder. After embolization, angiograms showed complete obliteration of the malformation (Fig. 2). The patient had marked swelling of the right upper eyelid (eyelid hematoma) for about 3 days after the embolization. He returned home 4 days after the embolization with normal intraocular pressure (14 mm Hg) and a visual acuity of 6/10 in the right eye. All ocular symptoms including the sixth cranial nerve palsy had resolved completely 3 months later.

#### Case 3

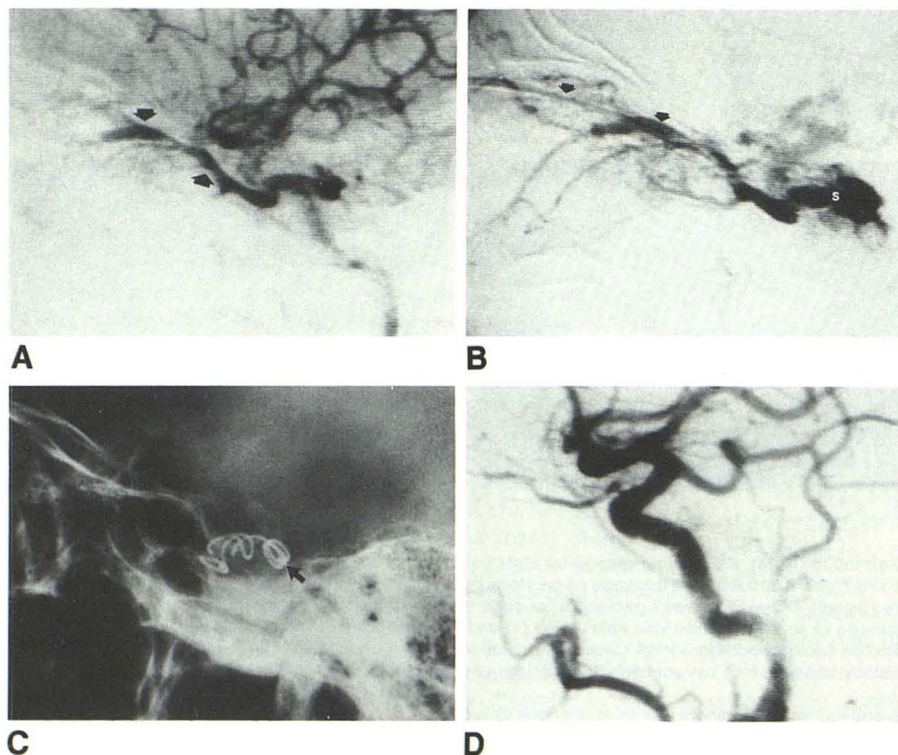
A 63-year-old woman was admitted with a 2-month history of redness, protrusion, retroorbital pain, and chemosis of the left eye. Intraocular pressure was normal. No bruits were heard and there were no cranial nerve palsies. Angiograms showed a dural AVM of the cavernous sinus fed from both the left ECA and ICA. Embolization was performed initially through the ECA with 2 mg of Ivalon particles in sizes of 250–500  $\mu$ m mixed with diluted contrast material and injected under fluoroscopy. Then embolization of the cavernous sinus through the SOV was performed with two coils and five Gelfoam strips. Angiograms after embolization showed partial obliteration of the malformation with residual drainage into the IPS (Fig. 3). The patient was discharged 1 week after the embolization with continuing carotid jugular compression. The clinical ocular symptoms had disappeared completely when she returned for clinical follow-up 3 months later.

#### Case 4

A 45-year-old woman was admitted because of conjunctival congestion, ocular discomfort, retroorbital pain, slight proptosis of the left eye, and noise on the left side of the head. On examination, bruits were heard from the left eye and forehead. The intraocular pressure of the left eye was 30 mm Hg, and a sixth cranial nerve palsy was present. Angiograms showed a dural AVM of the cavernous sinus fed from the left ECA and ICA. Dissection of the SOV by an ophthalmologist failed. Therefore, puncture and catheterization of the SOV by the technique described was used. Three coils and four Gelfoam strips were implanted inside the cavernous sinus. The angiogram demonstrated obliteration of the malformation after the embolization (Fig. 4). The patient was discharged 1 week later with normal intraocular pressure. All ocular symptoms including the sixth cranial nerve palsy had disappeared at follow-up 3 months later.

#### Case 5

A 42-year-old woman had proptosis, eyelid swelling, and conjunctival congestion of the right eye for about 2 months and loss of vision of the right eye for 4 days. Examination revealed sixth cranial nerve palsy. Intraocular pressure was normal. There was no light perception in the right eye. Angiography showed a dural AVM of the cavernous sinus fed by the right ECA, right ICA, and left carotid artery. Catheterization of the cavernous sinus through the IPS by the femoral vein approach was performed without difficulty; however, the tip of the catheter could not reach the anterior inferior compartment of the cavernous sinus. Therefore, embolization was performed through the SOV by putting three coils and five Gelfoam strips into the anterior inferior compartment of the cavernous sinus. Then we implanted a coil and two Gelfoam strips into the posterior superior compartment



**Fig. 2.**—Case 2: dural arteriovenous malformation of cavernous sinus fed by meningohypophyseal trunk.

**A,** Right internal carotid angiogram (late arterial phase). Early opacification and enlargement of posterior half of superior ophthalmic vein (SOV) (arrows). Malformation is fed by meningohypophyseal trunk, which is too small for passage of detachable balloon.

**B,** Cavernous sinus venogram after injection of contrast media in cavernous sinus (S) through catheter in SOV (arrows).

**C,** Plain lateral skull film after embolization. Coils (arrow) have been implanted in cavernous sinus.

**D,** Right common carotid angiogram (lateral view) 1 week after embolization. Fistula is completely obliterated.

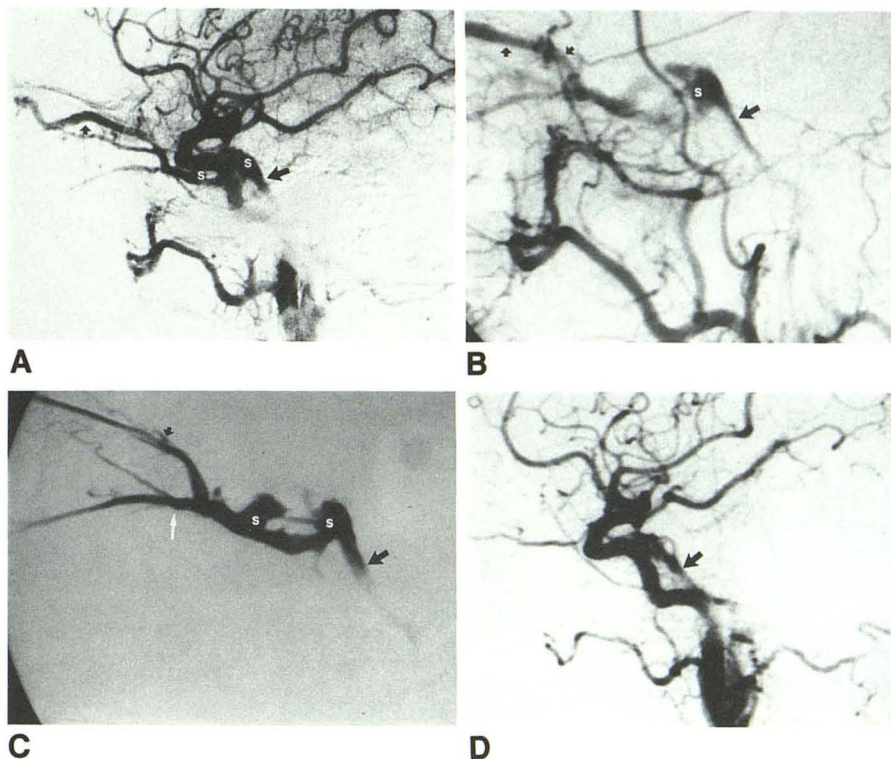
**Fig. 3.**—Case 3: dural arteriovenous malformation of cavernous sinus fed by dural branches of left internal and external carotid arteries.

**A,** Left common carotid angiogram (lateral view). Early opacification of cavernous sinus (S), superior ophthalmic vein (SOV) (short arrow), and inferior petrosal sinus (IPS) (long arrow).

**B,** Left external carotid angiogram (lateral view). Early opacification of cavernous sinus drains into SOV (short arrows) and IPS (long arrow).

**C,** Cavernous sinus venogram with catheter in SOV (short black arrow). Cavernous sinus, IPS (long black arrow), and inferior ophthalmic vein (white arrow) are opacified.

**D,** Left common carotid angiogram after embolization (lateral view). Residual malformation drains into IPS (arrow).



of the cavernous sinus through the catheter in the IPS. The malformation was obliterated completely after embolization (Fig. 5). The patient was discharged 1 week later with resolution of the sixth cranial nerve palsy. All ocular symptoms except vision loss had disappeared by 1 month later.

## Discussion

Treatment of the AVMs of the cavernous sinus in the past has included carotid jugular compression, trapping of the ICA, ligation or selective embolization of the external carotid feeders, and embolization or electrothrombosis of the cavernous sinus via the SOV or IPS at the time of craniotomy.

Carotid jugular compression has been effective in inducing thrombosis in the treatment of 17% of direct CCFs and 30% of indirect CCFs [5, 6]. Compression is best achieved by the patient himself with his contralateral hand, so that the hand will drop spontaneously if any weakness of the hand develops from cerebral ischemia. Carotid jugular compression is not indicated in patients with cortical venous drainage because theoretically this may increase the cerebral venous pressure and cause infarction or rupture of the cerebral vein. The maximal effect of carotid jugular compression is usually achieved within 4–6 weeks [5]. Therefore, this method is not indicated in patients who need a rapid treatment, such as those who have a recent decline in visual acuity. For those patients in whom carotid jugular compression is not indicated or is not effective, further treatment such as surgery or embolization is used.

Ligation of blood vessels at the level of the AVM is very

difficult in dural AVMs of the cavernous sinus. Proximal ligation may be effective temporarily, but the collateral circulation will soon be reinstated and the symptoms of the AVM will reappear [1, 21, 22]. Surgical trapping of the ICA is effective in some cases when dural AVMs of the cavernous sinus are fed by branches of the ICA only. This operation includes a craniotomy to apply a clip in the supraclinoid ICA and a ligation of the ICA at its origin. To occlude possible collateral circulation, embolization is performed with muscle or other emboli in the cavernous portion of the ICA. To avoid arterial insufficiency, EC–IC bypass surgery is usually performed at the same time. Surgical trapping is not only complex, but also somewhat extreme for the relatively mild symptoms and benign course of a dural AVM of the cavernous sinus.

Balloon embolization with preservation of blood flow in the ICA has become the treatment of choice in direct CCFs [2, 3, 10–14]. In dural AVMs fed by branches of the ICA, the opening of the fistula is usually too small for the passage of a detachable balloon. Detachable balloons have been used to trap the ICA and the feeding arteries of the AVM to relieve the severe symptoms of dural AVMs of the cavernous sinus [4]. This procedure is similar to the surgical trapping operation but simpler. Only one step is involved, and a craniotomy is not necessary if the patient can tolerate the test occlusion of the ICA. If the patient cannot tolerate the test occlusion, EC–IC bypass surgery is required before the trapping procedure. Although this balloon trapping procedure is effective only in cases fed from branches of one ICA and is simpler than the surgical trapping procedure, it is still not ideal because it cannot preserve the blood flow in the ICA.

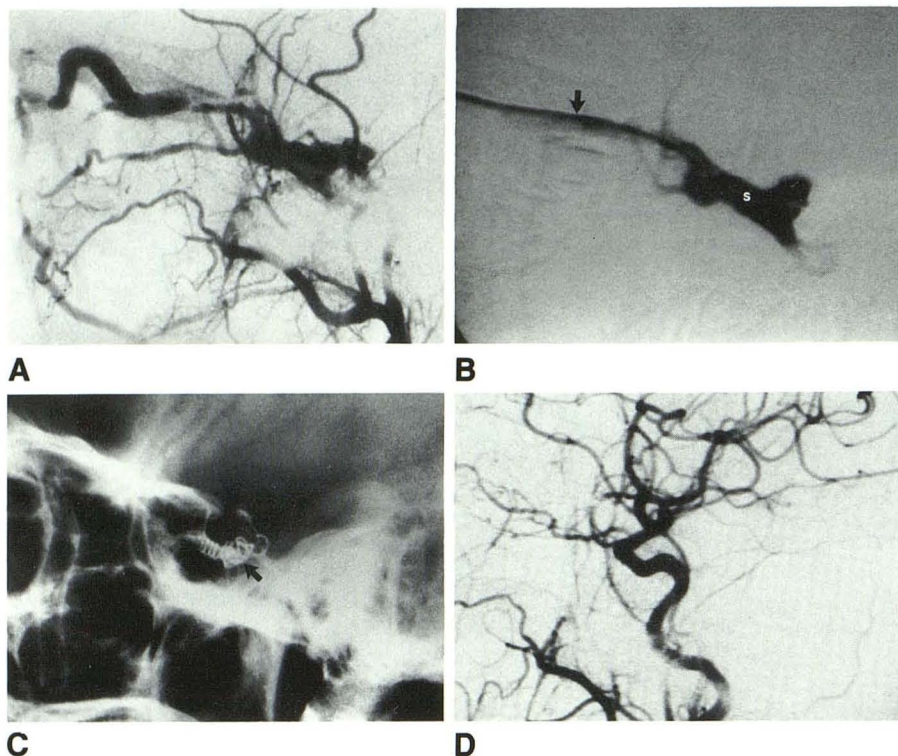


Fig. 4.—Case 4: dural arteriovenous malformation (AVM) of cavernous sinus fed by multiple small dural arteries of left external and internal carotid arteries.

A, Left external carotid angiogram (lateral view). Dural AVM is fed by multiple small dural arteries of external carotid artery.

B, Cavernous sinus venogram through superior ophthalmic vein (arrow). Catheter tip is in cavernous sinus (S).

C, Lateral plain skull film. Coils (arrow) are implanted in cavernous sinus.

D, Common carotid angiogram after embolization. Fistula is obliterated completely.

Embolization of the branches of the ECA has been used for treatment of dural AVMs of the cavernous sinus [4, 5, 8, 14]. It is the treatment of choice in AVMs with no ICA feeders. But sometimes embolization of each feeder one by one is a lengthy and painful procedure, and some patients may not tolerate it [8].

Electrothrombosis or embolization of the cavernous sinus has been described before in the treatment of direct or indirect CCFs after craniotomy [16, 17, 23], through the IPS [15, 16], or through the SOV or angular vein [17–20]. Electrothrombosis is more complex. Not all CCFs can be obliterated with preservation of the ICA by electrothrombosis [16, 17, 23]. Therefore, this technique is not widely used.

The venous approach through the SOV or IPS without craniotomy can obliterate the fistula or malformation with preservation of the blood flow in the ICA. We believe it is the treatment of choice in several situations: (1) if there is a dural AVM of the cavernous sinus fed by small branches of the ICA or a direct CCF with a small opening, in which the conventional treatment is effective but cannot preserve the ICA (as in case 2); (2) if there is a dural AVM of the cavernous sinus with multiple feeders from one or both sides of the ICA and ECA, in which embolization of feeders from the ECA is lengthy and may not be effective (effective treatment includes trapping of one ICA or two, as in cases 3–5); and (3) if there are lesions fed by other inaccessible branches, such as branches of the vertebral artery, or a recurrence of a CCF after a trapping procedure of the ICA (such in case 1).

If the IPS is enlarged, we can embolize the cavernous sinus through the IPS by puncture of the internal jugular or femoral

vein. The cavernous sinus is traversed by the ICA and divided into two compartments: a larger anterior inferior compartment and a smaller posterior superior compartment [16]. These two compartments may not communicate with each other. There is also an angulation between the IPS and the cavernous sinus. Thus, the catheter from the IPS may not be able to reach the opening of the fistula, especially when it is located in the anterior inferior compartment. Therefore, when the IPS is not enlarged or if the catheter in the IPS cannot reach the anterior inferior compartment of the cavernous sinus, we may consider the SOV approach.

The SOV can be catheterized after surgical dissection of the anterior aspect of the SOV or the angular vein, as was reported previously and occurred in our case 1. However, the anterior aspect of the SOV and the angular vein may not be enlarged though the posterior aspect of the SOV may be enlarged (as in case 2). Surgical dissection of the anterior aspect of the SOV or the angular vein may still be difficult even if it is enlarged on the angiogram (as in case 4). Therefore, we developed the technique of transcatheter puncture of the SOV under guidance of real-time DSA without surgical dissection, and used it in cases 2–5.

The possibilities of worsening symptoms after embolization via the SOV include formation of an intraorbital or intracranial hematoma, incomplete embolization, and cavernous sinus thrombosis from mechanical compression of the cranial nerves in the cavernous sinus by metallic coils. Transcatheter puncture and catheterization of the SOV has not been recommended by previous authors because of the risk of hematoma [18]. All our patients had subconjunctival hemor-

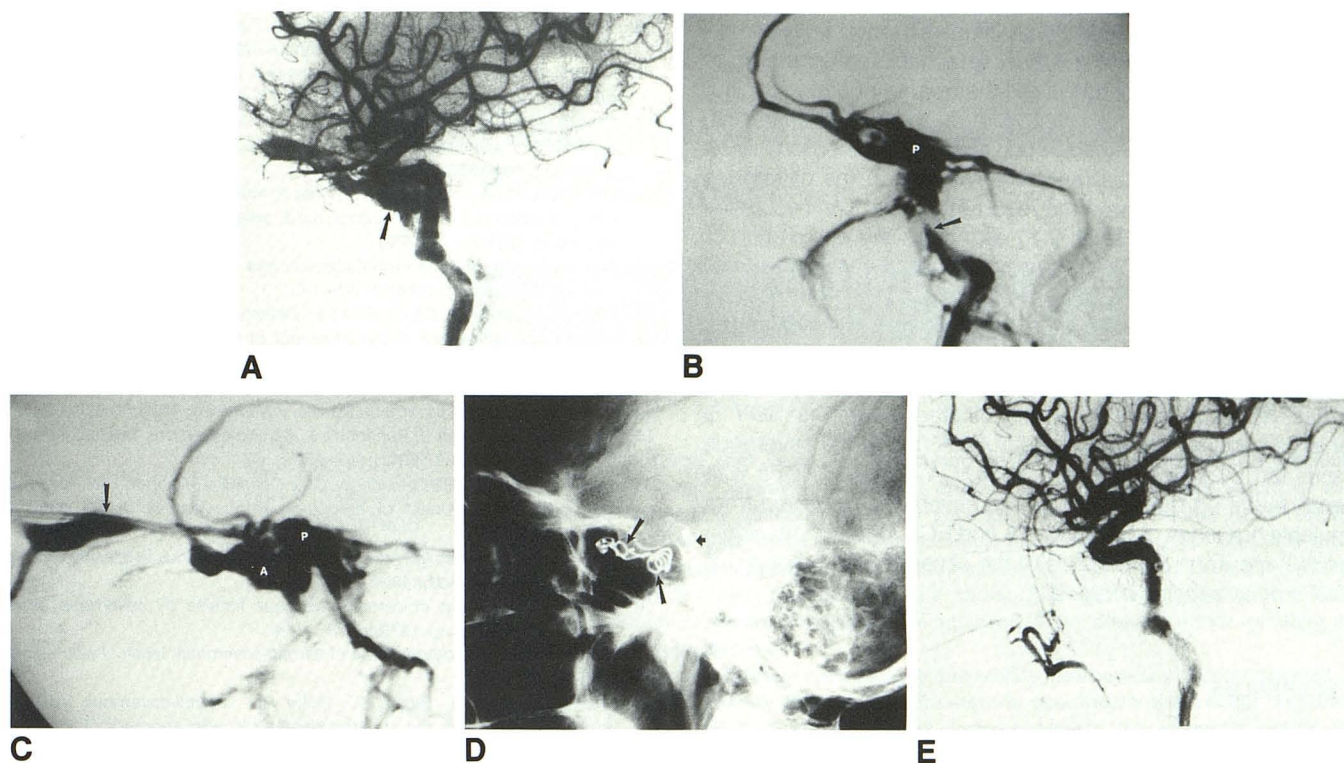


Fig. 5.—Case 5: dural arteriovenous malformation of cavernous sinus fed by dural branches of right internal, right external, and left internal carotid arteries.

A, Right internal carotid angiogram shows early opacification of cavernous sinus (arrow).

B, Cavernous sinus venogram through inferior petrosal sinus (arrow). Posterior superior compartment of cavernous sinus (P) is opacified, but anterior inferior compartment is not.

C, Cavernous sinus venogram through superior ophthalmic vein. Cavernous sinus, including anterior inferior (A) and posterior superior (P) compartments, is opacified.

D, Plain skull film after embolization. Coils are implanted in anterior inferior (long arrows) and posterior superior (short arrow) compartments of cavernous sinus.

E, Right common carotid angiogram after embolization. Fistula is completely obliterated.

rhage, probably because our needle passed the conjunctiva. It gradually cleared within 1 week in all cases. One patient had obvious eyelid hematoma with ptosis (case 2), which subsided without problems within several days. No patient had signs or symptoms suggesting an intraorbital hematoma posterior to the globe. A new CCF with a nonarterialized vein is also considered a contraindication to the SOV approach because of the risk of intraorbital hematoma [18]. This is not important in the treatment of CCFs of the dural AVM type, because the symptoms usually develop slowly and are not obvious for months.

If the embolization is incomplete with remaining venous drainage to the SOV, the pressure of the SOV will remain high and there will be a risk of intraorbital or eyelid hemorrhage. In incomplete embolization with the remaining fistula draining to the brain, there is a risk of intracranial hemorrhage. Therefore, in the treatment of dural AVMs of the cavernous sinus, it is important to use larger emboli in the cavernous sinus to block the communication between the feeding artery and the veins in the brain to reduce the risk of intracranial hemorrhage. In case 3, the embolization of the cavernous sinus was incomplete because we did not advance the cath-

eter and coils to the posterior aspect of the cavernous sinus. The eye symptoms all disappeared because the anterior cavernous sinus was occluded. There was no venous drainage to the brain and no risk of intracranial hemorrhage.

Theoretically, the symptoms of cavernous sinus thrombosis related to involvement of neighboring nerves may occur with compression of these nerves in the cavernous sinus by the implanted emboli. In none of our five cases was there a newly developed cranial palsy after embolization of the cavernous sinus via the SOV. To avoid this, we do not force a large coil into a small cavernous sinus.

Can this technique be applied in the treatment of direct CCFs. In direct CCFs with complete transection of the ICA, implantation of emboli into the cavernous sinus risks sending the emboli into the ICA with distal migration. Therefore, sacrifice of the ICA with or without preliminary EC-IC bypass surgery is the treatment of choice in direct CCFs with complete transection of the ICA. For large CCFs directly from the ICA without history of previous operation, embolization through the SOV with coils did not result in satisfactory occlusion of the fistulas in the two cases reported by Uflacker et al. [18]. Therefore, for a high-flow fistula directly from the

ICA that can be occluded by an inflated balloon with preservation of blood flow in the ICA, a detachable balloon through the ICA and into the fistula is still the treatment of choice. But with a CCF after a trapping procedure, the ICA can easily be compressed and displaced to one side of the cavernous sinus by the implanted coils. Thus, embolization of the cavernous sinus will easily obliterate the recurrent fistula. The two cases reported by Uflacker et al. [18] with complete obliteration of the CCFs by the SOV approach both had recurrent direct CCFs after surgical trapping procedures.

In conclusion, we believe that transcatheter puncture and catheterization of the SOV can be performed safely with the aid of DSA. The SOV approach can treat the fistula with preservation of the ICA. It is indicated when the SOV is enlarged and can be used in (1) dural AVMs of the cavernous sinus fed by small branches of the ICA or direct CCFs with small tears; (2) dural AVMs of the cavernous sinus fed from multiple branches of both the ICA and ECA, one or both sides; and (3) recurrent dural AVMs of the cavernous sinus or direct CCFs after trapping of the ICA.

## REFERENCES

1. Walker E, Allegra GE. Carotid-cavernous fistulas. *Surgery* 1956;39:411-422
2. Yamamoto I, Watabe T, Shinoda M, Hasegawa Y, Sato O. Bilateral spontaneous carotid-cavernous fistulas treated by the detachable balloon technique: case report. *Neurosurgery* 1985;17:469-473
3. Bradac GB, Bender A, Curio G, Debrun G. Report of two cases of spontaneous direct carotid-cavernous fistula. *Neuroradiology* 1985;27:436-439
4. Vinuela F, Fox AJ, Debrun GM, Peerless SJ, Drake CG. Spontaneous carotid-cavernous fistulas: clinical, radiological, and therapeutic considerations. *J Neurosurg* 1984;60:976-984
5. Halbach VV, Higashida RT, Hieshima GB, Reicher M, Norman D, Newton TH. Dural fistulas involving the cavernous sinus: results of treatment in 30 patients. *Radiology* 1987;163:437-442
6. Halbach VV, Hieshima GB, Higashida RT, Reicher M. Carotid cavernous fistulae: indications for urgent treatment. *AJNR* 1987;8:627-633
7. Newton TH, Hoyt WF. Dural arteriovenous shunts in the region of the cavernous sinus. *Neuroradiology* 1970;1:71-81
8. Grossman RI, Sergott RC, Goldberg HI, et al. Dural malformations with ophthalmic manifestations: results of particulate embolization in seven patients. *AJNR* 1985;6:809-813
9. Lasjaunias P, Chiu M, Brugge KT, Tolia A, Hurth M, Bernstein M. Neurological manifestations of intracranial dural arteriovenous malformations. *J Neurosurg* 1986;64:724-730
10. Serbinenko FA. Balloon catheterization and occlusion of major cerebral vessels. *J Neurosurg* 1974;41:125-145
11. Debrun G, Lacour P, Caron JP, et al. Detachable balloon and calibrated-leak balloon techniques in the treatment of cerebral vascular lesions. *J Neurosurg* 1978;49:635-649
12. Debrun G, Lacour P, Vinuela F, Fox A, Drake CG, Caron JP. Treatment of 54 traumatic carotid cavernous fistulas. *J Neurosurg* 1981;55:678-692
13. Berenstein A, Kricheff II, Ransohoff J. Carotid-cavernous fistulas: intraarterial treatment. *AJNR* 1980;1:449-457
14. Tsai FY, Hieshima GB, Mehringer CM, Grinnell V, Pribam HW. Delayed effects in the treatment of carotid-cavernous fistulas. *AJNR* 1983;4:357-361
15. Manelfe C, Berenstein A. Treatment of carotid cavernous fistulas by venous approach. *J Neuroradiol* 1980;7:13-19
16. Mullan S. Treatment of carotid-cavernous fistulas by cavernous sinus occlusion. *J Neurosurg* 1979;50:131-144
17. Hosobuchi Y. Electrothrombosis of carotid-cavernous fistula. *J Neurosurg* 1975;42:76-85
18. Uflacker R, Lima S, Ribas GC, Piske RL. Carotid-cavernous fistulas: embolization through the superior ophthalmic vein approach. *Radiology* 1986;159:175-179
19. Tress BM, Thomson KR, Klug GL, Mee RRB, Crawford B. Management of carotid-cavernous fistulas by surgery combined with interventional radiology. Report of two cases. *J Neurosurg* 1983;59:1076-1081
20. Courtheoux P, Labbe D, Hamel C, Lecoq PJ, Jahara M, Theron J. Treatment of bilateral spontaneous dural carotid-cavernous fistulas by coils and sclerotherapy, case report. *J Neurosurg* 1987;66:468-470
21. Hamby WB, Dohn DF. Carotid-cavernous fistulas: report of thirty six cases and discussion of their management. *Clin Neurosurg* 1965;11:150-170
22. Hamby WB. Carotid-cavernous fistula: report of 32 surgically treated cases and suggestions for definitive operation. *J Neurosurg* 1964;21:859-866
23. Mullan S. Experiences with surgical thrombosis of intracranial berry aneurysms and carotid cavernous fistulas. *J Neurosurg* 1974;41:657-670