



Get Clarity On Generics

Cost-Effective CT & MRI Contrast Agents



FRESENIUS
KABI

WATCH VIDEO

AJNR

Platinum wire: a new transvascular embolic agent.

P J Yang, V V Halbach, R T Higashida and G B Hieshima

AJNR Am J Neuroradiol 1988, 9 (3) 547-550

<http://www.ajnr.org/content/9/3/547>

This information is current as
of August 18, 2025.

Platinum Wire: A New Transvascular Embolic Agent

Peter J. Yang^{1,2}
 Van V. Halbach¹
 Randall T. Higashida¹
 Grant B. Hieshima¹

Standard Gianturco and "mini" coils cannot be used with some of the present microcatheter systems. However, occasions arise in which metallic coils would be an ideal embolic agent in a vascular structure accessible only to a tracker (2.2-French) catheter system. We performed nine embolization procedures in eight patients with arteriovenous fistulas using platinum coils as an embolic agent. Fistulas were completely occluded in six of the nine cases. In several cases, platinum wire embolization was augmented with other agents. Complications occurred in two cases, neither resulting in permanent neurologic deficits.

Advantages of using platinum coils include availability, radioopacity, thrombogenicity, biocompatibility, and delivery through microcatheters, specifically the tracker catheter system.

Superselective catheterization has been facilitated by the development of new microcatheter systems. In particular, the 2.2-French tracker catheter* has proved extremely useful in reaching difficult areas during therapeutic embolization procedures. However, the variety of embolic agents that can be used with this catheter is limited because of its small caliber.

Metallic coil devices have been used for transvascular embolization for years [1–6]. Unfortunately, the tracker catheter is not large enough to accept any of the presently available metal coils.

We have encountered a number of cases in which a metallic coil would be useful as an embolic agent, but the area being embolized was only accessible to catheterization with a tracker system. In all these arteriovenous fistulas (AVFs) we attempted to occlude the fistula by thrombosing the draining sinus or vein, a technique described by Mullan [7]. Small pieces of platinum wire proved useful in these instances. Platinum wire obtained from the tips of guidewires is readily available, very thrombogenic, and can be easily deposited through the tracker catheter system.

Materials and Methods

The platinum wires were obtained from the distal tips of 0.014-in.[†] and 0.013-in.[‡] steerable guidewires. The tips were cut to lengths of 0.5–1.5 cm with sharp scissors, resterilized, and shaped into a curved or coiled configuration using the same techniques used to form a curve on the tip of a guidewire. The guidewire tip was placed in the desired location by loading the wire into a needle introducer and pushing it through the tracker catheter with a second guidewire (Fig. 1). Multiple platinum wire pieces were placed into the vascular structure, until the desired amount of occlusion was effected.

A total of nine embolization procedures were performed on eight patients with AVFs (one patient with bilateral carotid-cavernous fistulas [CCF] had two separate procedures). Five patients had dural AVFs and three patients had posttraumatic, direct CCFs.

In all cases, the platinum wires were placed into the cavernous sinus, a venous sinus, or a draining vein involved with the fistula. The objective was to either completely occlude the

Received July 28, 1987; accepted after revision October 27, 1987.

¹ Department of Radiology, Division of Diagnostic and Interventional Neuroradiology, UCSF, San Francisco, CA 94143.

² Present address: Magnetic Resonance Imaging, Department of Radiology, University Medical Center, Tucson, AZ 85724. Address reprint requests to P. J. Yang.

AJNR 9:547–550, May/June 1988

0195–6108/88/0903–0547

© American Society of Neuroradiology

* Target Therapeutics.

† Advanced Cardiovascular Systems.

‡ Target Therapeutics.

abnormal vascular communication or slow blood flow enough to allow use of other embolic material. In four cases, the wires were used alone. In four other patients embolization was augmented with isobutyl-2-cyanoacrylate (IBCA) [3], and Gianturco "mini" coils [1]. Silicone balloons were used in one case in which an internal carotid artery occlusion had to be performed.

Results

The results in our eight patients are summarized in Table 1. In six of the nine cases, there was complete closure of the fistula. Of these cases, two had additional embolization with IBCA and one with "mini" coils. In the two cases with IBCA, the fistulas were so large that platinum wire embolization alone was insufficient. However, it was thought that emboli-

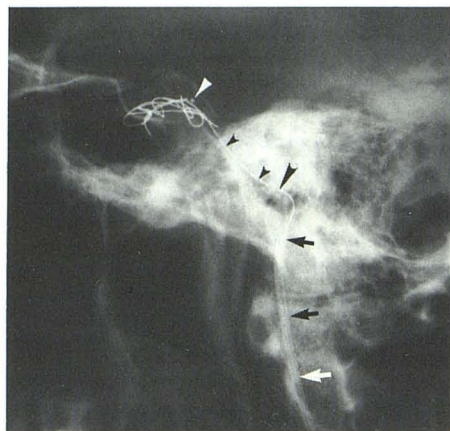


Fig. 1.—Placement of platinum coils into cavernous sinus via inferior petrosal sinus. Lateral film shows tracker catheter traversing 7-French catheter in internal jugular vein (arrows) and tracker tip in cavernous sinus (white arrowhead). Multiple platinum coils are already in cavernous sinus. Another platinum wire (small black arrowheads) is in distal tracker and is being pushed by guidewire (large black arrowhead at tip).

zation with liquid adhesives alone was dangerous without first decreasing blood flow through the fistula using the platinum wire.

In two cases, blood flow through the fistula was diminished without complete closure. In one patient, the goal of therapy was to arrest a progressive seventh-nerve palsy associated with erosion of the temporal bone by an extremely large dural AVF (patient 1). After embolization of a selected portion of the fistula, there was improvement in seventh-nerve function. In the other case (patient 4), a left-sided, direct CCF was embolized with platinum wires after balloons failed to completely close the fistula. Postembolization angiography demonstrated markedly decreased flow through the CCF. Because the clinical symptoms resolved, a follow-up angiogram was not obtained.

There were two complications associated with platinum wire insertion. In one case with a CCF (patient 5), placement of platinum wires using a transarterial approach resulted in extrusion of part of a wire through the cavernous sinus into the lumen of the internal carotid artery. Attempts to angioplasty the wire into the sinus with a balloon were unsuccessful and the patient underwent balloon occlusion of the internal carotid artery without complications.

In a patient with a cavernous sinus dural AVF (patient 8), progressive proptosis, pain, and acute blindness occurred during the embolization procedure because of redirection of blood flow toward the thrombosing superior ophthalmic vein. With decreased flow through the AVF resulting from platinum coil embolization, IBCA was injected into the cavernous sinus with obliteration of the fistula. The proptosis resolved with full recovery of vision within 20 min.

Representative Case Reports

Case 1 (Patient 3)

A 62-year-old man presented with bilateral sixth-nerve palsies, left eye chemosis, and bruit of 3 months' duration. Angiography revealed a dural AVF involving the left inferior petrosal sinus with arterial supply from both external carotid arteries, and dural branches arising

TABLE 1: Platinum Wire Embolizations

Patient No.	Diagnosis	Catheter Route for Platinum Wire	Other Embolic/Delivery Agent/Route	Results
1	Right transverse sinus dural AVF	Transvenous	IBCA/arterial and venous	Diminished flow
2	Left cavernous sinus dural AVF	Transvenous	IBCA/venous	Closed
3	Left inferior petrosal sinus dural AVF	Transvenous	—	Closed
4	Left CCF	Transvenous	—	Diminished flow
5	Left CCF	Transarterial	Balloons/arterial	Carotid occlusion
6	Right CCF	Transvenous	"Mini" coils/venous	Closed
7	Left CCF	Transarterial	—	Closed
7	Left cavernous sinus dural AVF	Transvenous	—	Closed
8	Left cavernous sinus dural AVF	Transvenous	IBCA/venous	Closed

Note.—AVF = arteriovenous fistula; IBCA = isobutyl-2-cyanoacrylate; CCF = direct carotid cavernous fistula.

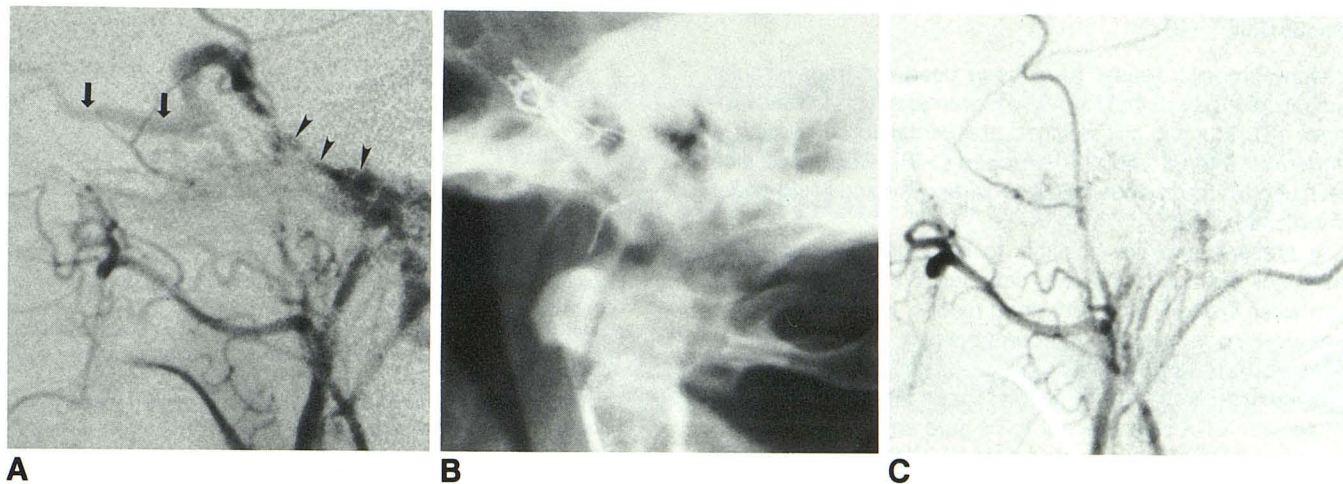


Fig. 2.—**A**, Left external carotid artery injection, lateral view. Multiple small branches from the external carotid artery fill a dural AVF, which drains into inferior petrosal sinus (*arrowheads*). Note venous drainage into cavernous sinus and superior ophthalmic vein (*arrows*).

B, Postembolization lateral film shows platinum wires in inferior petrosal sinus.

C, Left external carotid artery injection, lateral view. Postembolization angiogram reveals almost complete obliteration of AVF. Minimal residual contrast stain is seen near jugular bulb. Injections of internal carotid arteries and right external carotid artery showed no filling of AVF.

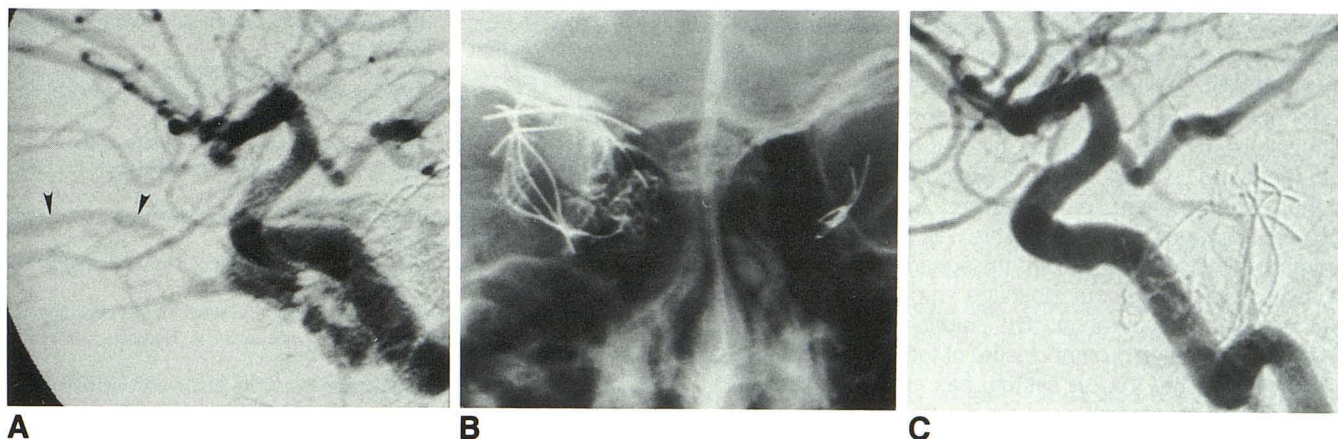


Fig. 3.—**A**, Left internal carotid artery, lateral view. A direct carotid cavernous fistula has venous drainage into mildly enlarged superior ophthalmic vein (*arrowheads*).

B, Postembolization anteroposterior study shows platinum wires in left cavernous sinus. Platinum wires and Gianturco "mini" coils are seen in right cavernous sinus region from prior embolization of right carotid cavernous fistula.

C, Left internal carotid artery injection, lateral view. Postembolization angiogram reveals complete obliteration of carotid cavernous fistula.

from the cavernous portion of the left internal carotid artery (Fig. 2A). The predominate venous drainage was into the left cavernous sinuses and an enlarged superior ophthalmic vein.

Ten platinum wires were placed into the left inferior petrosal sinus using a transvenous approach (Fig. 2B). Postembolization angiography revealed virtually complete obliteration of the fistula (Fig. 2C). The patient's bruit and chemosis resolved and there is significant improvement in sixth-nerve function 2 months after the procedure.

Case 2 (Patient 6)

A 20-year-old woman who was involved in a motor vehicle accident presented with right proptosis and a bruit. Angiography disclosed a

right carotid-cavernous fistula. Balloon embolization was unsuccessful because of the small size of the arterial tear; thus, a transvenous approach was used to close the fistula using platinum wires and Gianturco "mini" coils. The platinum wires were used to occlude the cortical venous drainage of the fistula, which was only accessible via a tracker catheter. A 3-French Teflon catheter was used to place Gianturco "mini" coils in the remainder of the cavernous sinus, with successful occlusion of the fistula. Because of persistent bruit, a second CCF was discovered on the left side (Fig. 3A). Again, balloon embolization was unsuccessful. A transvenous approach was also attempted without success. Finally, a tracker catheter was used to place platinum wire into the left cavernous sinus through the fistula via the internal carotid artery (Fig. 3B). Postembolization angiography disclosed complete occlusion of the CCF (Fig. 3C).

Discussion

Many embolic agents have been used for transvascular embolization, each having their advantages and disadvantages [8]. Metallic coil devices are useful for occluding a moderate to large vascular structure [1-6]. Coils have also been used in the past as an aid to particulate and liquid-agent embolization [9].

At present, it is not possible to introduce a standard or "mini" coil through the tracker catheter. We have used platinum wires instead, with very good results. In all cases, there was a decrease in the flow through the AVF and in four cases there was virtually complete occlusion without the help of other embolic agents. In three cases, complete closure of the fistula with IBCA was thought to be safe only after the blood flow through the fistula was decreased using platinum wires.

Platinum wires were used because of their thrombogenicity, radiopacity, availability, and biocompatibility [10-12]. Thrombogenicity of metal can be enhanced by using an electrical current [13, 14], by combining the wire with fabric strands [15], or by "packing" multiple wires into the vascular structure [16]. Using the tracker system, the last option is the most feasible.

We encountered two complications as a result of this technique. In the first patient, extrusion of a small piece of wire represented a potential nidus for thrombus formation. Thus, balloon occlusion of the internal carotid artery was performed. Extrusion of wire is also a problem that may occur with coil insertion [17]. In fact, most of the technical pitfalls with Gianturco coils also apply to platinum wire embolization. In the second patient, proptosis and temporary blindness occurred during the procedure. This was probably caused by redirection of blood flow toward the superior ophthalmic vein, as other routes of venous drainage were being blocked by platinum wire embolization. The sudden, dramatic clinical change necessitated prompt closure of the fistula using IBCA.

In summary, the tracker system has enhanced our ability to catheterize areas that were previously inaccessible. Platinum guidewire tips can be used with this catheter system in a manner similar to metal coil devices. We have found this embolic agent particularly useful in occluding the cavernous sinus or a venous sinus when treating arteriovenous fistulas.

ACKNOWLEDGMENT

We thank Leslee Bachelier for manuscript preparation.

REFERENCES

1. Gianturco C, Anderson JH, Wallace S. Mechanical devices for arterial occlusion. *AJR* 1975;124:428-435
2. Anderson JH, Wallace S, Gianturco C, Gerson LP. "Mini" Gianturco stainless steel coils for transcatheter vascular occlusion. *Radiology* 1979;132:301-303
3. Chuang VP, Wallace S, Gianturco C. A new improved coil for tapered-tip catheter for arterial occlusion. *Radiology* 1980;135:507-509
4. Lund G, Rysary J, Kotula F, Castaneda-Zuniga WR, Amplatz K. Detachable steel spring coils for vessel occlusion. *Radiology* 1985;155:530
5. Butto F, Hunter DW, Castaneda-Zuniga WR, Amplatz K. Coil-in-coil techniques for vascular embolization. *Radiology* 1986;554-555
6. Braun IF, Hoffman JC Jr, Casarella WJ, Davis PC. Use of coils for transcatheter carotid occlusion. *AJNR* 1985;6:953-956
7. Mullan S. Treatment of carotid-cavernous fistulas by cavernous sinus occlusion. *J Neurosurg* 1979;50:131-144
8. White RI, Strandberg JV, Gross GS, Barth KH. Therapeutic embolization with long-term occluding agents and their effects on embolized tissues. *Radiology* 1977;125:677-687
9. Tomsick TA, Ball JB. Balloons and coils: aids in particulate/liquid head-neck embolization. *AJNR* 1985;6:598-601
10. Compte P. Metallurgical observations of biomaterials. In: Boretos JW, Eden M, eds. *Contemporary biomaterials*. New Jersey: Noyes Publications, 1984:66-91
11. Loeb GE, McHardy J, Kelliher EM, Brummer SB. Neural prosthesis. In: Williams DF, ed. *Biocompatibility in clinical practice*. Boca Raton, FL: CRC Press, 1982:123-150
12. Cooper R, Crow JH. Toxic effects of intra-cerebral electrodes. *Med Biol Eng Comput* 1966;4:575-581
13. Hosobuchi Y. Electrothrombosis of carotid-cavernous fistula. *J Neurosurg* 1975;42:76-85
14. Mullan S, Beckman F, Vailati G, Karasick J, Dobben G. An experimental approach to the problem of cerebral aneurysm. *J. Neurosurg* 1964;21:838-845
15. Barth KH, Strandberg JD, Kaufman SL, White RI. Chronic vascular reactions to steel coil occlusion devices. *AJR* 1978;131:455-458
16. Anderson JH, Wallace S, Gianturco C. Transcatheter intravascular coil occlusions of experimental arteriovenous fistulas. *AJR* 1977;129:795-798
17. Mazur MJ, Baltaxe HA, Wolf GL. Therapeutic embolization of the renal artery with Gianturco coils: limitations and technical pitfalls. *Radiology* 1981;138:37-46