



## Get Clarity On Generics

Cost-Effective CT & MRI Contrast Agents



FRESENIUS  
KABI

WATCH VIDEO

# AJNR

## **Risk of seizures after myelography: comparison of iohexol and metrizamide.**

P Maly, T Bach-Gansmo and D Elmqvist

*AJNR Am J Neuroradiol* 1988, 9 (5) 879-883

<http://www.ajnr.org/content/9/5/879>

This information is current as  
of August 13, 2025.

# Risk of Seizures After Myelography: Comparison of Iohexol and Metrizamide

Pavel Maly<sup>1</sup>  
Tore Bach-Gansmo<sup>2</sup>  
Dan Elmqvist<sup>3</sup>

A parallel, double-blind, randomized study comparing iohexol and metrizamide—both 180 mg I/ml—in lumbar myelography was carried out in 60 consecutive patients. Eight to 15 ml of contrast medium were administered with the upper level at the middle thoracic column. A detailed neurologic examination was performed before and 24 hr after myelography. EEG recordings—evaluated visually and with fast Fourier transformation analysis—and somatosensory evoked responses were registered before, 6 hr after, and 24 hr after myelography. All patients were observed for adverse reactions for 24–48 hr. Iohexol did not produce any epileptiform activity but epileptiform activity was detected in five patients receiving metrizamide. Iohexol produced significantly less frequent and less severe EEG changes than did metrizamide both at visual evaluation ( $p < .0025$ ) and at fast Fourier transformation analysis ( $p < .04$ ). No significant changes occurred in the early components of the somatosensory evoked potentials after either contrast medium.

Iohexol caused significantly ( $p < .002$ ) less frequent and less severe adverse reactions than did metrizamide. The neurologic examination revealed no changes of clinical importance with either contrast agent.

Adverse reactions after subarachnoid injection of metrizamide in humans have been reported extensively during the last decade. The most serious reactions include signs of CNS excitation, seizures in particular. The low epileptogenic effect of metrizamide in humans predicted from animal experiments [1] has been confirmed during the widespread clinical use of this substance. Animal experiments have demonstrated a significantly lower epileptogenic effect of subarachnoid injection of nonionic contrast media developed after metrizamide, such as iogluclide [2, 3], iotrol [3], and iopamidol [2–7]. A low epileptogenic effect of iopamidol has been found in humans [8–11].

To date, several animal experiments [2, 4, 6, 7, 12, 13] have failed to demonstrate any excitative effect on the CNS after subarachnoid injection of iohexol even after lowering of the seizure threshold with chlorpromazine [13]. In the first four “open clinical studies” utilizing EEG in lumbar myelography with iohexol no spike activity was detected, but seven of 145 patients displayed slow-wave activity [14–17].

The aim of the present investigation was to find out if the epileptogenic effect of iohexol used in lumbar myelography is as small and rare as the previous animal experiments predicted. Therefore, we investigated a small number of patients (60) under rigorously standardized conditions—including EEG, evaluated both by an experienced electroencephalographer and by fast Fourier transformation (FFT) analysis, and somatosensory evoked potentials. The patients were also questioned for subjective complaints. Metrizamide served as the reference substance for checking the sensitivity of the chosen methods.

## Materials and Methods

This parallel, double-blind, randomized study included 60 hospitalized adult patients successively referred to the X-ray department for lumbar myelography. They had all given

Received September 11, 1987; accepted after revision February 18, 1988.

<sup>1</sup> Department of Diagnostic Radiology, Malmö General Hospital, 214 01 Malmö, Sweden. Address reprint requests to P. Maly.

<sup>2</sup> Nycomed AS, Postbox 4220 Torshov, N-0404 Oslo 4, Norway.

<sup>3</sup> Department of Neurophysiology, University Hospital, S-221 85 Lund, Sweden.

AJNR 9:879–883, September/October 1988  
0195–6108/88/0905–0879  
© American Society of Neuroradiology



informed consent. Emergency cases were not included. After entrance, no patient was excluded. Their age and gender distribution is given in Table 1. The clinical diagnoses were sciatica, low back pain, or lumbar spinal stenosis. Six of the patients examined with metrizamide and four examined with iohexol had a history of previous hypersensitivity reaction (to penicillin, nitrofurantoin, adrenaline, nickel, and pollen).

Twenty-three of the patients in the iohexol group and 15 in the metrizamide group continued to take what medication they had before the myelography, such as analgesics, benzodiazepines, diuretics, cardiac glycosides, and antiinflammatory agents; but no medications known to lower the seizure threshold—such as phenothiazine derivatives, tricyclic antidepressants, MAO inhibitors, CNS stimulants, or certain antimicrobial agents—were allowed. Fluid intake was permitted until the morning of myelography. No premedication for the myelography was given. A 22-gauge needle was used to withdraw 4–6 ml (median, 4 ml) of CSF. The type of myelographic contrast medium was chosen according to a predetermined, randomized list. Fifteen milliliters of iohexol or metrizamide, both with a concentration of 180 mg I/ml, were administered under fluoroscopic observation to all but one patient. This patient, with severe spinal stenosis cranially to the site of the puncture, received only 8 ml of metrizamide because of increasing pain during the injection. The upper level of contrast medium was recorded (Fig. 1). During and after myelography, active movements by the patients were restricted to a minimum. The patients were kept in bed for the next 24 hr with the cranial end of the bed elevated 10–15° for the first 6–8 hr.

TABLE 1: Gender and Age Distribution

Contrast Medium	Gender		Age	
	Men	Women	Median	(Range)
Iohexol ( <i>n</i> = 30)	16	14	52	(29–70)
Metrizamide ( <i>n</i> = 30)	14	16	46	(22–64)
Total ( <i>n</i> = 60)	30	30	48	(22–70)

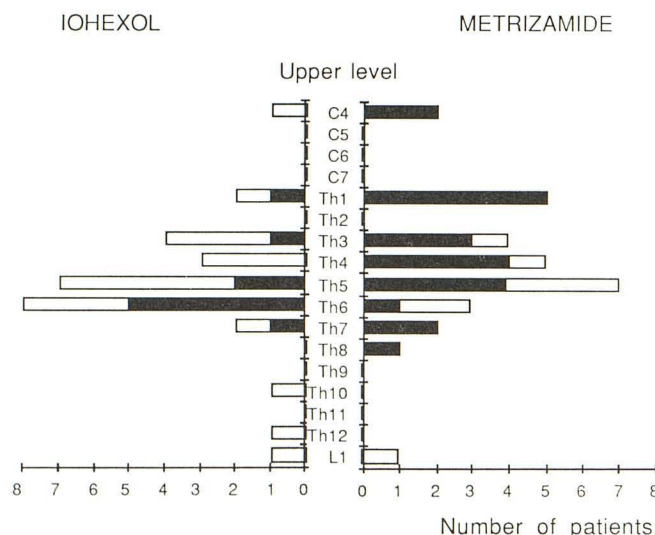


Fig. 1.—Upper level of contrast medium as seen on films. Black columns represent patients with adverse reactions and/or EEG changes.

A detailed neurologic examination was performed within 48 hr before myelography and repeated at 6 and 24 hr after myelography.

Before myelography and 6 and 24 hr after myelography the following electrophysiological recordings were made: (1) standard 16-channel EEG with hyperventilation and photic stimulation; (2) tape recording of four of these EEG channels (F3–C3, P3–O1, F4–C4, P4–O2) for off-line frequency (FFT) analysis; and (3) somatosensory evoked response with stimulation of one median nerve and recording over the contralateral somatosensory area (C3 or C4 with FZ as reference). The EEG was recorded on tape together with trigger impulse for off-line analysis.

When obvious changes in the EEG pattern were observed, further recordings were made at 24-hr intervals whenever this was possible until the EEG pattern was back to the baseline recorded before myelography.

The FFT and evoked potential analysis were performed on a PDP 11/23 computer using the BRAINLAB program (DEC). On visual interpretation of the EEGs the background activity was scored as unchanged, slight slowing, or moderate-severe slowing. The occurrence of paroxysmal-epileptiform activity was noted. Slowing that could be accounted for by drowsiness was not considered abnormal.

The patients were observed for any sign of adverse reactions during the examination and for 24–48 hr afterward. Patients displaying any adverse reaction were observed until the reaction disappeared. The subjective reactions were graded as mild (1), moderate (2), or severe (3). Radiographic quality was evaluated and graded as poor, good, or excellent.

The investigators performing the individual moments in this study were the same for all patients and were blinded to the type of contrast medium used in individual patients until all data had been analyzed and scored.

A two-sided binomial test was used to decide whether differences between the two media were statistically significant at the 5% level. For continuously variable parameters, the median, the interquartile range, and the range were used as indexes of location and dispersion.

## Results

### Visually Scored EEG

The visually scored EEG was completely unchanged in 27 (90%) of the patients in the iohexol group and in 15 (50%) of the patients in the metrizamide group.

Slight slowing of background activity occurred in three (10%) of the patients in the iohexol group and in nine (30%) of the patients in the metrizamide group. None of the patients receiving iohexol displayed moderate or severe slowing of the background activity whereas six (20%) of the patients receiving metrizamide had such changes.

Paroxysmal-epileptiform activity was not detected in any patient in the iohexol group whereas in the metrizamide group, one patient with slight slowing and four patients with severe slowing of the background activity (together, 17% of patients) also displayed paroxysmal-epileptiform activity (irregular spikes and sharp slow waves), most often bilateral.

The difference in the frequency of the occurrence of EEG abnormalities between the iohexol and metrizamide groups was significant ( $p < .0025$ ). EEG changes when present were generally more pronounced at 24 hr than at 6 hr.



### *FFT Analysis of EEG*

FFT analysis showed that the peak frequency in the alpha (8–13 Hz) band was reduced, with 0.38 Hz at 6 hr and 0.56 Hz at 24 hr in the iohexol group and 0.56 Hz at 6 hr and 1.18 Hz at 24 hr in the metrizamide group. The difference was only significant at 24 hr ( $p < .04$ ). There were no consistent differences in the other parameters of the FFT analysis (absolute power and relative power in the alpha, theta, or delta band).

### *Somatosensory Evoked Potentials*

In the analysis of the somatosensory evoked responses only the early components P1, N1, P2, P3, and N2 were measured. There were no significant changes of latencies or amplitudes, either before or after myelography or between the iohexol and metrizamide groups.

### *Clinical Follow-up*

Iohexol did not cause any adverse reactions in 20 (67%) of the patients, whereas in the metrizamide group only eight (27%) of the patients had no adverse reactions.

In the equally large groups of patients investigated with iohexol or metrizamide—30 patients in each group—the number of patients that experienced some adverse reaction is as follows (metrizamide group within parentheses): headache, seven (17); nausea, three (13); vomiting, none (three); pain, three (seven); vertigo, one (four); mental reaction, zero (five); other, four (five).

No manifest seizures were observed in either group. No muscular twitching occurred in the iohexol group, but two patients in the metrizamide group displayed mild muscular twitching in their legs.

Ten (33%) of the patients in the iohexol group experienced 19 episodes of subjective discomfort whereas 22 (73%) of the patients in the metrizamide group experienced 55 episodes of subjective discomfort. The difference in frequency of patients with adverse reactions was statistically significant ( $p < .002$ ).

The adverse reactions were classified as severe in four patients (13%) in the iohexol group. Three patients had severe headache, and the fourth severe sciatica. In the metrizamide group, seven patients (23%) had severe adverse reactions such as headache, nausea, vomiting, increased sciatica, and mental reactions, and four of these patients experienced more than one reaction classified as severe.

The adverse reactions appeared about 9 hr after the myelography (median value, range, 3–72 hr) and there was no difference between the two contrast media concerning the onset of the adverse reactions.

Among 10 patients with a history of previous hypersensitivity reaction, five of the six patients in the metrizamide group and one of the four in the iohexol group experienced mild headache.

Neurologic examination revealed no changes of clinical importance.

The radiographic quality was judged good or excellent in all cases. The upper level of contrast medium as seen on the films during myelography is given in Figure 1 and is related to adverse reactions.

In some patients the upper level of contrast medium was higher than that expected in lumbar myelography. In these patients the thoracic region was examined as a secondary part of the examination when their symptomatology could not be sufficiently explained by the findings in the lumbar region.

Four patients in each group had postmyelographic CT in the lumbar region to produce more detailed information about four disk herniations and four lumbar stenoses. There was no correlation between the upper level of contrast medium and use of postmyelographic CT.

### **Discussion**

The incidence of 33% adverse reactions in patients after lumbar myelography with iohexol in our study correlates well with the incidences of 26%, 39%, and 44% in recently published double-blind studies on iohexol lumbar myelography [18–20]. When compared with the scattered percentage of adverse reactions in open studies—14% [16], 17% [17], 35% [14], and 68% [15]—the advantages of randomized double-blind methodology are clear. Findings similar to ours were identified in animal experiments [2, 4, 12, 13] and in clinical studies [18–21]: iohexol caused significantly less frequent and less severe adverse reactions than did metrizamide. Reports of mental disturbances after iohexol myelography are uncommon. Although Cronqvist et al. [22] described some psychic effects after myelography, and Ratcliff et al. [23] do not exclude such an effect, most clinical studies [11, 14–21, 24, 25], as well as our own, do not report any mental disturbance after iohexol.

Interestingly, our EEG results differ from other randomized double-blind controlled studies. The slowing of background activity in EEGs after iohexol and metrizamide was approximately three times the percentage found in a similarly designed study [19]. The percentage of paroxysmal spike activity after metrizamide was also three times greater than found in that study. The percentage of patients with slowing of background activity after iohexol was double that demonstrated in the open studies [14–17].

Our results may reflect a higher sensitivity of our EEG methods. In addition, the contrast media may have been brought to a higher level than in the previously discussed studies. In our study, the contrast medium was brought to the middle or upper thoracic region (Fig. 1). Although the correlation between the upper level of visible contrast medium and the incidence of adverse reactions is controversial in the literature, there are indications that this correlation exists. Nakstad et al. [21] reported in a double-blind study a percentage of EEG changes after cervical and thoracic iohexol myelography that is twice that found in our study, even though the incidence of both slow-wave activity and spike activity



after metrizamide is similar to our results. Also the incidence of subjective adverse reactions after cervical and thoracic myelography [21] was exactly double our incidence after lumbar myelography with both contrast media.

The higher the contrast medium is raised during myelography, the sooner the adverse reactions and EEG changes may occur. In our study no statistically significant correlation was found between the upper level of contrast medium and the interval between the injection and the onset of adverse reactions. In a previous study [21] most of the subjective reactions occurred in the first 8 hr after cervical and thoracic myelography. In our study only half of all subjective reactions occurred in the first 9 hr. Similarly, almost all EEG changes after cervical and thoracic myelography occurred within 6 hr [21], whereas in our study, most EEG changes occurred at 24 hr after lumbar myelography. To receive optimal information about the neurotoxic effects of contrast media it is therefore important to plan appropriate periods of EEG monitoring depending on the type of myelography.

Currently, we do not know to what extent—qualitatively and quantitatively—the shifts of EEG lower frequencies, such as delta and theta, correspond to the clinically apparent nonconvulsive adverse reactions. Interestingly, and with only one exception, all of our patients with postmyelographic EEG changes experienced one or more adverse reactions subjectively (three in the iohexol group and 14 in the metrizamide group). All five patients with mental disturbances after metrizamide displayed pathologic EEG changes (grades 1, 1, 3, 4, and 4, respectively). Other investigators have reported similar findings: three patients who displayed severe EEG changes, including spike activity after cervical myelography, developed multiple postmyelographic symptoms, including mental disturbances [21]. Also, a highly significant correlation was found between the degree of EEG changes and change in behavior in rabbits after subarachnoid metrizamide injection [26].

The slowing of background activity by visual scoring of the EEG was confirmed in FFT analyses. A greater reduction in the peak frequency of the alpha band was found after metrizamide when compared with iohexol. No additional information was gained by FFT analyses when compared with visual evaluation of EEG recordings by an experienced electroencephalographer. These findings are in contradiction to the promising results of the quantitative computerized EEG methods in experimental contrast medium research [3, 4, 6, 7] and should be considered in any future design of myelography-EEG experiments.

Somatosensory evoked potentials were suggested to be a sensitive tool in the detection of neurotoxic effects of contrast media in animal experiments [3]. We chose to study the early components of the somatosensory responses since the later components are much more variable and it was not considered possible in this study to keep the experimental procedures, attention level, and so on so standardized that a meaningful study of the late components could be performed. The early components are more stable and resistant to different drugs. In accordance with this we did not observe any significant changes after myelography or between the two contrast media. However, our findings do not exclude the

possibility that changes of the later components might occur and that they may be sensitive tools for measuring CNS effects of myelographic contrast media provided a strict control of the experimental conditions can be guaranteed.

Iohexol is not completely devoid of an excitative effect on the CNS; Macpherson et al. [24] reported sharp-wave activity on EEG after iohexol cervical myelography in two patients. Increased premyelographic sharp-wave activity occurred in another two patients during the same study. We have not found any epileptogenic activity on EEG after iohexol. These findings correlate with animal experiments [4–7] and with clinical studies [11, 14–17, 19, 21]. We believe that the epileptogenic effect of iohexol is very low compared with the other myelographic contrast media clinically in use.

Owing to a lower epileptogenic effect and to the lower frequency and severity of the subjective adverse reactions we believe iohexol should replace metrizamide in clinical lumbosacral myelography. No additional information about EEG changes induced by contrast media is gained by computerized EEG analysis when EEGs are evaluated by an experienced electroencephalographer.

## REFERENCES

1. Lindgren E, ed. Metrizamide, a non-ionic watersoluble contrast medium. *Acta Radiol (Suppl)* **1973**;335:25–66, 89–101, 125–132, 143–152
2. Golman K, Olivecrona H, Gustafson Ch, Salvesen S, Almén T, Maly P. Excitation and depression of non-anesthetized rabbits following injection of contrast media into the subarachnoid space. *Acta Radiol [Diagn] (Suppl)* **1980**;362:83–86
3. Caillé JM, Gioux M, Arné P, Paty J. Neurotoxicity of nonionic iodinated water-soluble contrast media in myelography: experimental study. *AJNR* **1983**;4:1185–1189
4. Sovak M, Ranganathan R, Kerber CW, Bickford R, Alksna JF. Iotrol, a new myelographic agent: 2. Comparative electroencephalographic evaluation by spectrum analysis. *AJNR* **1983**;4:319–322
5. Gonsette RE, Liesenborgh L. Iogluide: a new contrast medium for myelography and cisternography (animal experiments and preliminary clinical experience). In: Amiel M, ed. *Contrast media in radiology*. Berlin: Springer-Verlag, **1982**:182–187
6. Gonsette RE. Immediate and delayed neurotoxicity of newly synthesized contrast media demonstrated by EEG sequential analysis. In: Amiel M, ed. *Contrast media in radiology*. Berlin: Springer-Verlag, **1982**:141–148
7. Gonsette RE, Brucher JM. Neurotoxicity of novel water-soluble contrast media for intrathecal application. *Invest Radiol (Suppl)* **1980**;15:254–259
8. Carella A, Federico F, DiCuonzo F, Vinjau E, Lamberti P. Adverse side effects of metrizamide and iopamidol in myelography. *Neuroradiology* **1982**;22:247–249
9. Liboni W, Benna P, Duca S, Fra L, Sicuro A. Electrophysiological (EEG, BAEP, VEP, H Reflex) patterns in myelography with nonionic water-soluble contrast media. *Neuroradiology* **1982**;22:277–278
10. Moschini L, Manara O, Bonaldi G, Cassinari V, Quilici N, Belloni G. Iopamidol and metrizamide in cervical myelography: side effects, EEG, and CSF changes. *AJNR* **1983**;4:848–850
11. Lamb JT. Iohexol vs iopamidol for myelography. *Invest Radiol (Suppl)* **1985**;20:37–43
12. Maly P, Almén T, Golman K, Olivecrona H. Excitatory effects in anesthetized rabbits from subarachnoidally injected iso- and hyperosmolar solutions of iohexol and metrizamide. *Neuroradiology* **1984**;26:131–136
13. Maly P, Olivecrona H, Almén T, Golman K. Interaction between chlorpromazine and intrathecally injected non-ionic contrast media in non-anesthetized rabbits. *Neuroradiology* **1984**;26:235–240
14. Eldevik OP, Nakstad P, Kendall BE, Hindmarsh T. Iohexol in lumbar myelography: preliminary results from an open, noncomparative multicen-



- ter clinical study. *AJNR* **1983**;4:299-301
15. Nakstad P, Aaserud O, Sortland O, Nyberg-Hansen R. Functional lumbar myelography with iohexol. *Acta Radiol [Diagn]* **1983**;24:493-497
  16. Ericson K, Hindmarsh T, Hannerz J. Experience with iohexol in lumbar myelography. *Acta Radiol [Diagn]* **1983**;24:503-505
  17. Kendall B, Harrison M, Schneidau A. Clinical trial of iohexol in lumbar myelography. *Acta Radiol [Diagn]* **1983**;24:507-510
  18. Kieffer SA, Binet EF, Davis DO, et al. Lumbar myelography with iohexol and metrizamide: a comparative multicenter prospective study. *Radiology* **1984**;151:665-670
  19. Sortland O, Nestvold K, Kloster R, Aandahl MH. Comparison of iohexol with metrizamide in myelography. *Radiology* **1984**;151:121-122
  20. Hindmarsh T, Ekholm SE, Kido DK, Sahler L, Sands M. Lumbar myelography with iohexol and metrizamide. A double-blind clinical trial. *Acta Radiol [Diagn]* **1984**;25:365-368
  21. Nakstad P, Helgetveit A, Aaserud O, Ganes T, Nyberg-Hansen R. Iohexol compared to metrizamide in cervical and thoracic myelography. A randomized double blind parallel study. *Neuroradiology* **1984**;26:479-484
  22. Cronqvist SE, Holtås SL, Laike T, Ozolins A. Psychic changes following myelography with metrizamide and iohexol. A comparative investigation with psychologic tests. *Acta Radiol [Diagn]* **1984**;25:369-373
  23. Ratcliff G, Sandler S, Latchaw R. Cognitive and affective changes after myelography: a comparison of metrizamide and iohexol. *AJNR* **1986**;6:683-687
  24. Macpherson P, Teasdale E, Coutinho C, McGeorge A. Iohexol versus iopamidol for cervical myelography: a randomised double blind study. *Br J Radiol* **1985**;58:849-851
  25. Batty VB. Cervical myelography using iohexol (Omnipaque), a new contrast medium. *Clin Radiol* **1984**;35:75-77
  26. Maly P, Elmquist D, Almén T, Golman K. Comparison between EEG and observation of rabbit behaviour in evaluation of subarachnoid neurotoxicity of metrizamide. *Acta Radiol [Diagn]* **1986**;27:235-240