



**Use of titanium wire in cervical spine fixation as a means to reduce MR artifacts.**

S E Mirvis, F Geisler, J N Joslyn and H Zrebeet

*AJNR Am J Neuroradiol* 1988, 9 (6) 1229-1231

<http://www.ajnr.org/content/9/6/1229>

This information is current as  
of July 1, 2025.

# Use of Titanium Wire in Cervical Spine Fixation as a Means to Reduce MR Artifacts

Stuart E. Mirvis<sup>1</sup>  
 Fred Geisler<sup>2</sup>  
 John N. Joslyn<sup>1</sup>  
 Hafez Zrebeet<sup>2</sup>

MR imaging of the cervical spine is valuable for assessing traumatic injuries to the spinal cord and bony ligamentous structures. MR is also useful for detecting such long-term complications of spinal cord injury as syrinx, arachnoid cyst, cord adhesion, and persistent mechanical impingement on the spinal cord or spinal nerve roots. Treatment of cervical spine injuries that are mechanically unstable entails fixation and fusion. However, previous attempts at our institution to obtain clinically useful MR images of the cervical region after posterior wire fixation have failed because of image artifacts arising from ferromagnetic stainless steel wires. Use of biocompatible titanium wire for fixation allowed undistorted imaging of the spinal cord and spinal canal adjacent to the surgical fixation in a cadaver and in eight patients.

MR imaging is useful for disclosing pathology of the spinal cord and supporting structures resulting from spinal cord injury. Among the abnormalities revealed on MR images obtained after acute cervical spine trauma are spinal cord hemorrhage and contusions, ligamentous injury, and acute intervertebral disk herniation [1, 2]. Abnormalities demonstrated on MR images in long-term follow-up of the traumatized spinal cord include syrinx, arachnoid cyst, tethering of the cord, and mechanical impingement by supporting elements on the spinal cord or spinal roots [3]. Any one of these sequelae may necessitate surgical intervention.

Many cervical spine injuries are mechanically unstable initially and require posterior internal fixation and fusion as part of their treatment. Currently, surgical stainless steel wire (#18, #20, or twisted paired #22) is used as the basis for internal stabilization of these injuries [4, 5]. The wires are placed directly over the posterior surface of the cervical laminae in both the midline interspinous and the oblique facet to spinous process wiring techniques. Thus, stainless steel wires are within millimeters of the region of the spinal cord and spinal support elements in which pathological sequelae may develop.

Unfortunately, attempts at our institution to obtain clinically useful MR images of the cervical region after posterior wire fixation with stainless steel\* have failed because of the marked artifacts arising from these ferromagnetic stainless steel wires (Fig. 1). In an effort to reduce such artifacts we evaluated the imaging effects of titanium wire used for posterior fixation in a cadaver and in eight patients.

## Methods and Materials

We used 22-gauge surgical titanium wire,<sup>†</sup> which is wound with an electric drill before it is sterilized. The winding is done by securing one of the ends of two strands of wire in a vice and the other ends in the chuck of an electric drill. The drill is turned until a twist tightness of one turn every 5–7 millimeters is obtained. Then, the drill is reversed and the twisted wire unwound approximately three turns so that internal spring tension is released before the drill chuck is opened to remove the wire. The twisted wire is then cut with heavy wire cutters to appropriate surgical lengths before it is washed and sterilized.

Initially, the posterior fixation with titanium wire was done on a cadaver's neck and imaged in our MR unit<sup>‡</sup> with 5-mm axial and sagittal imaging and T1- (500/17, TR/TE), mixed (2500/

Received December 9, 1987; accepted after revision March 30, 1988.

<sup>1</sup> Department of Diagnostic Radiology, University of Maryland Medical System, 22 S. Greene St., Baltimore, MD 21201. Address reprint requests to S. E. Mirvis.

<sup>2</sup> Department of Surgery, Division of Neurosurgery, University of Maryland Medical System, Baltimore, MD 21201.

AJNR 9:1229–1231, November/December 1988  
 0195–6108/88/0906–1229

© American Society of Neuroradiology

\* DS-22 surgical steel monofilament, type B, size 4. Ethicon, Somerville, NJ.

<sup>†</sup> Titanium-6 Al-4V ELI alloy. Specialty Steel and Forge, Leonia, NJ.

<sup>‡</sup> Siemens Magnetom 1.5-T, Iselin, NJ.



40), and T2- (2500/90) weighted sequences, which we typically use in cervical spine imaging. Only minimal signal dropout (less than 2 mm in diameter) was detected around the titanium wires in any slice orientation or signal acquisition sequence. After giving their informed consent, eight patients with posttraumatic posterior spinal column instability were fixed with titanium wires according to standard surgical techniques and were imaged in keeping with the method described above. The fixations were performed at C2–C3 in one patient, at C5–C6 in four patients, and at C6–C7 in three patients. Because they are stiffer than stainless steel wires, the titanium wires were judged by the neurosurgeons to be considerably more difficult to install.

## Results

Clinically useful MR images were obtained in all eight patients after they underwent posterior fixation with titanium

wires. Image artifacts around the wires were minimal and permitted distortion-free assessment of the spinal cord and neural canal adjacent to the wires (Figs. 2 and 3). In this limited series, spinal cord edema, spinal cord contusions, myelomalacia, and mechanical displacement were successfully imaged. The titanium wires appeared slightly less dense radiographically than did the stainless steel wires, but they were still easily visualized.

## Discussion

Titanium has good tissue compatibility and biomedical and mechanical properties, and it was successfully used for internal posterior cervical fixation as part of the management of unstable cervical spine injuries. Other clinical applications for

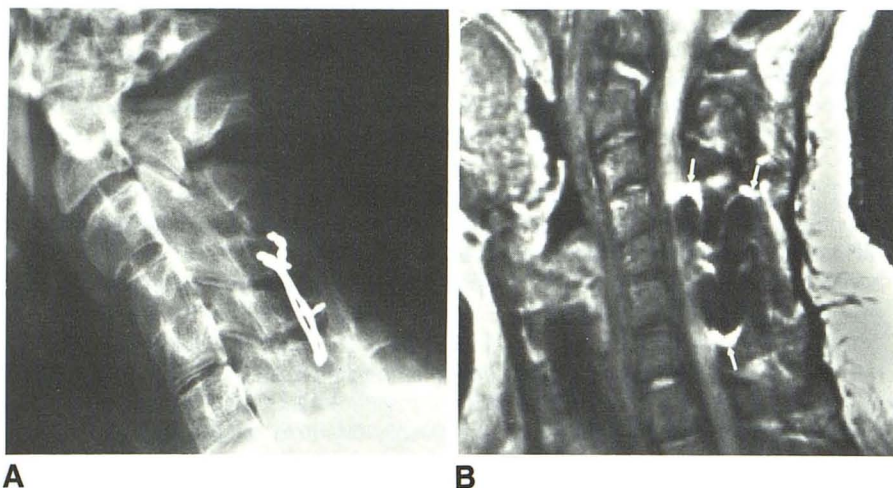


Fig. 1.—MR image distortion from posterior wire fixation with stainless steel.

A, Lateral cervical spine radiograph shows wire fixation and bone graft fusion from the posterior elements of C4 to C6.

B, T1-weighted midline sagittal MR image (500/17) shows typical signal loss with peripheral bright borders surrounding ferromagnetic stainless steel wire (arrows). Adjacent spinal cord and neural canal are significantly obscured by artifact, thus compromising clinical utility of the study.

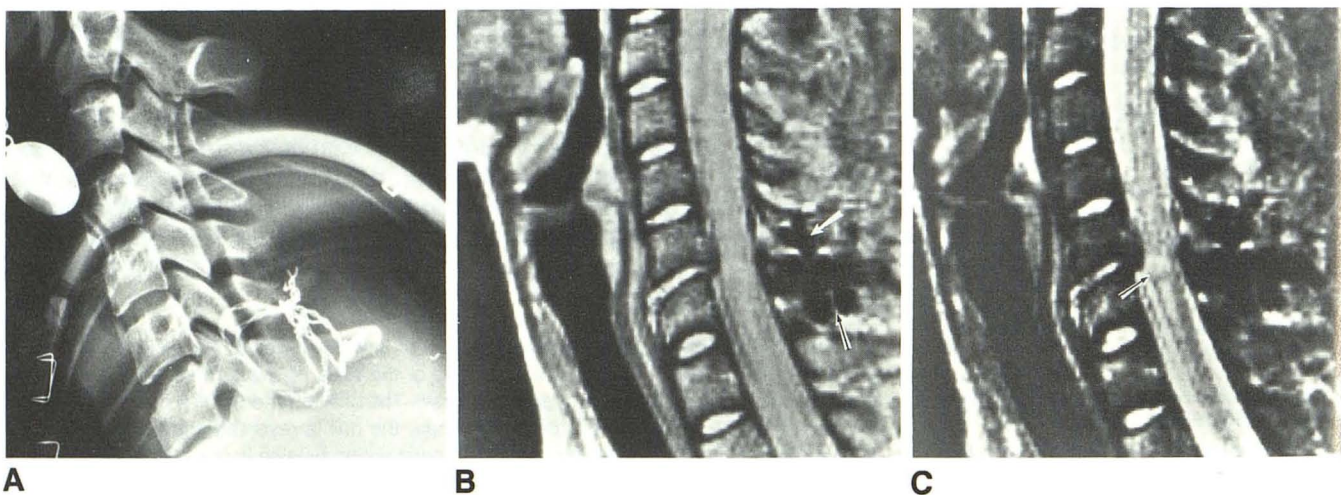


Fig. 2.—MR images after cervical spine fixation with titanium wire.

A, Lateral cervical spine radiograph shows posterior wire fixation between C6 and C7, which was used for management of hyperflexion injury in 24-year-old woman with incomplete C5 quadriplegia. Titanium wire appears to be less radiopaque than stainless steel, but is still easily visualized.

B, Mixed-weighted MR image (2500/40) obtained in mid-sagittal plane reveals slight retropulsion of posteroinferior aspect of C6 vertebral body and anterior herniation of C6–C7 intervertebral disk. Minimal artifact from titanium wires is present (arrows), permitting distortion-free assessment of adjacent spinal cord and neural canal.

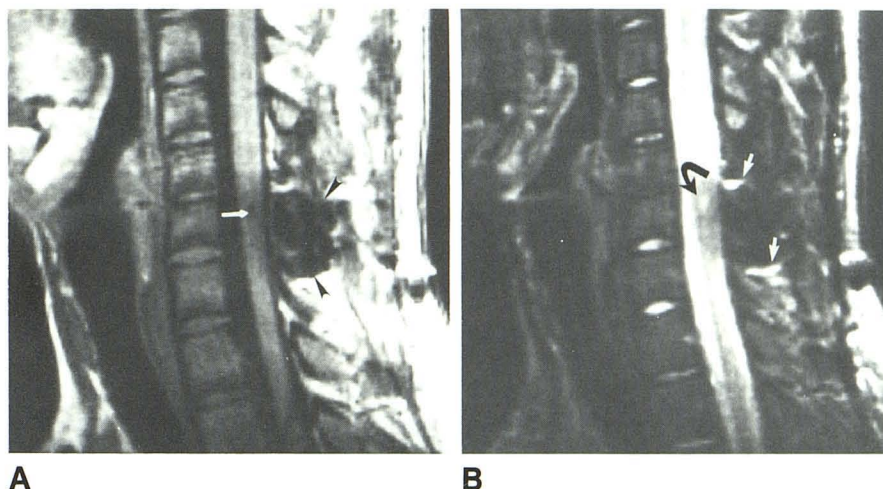
C, T2-weighted mid-sagittal image (2500/90) also demonstrates focal increased signal in spinal cord adjacent to retropulsed portion of C6 vertebral body (arrow), suggestive of a contusion.



Fig. 3.—MR images after posterior cervical fixation with titanium wire.

A, T1-weighted MR image (500/17) obtained in mid-sagittal plane in 18-year-old with mild central cord syndrome obtained after C5–C6 bilateral facet dislocation. Focal central area of decreased signal at upper border of C6 (arrow) is believed to represent an area of myelomalacia or small cyst. There is a region of decreased signal surrounding the titanium wires, which are placed posteriorly at C5 and C6 (arrowheads), that produces a slight uniform decrease in signal in posterior cervical canal.

B, T2-weighted image (2500/90) reveals focal increased signal intensity in same region (curved arrow) with only minimal interference (straight arrows) from adjacent titanium fixation wire.



titanium include orthopedic prostheses, oral implants, reconstructive plastic surgery, and cardiac pacemaker implants [6–8]. The alloy Ti-6 Al-4V has a good combination of mechanical and physical properties, including strength, ductility, and endurance limits as required for surgical implantation [6, 7].

Previous efforts have been made to discover an appropriate material for needles used in MR-guided aspiration biopsies [9]. Mueller et al. [9] tested various stainless steel alloys, brass, copper, and titanium for artifact generation and safety. Their in vitro experiments demonstrated visible image artifacts from the titanium cannula tested (specific alloy not reported), but this was not quantitated or described. Our MR studies of posterior cervical fixations with titanium wire to treat cervical spinal column instability in a cadaver and in six subjects demonstrated a small but acceptable local image degradation produced by the titanium wires.

The MR artifacts from the titanium wires were far less than those produced by stainless steel wires in the same anatomic position. Most stainless steel alloys used for human implantation, while considered nonmagnetic, exhibit considerable ferromagnetism within a strong magnetic field, which in turn contributes to local distortion of the magnetic field and to signal loss [10]. The titanium alloy tested in this study appears to exhibit little or no ferromagnetism in vitro. The minimum signal loss detected around these wires could result from local eddy currents produced by changing magnetic field gradients that may occur in nonferromagnetic conductors [11].

The use of titanium wires enabled us to obtain an undis-

torted image of the spinal cord immediately adjacent to the surgical fixation, whereas the stainless steel wires degraded the MR images to an extent that placed the clinical value of the MR study in question.

#### REFERENCES

1. Hackney DB, Asato R, Joseph P, et al. Hemorrhage and edema in acute spinal cord compression: demonstration by MR imaging. *Radiology* 1986;161:387–390
2. Kulkarni MV, McArdle CB, Kopanicky D, et al. Acute spinal cord injury: MR imaging at 1.5 T. *Radiology* 1987;164:837–843
3. Quencer RM, Sheldon JJ, Post MJD, et al. MRI of the chronically injured cervical spinal cord. *AJR* 1986;147:125–132
4. Cahill DW, Bellagarrigue R, Ducker TB. Bilateral facet to spinous process fusion: a new technique for posterior spinal fusion after trauma. *Neurosurgery* 1983;13(1):1–4
5. Murphy MJ, Southwick WO. Posterior approaches and fusion. In: Bailey R, ed. *The cervical spine. The Cervical Spine Research Society*. Philadelphia: Lippincott, 1983:496–513
6. Williams DF. Titanium as a metal for implantation. *J Med Eng Technol* 1977;1:266–270
7. Hille GH. Titanium for surgical implants. *J Materials* 1966;1:373–383
8. American Society for Testing and Materials. Philadelphia: Designation F 136–79
9. Mueller PR, Stark DD, Simeone JF, et al. MR-guided aspiration biopsy: needle design and clinical trials. *Radiology* 1986;161:605–609
10. New PFJ, Rosen BR, Brady TJ, et al. Potential hazards and artifacts of ferromagnetic and nonferromagnetic surgical and dental materials and devices in nuclear magnetic resonance. *Radiology* 1983;147:139–148
11. Kelly W. Image artifacts and technical limitations. In: Brant-Zawadzki M, Norman D, eds. *Magnetic resonance of the central nervous system*. New York: Raven, 1987:43–82