



**Get Clarity On Generics**

Cost-Effective CT & MRI Contrast Agents



**FRESENIUS  
KABI**

**WATCH VIDEO**

**AJNR**

## **Radiogenomics Provides Insights into Gliomas Demonstrating Single-Arm 1p or 19q Deletion**

Arian Lasocki, Michael E. Buckland, Tahlia Molinaro, Jing Xie and Frank Gaillard

This information is current as of August 6, 2025.

*AJNR Am J Neuroradiol* published online 26 October 2023  
<http://www.ajnr.org/content/early/2023/10/26/ajnr.A8034>

# Radiogenomics Provides Insights into Gliomas Demonstrating Single-Arm 1p or 19q Deletion

 Arian Lasocki,  Michael E. Buckland,  Tahlia Molinaro,  Jing Xie, and  Frank Gaillard

## ABSTRACT

**BACKGROUND AND PURPOSE:** *IDH*-mutant gliomas are further divided on the basis of 1p/19q status: oligodendroglioma, *IDH*-mutant and 1p/19q-codeleted, and astrocytoma, *IDH*-mutant (without codeletion). Occasionally, testing may reveal single-arm 1p or 19q deletion (unideletion), which remains within the diagnosis of astrocytoma. Molecular assessment has some limitations, however, raising the possibility that some unideleted tumors could actually be codeleted. This study assessed whether unideleted tumors had MR imaging features and survival more consistent with astrocytomas or oligodendrogliomas.

**MATERIALS AND METHODS:** One hundred twenty-one *IDH*-mutant grade 2–3 gliomas with 1p/19q results were identified. Two neuroradiologists assessed the T2-FLAIR mismatch sign and calcifications, as differentiators of astrocytomas and oligodendrogliomas. MR imaging features and survival were compared among the unideleted tumors, codeleted tumors, and those without 1p or 19q deletion.

**RESULTS:** The cohort comprised 65 tumors without 1p or 19q deletion, 12 unideleted tumors, and 44 codeleted. The proportion of unideleted tumors demonstrating the T2-FLAIR mismatch sign (33%) was similar to that in tumors without deletion (49%;  $P = .39$ ), but significantly higher than codeleted tumors (0%;  $P = .001$ ). Calcifications were less frequent in unideleted tumors (0%) than in codeleted tumors (25%), but this difference did not reach statistical significance ( $P = .097$ ). The median survival of patients with unideleted tumors was 7.8 years, which was similar to that in tumors without deletion (8.5 years;  $P = .72$ ) but significantly shorter than that in codeleted tumors (not reaching median survival after 12 years;  $P = .013$ ).

**CONCLUSIONS:** *IDH*-mutant gliomas with single-arm 1p or 19q deletion have MR imaging appearance and survival that are similar to those of astrocytomas without 1p or 19q deletion and significantly different from those of 1p/19q-codeleted oligodendrogliomas.

**ABBREVIATIONS:** codelet = codeleted; FISH = fluorescence in situ hybridization; *IDH*<sup>mut</sup> = *IDH*-mutant; *IDH*<sup>WT</sup> = *IDH*-wild-type; WHO = World Health Organization

The molecular status of tumors of the CNS is of increasing importance in their classification. The 2016 update to the World Health Organization Classification of Tumors of the Central Nervous System (henceforth WHO 2016) introduced molecular status into the diagnosis of intracranial gliomas.<sup>1</sup> Some of the key changes related to grade 2–3 gliomas, which were

divided into 3 subtypes based on *IDH* and 1p/19q status: oligodendroglioma, *IDH*-mutant (*IDH*<sup>mut</sup>) and 1p/19q-codeleted (demonstrating combined loss of the short arm of chromosome 1 and the long arm of chromosome 19 [1p/19q<sup>codelet</sup>]); astrocytoma, *IDH*<sup>mut</sup> (without 1p/19q-codeletion); and astrocytoma, *IDH*-wild-type (without an *IDH* mutation [*IDH*<sup>WT</sup>]).<sup>1</sup> The 2021 WHO classification (henceforth WHO 2021) increased the importance of molecular status in tumor diagnosis.<sup>2</sup> For example, CDKN2A/B copy number status has become important in the grading of *IDH*<sup>mut</sup> astrocytomas, with CDKN2A/B homozygous deletion allowing the diagnosis of a grade 4 tumor even in the absence of the classic histologic features of microvascular proliferation and necrosis.<sup>2</sup>

Occasionally, testing for 1p/19q status may reveal a single-arm 1p or 19q deletion (unideletion), without 1p/19q-codeletion. Such tumors (provided they are *IDH*<sup>mut</sup>) remain within the diagnosis of astrocytoma, *IDH*<sup>mut</sup>. Despite being the criterion standard, molecular assessment can have some limitations. For example, 1p/19q fluorescence in situ hybridization (FISH) can produce false-

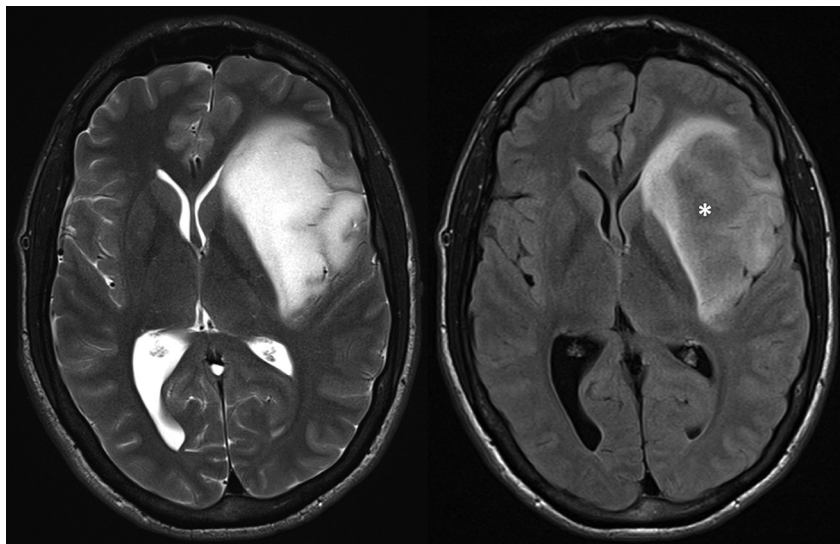
Received April 27, 2023; accepted after revision September 15.

From the Department of Cancer Imaging (A.L.), Department of Medical Oncology (T.M.), and Centre for Biostatistics and Clinical Trials (J.X.), Peter MacCallum Cancer Centre, Melbourne, Victoria, Australia; Sir Peter MacCallum Department of Oncology (A.L.) and Department of Radiology (A.L., F.G.), The University of Melbourne, Parkville, Victoria, Australia; Department of Neuropathology (M.E.B.), Royal Prince Alfred Hospital, Camperdown, New South Wales, Australia; School of Medical Sciences (M.E.B.), University of Sydney, Camperdown, New South Wales, Australia; and Department of Radiology (F.G.), The Royal Melbourne Hospital, Parkville, Victoria, Australia.

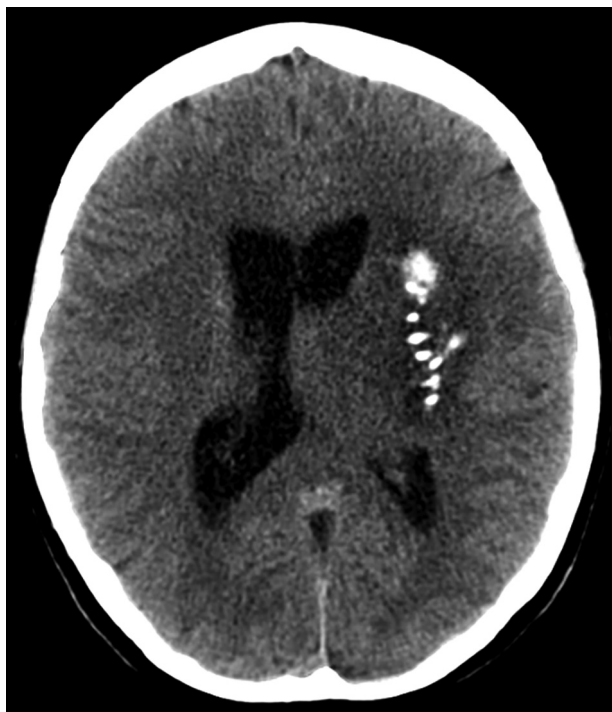This study was supported by a RANZCR research grant in 2018.

Please address correspondence to Arian Lasocki, MD, Department of Cancer Imaging, Peter MacCallum Cancer Centre, Grattan St, Melbourne, Victoria 3000, Australia; e-mail: arian.lasocki@petermac.org

<http://dx.doi.org/10.3174/ajnr.A8034>



**FIG 1.** T2-weighted (left) and FLAIR (right) MR images of a left fronto-insular glioma show that much of the tumor has substantially lower signal on FLAIR (asterisk) than on T2-weighted imaging, consistent with the T2-FLAIR mismatch sign, which is characteristic of astrocytoma,  $IDH^{mut}$ . This tumor had a single-arm 19q deletion.



**FIG 2.** This unenhanced CT image demonstrates calcifications in an oligodendroglioma ( $IDH^{mut}$  and 1p/19q<sup>codelet</sup>) involving the left insula.

positive results in the presence of partial deletions.<sup>3</sup> In addition, sequencing can provide false-negative results if there are relatively few tumor cells within the sample,<sup>4</sup> particularly relevant to gliomas from which only a small sample can be safely obtained. The possibility of sampling error is also particularly relevant to intracranial diffuse gliomas, given their inherent heterogeneity.<sup>5</sup> This raises the likelihood that some tumors diagnosed as having 1p- or 19q-unideletion could actually be 1p/19q codeleted (1p/19q<sup>codelet</sup>),

which has implications not only for formal diagnosis but also for grading and treatment.

The field of radiogenomics aims to predict glioma genotype on the basis of imaging features, most commonly using MR imaging, and a variety of features have been studied.<sup>6</sup> The T2-FLAIR mismatch sign, strongly predictive of an  $IDH^{mut}$  astrocytoma in the case of histologic grade 2–3 gliomas, is the most distinctive feature across all diffuse glioma grades and genotypes.<sup>6–10</sup> Calcification has long been reported as a feature of oligodendrogliomas based on the histologic criteria before WHO 2016, and it has also been more recently confirmed as a predictor of oligodendroglioma,  $IDH^{mut}$  and 1p/19q<sup>codelet</sup>.<sup>8,11,12</sup> Additional features can be helpful in distinguishing 2 of the 3 glioma genotypes, but they are less predictive when all 3 are included.<sup>6</sup>

For example, a frontal lobe location predicts an  $IDH$  mutation but has less predictive value for determining 1p/19q status.<sup>6</sup>

Radiogenomics has the potential to overcome some of the limitations of histologic assessment.<sup>13</sup> For example, Patel et al<sup>14</sup> demonstrated that MR imaging features were able to identify some tumors incorrectly classified as 1p/19q<sup>codelet</sup> based on FISH. We sought to use radiogenomics to provide additional insight into gliomas demonstrating 1p- or 19q-unideletion, by determining whether their MR imaging features were more consistent with astrocytomas ( $IDH^{mut}$  but without 1p/19q<sup>codelet</sup>) or oligodendrogliomas ( $IDH^{mut}$  and 1p/19q<sup>codelet</sup>), by using the T2-FLAIR mismatch sign (Fig 1) and the presence of calcifications (Fig 2), because the literature<sup>6</sup> suggests these features as the best differentiators of the 2 tumor types. The survival associated the different tumor types was also compared.

## MATERIALS AND METHODS

Results from 2 previous radiogenomics studies were combined to identify  $IDH^{mut}$  grade 2–3 gliomas with available 1p/19q testing results.<sup>8,12</sup> All were adult patients. In the earlier study, 1p/19q status had been determined by FISH,<sup>8</sup> while in the later study, next-generation sequencing was used unless FISH results were already available as part of routine clinical practice or earlier research.<sup>12</sup> MR imaging had been performed on a variety of scanners, including at external institutions, and included, at least, T2WI, FLAIR, and pre- and postcontrast T1WI.<sup>8,12</sup> The T2-FLAIR mismatch sign and the presence of calcifications on preoperative imaging were assessed by 2 neuroradiologists with subspecialty expertise in neuro-oncology, blinded to the molecular diagnosis. Discrepancies were resolved by consensus. Identification of the T2-FLAIR mismatch sign was based on the definition originally presented by Patel et al,<sup>9</sup> namely an area of non-contrast-enhancing tumor demonstrating high T2 signal and relatively hypointense FLAIR signal. The T2-FLAIR mismatch sign was considered positive

**Table 1: Patient demographics for the 3 tumor genotypes and the overall cohort**

	No Deletion	Unideletion	Co-Deletion	Total
No. (%)	65 (54%)	12 (10%)	44 (36%)	121
Age (yr)				
Range	17–70	23–61	17–72	17–72
Median	37	34	39	37
Sex				
Male	42 (65%)	7 (58%)	24 (55%)	73 (60%)
Female	23 (35%)	5 (42%)	20 (45%)	48 (40%)

**Table 2: Comparison of imaging features and median survival across the 3 tumor genotypes**

	No Deletion	Unideletion	Co-Deletion
T2-FLAIR mismatch			
Present	32 (49%)	4 (33%)	0 (0%)
Absent	33 (51%)	8 (67%)	44 (100%)
P value	$P = .39$	Reference	$P = .0013$
Calcifications			
Present	2 (3%)	0 (0%)	11 (25%)
Absent	63 (97%)	12 (100%)	33 (75%)
P value	$P = 1$	Reference	$P = .097$
Survival			
Median (yr)	8.5	7.8	>12
P value	$P = .72$	Reference	$P = .013$

Statistical correlations were performed using the Fisher exact test. Survival was assessed using Kaplan-Meier curves. The multivariate model included patient age, sex, and histologic tumor grade (2 or 3). A  $P$  value  $< .05$  was considered statistically significant. All statistical analyses were performed with R statistical and computing software (Version 4.0.3; <http://www.r-project.org/>) using standard and validated statistical procedures.

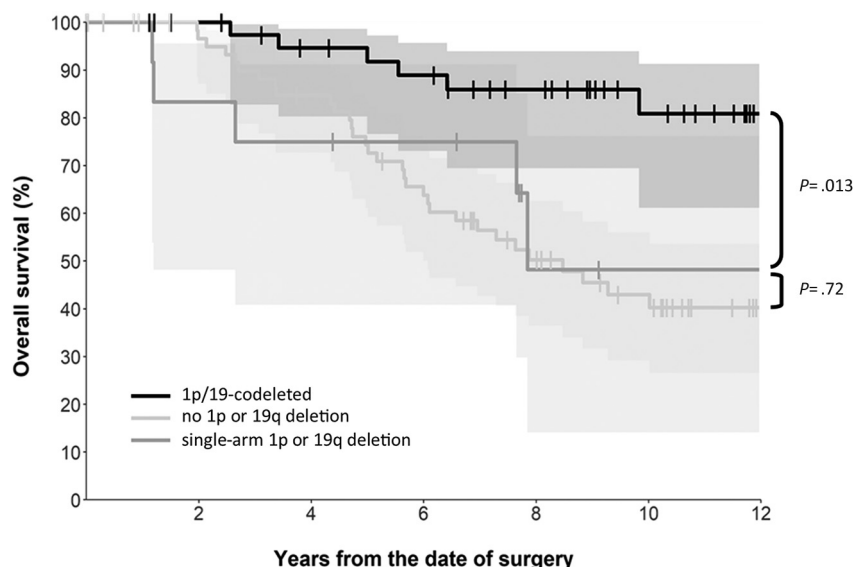
## RESULTS

One hundred twenty-one patients with an  $IDH^{mut}$  grade 2–3 gliomas with available 1p/19q results were identified across the 2 studies. These comprised 65 tumors without 1p or 19q deletion, 12 tumors with unideletion (11 with 19q-unideletion and 1 with 1p-unideletion), and 44 1p/19q<sup>codelet</sup> tumors. Most tumors were WHO grade 2 (103 of 121, or 85%); the remainder were grade 3. The median age across the cohort was 37 years (range, 17–72 years), with a slightly greater proportion of males (73 of 121, or 60%). The demographics of the patients across the 3 genotypes and the overall cohort are summarized in Table 1.

T2-FLAIR mismatch was identified in 4 (33%) of the 12 tumors with unideletion, 32 (49%) of 65 tumors without deletion, and none (0%) of the 44 codeleted tumors. There was a significant difference

in the frequency of T2-FLAIR mismatch when comparing the unideleted and codeleted tumors ( $P = .001$ ), but there was no significant difference when comparing the unideleted tumors and those without deletion ( $P = .39$ ). Calcifications were demonstrated in none (0%) of the unideleted tumors, 2 (3%) of the tumors without deletion, and 11 (25%) of the codeleted tumors. There was a trend ( $P = .097$ ) toward a difference in the frequency of calcifications when comparing the unideleted and codeleted tumors, but no significant difference was found when comparing the unideleted tumors and those without deletion ( $P = 1$ ). Of note, the tumor with 1p-unideletion demonstrated neither T2-FLAIR mismatch nor calcifications. The above results are summarized in Table 2.

The median survival of patients with unideleted tumors was 7.8 years, which was similar to the median survival of



**FIG 3.** Kaplan-Meier survival curves of all 3 groups of tumors, demonstrating that the unideleted tumors in the cohort had survival that was significantly shorter than that of 1p/19q<sup>codelet</sup> tumors ( $P = .013$ ), but similar to that in tumors without 1p or 19q deletion ( $P = .72$ ).

if  $>50\%$  mismatch was present.<sup>8,12</sup> Assessment for calcifications also used susceptibility-sensitive sequences and relevant CT studies, when available.<sup>8,12</sup> If magnetic susceptibility on MR imaging or precontrast hyperdensity on CT or both were present but could not be confidently attributed to calcification as opposed to hemorrhage, this feature was considered negative for calcification. Good interobserver agreement has already been reported, with  $\kappa > 0.6$  for both features across both cohorts.<sup>8,12</sup>

The presence of the 2 MR imaging features was considered across 3 tumor groups (all being  $IDH^{mut}$ ): no 1p or 19q deletion, single-arm 1p or 19q deletion (unideletion), and 1p/19q<sup>codelet</sup>.

8.5 years for those with tumors without deletion ( $P = .72$ ). In contrast, the median survival was not reached for the codeleted tumors after 12 years of follow-up, and there was a statistically significant difference in survival between those with unideleted and codeleted tumors ( $P = .013$  on multivariate analysis). Kaplan-Meier survival curves for all 3 tumor groups are shown in Fig 3, and median survival data are also included in Table 2.

## DISCUSSION

Both our imaging and survival data strongly support that tumors with single-arm 1p or 19q deletion are equivalent to  $IDH^{mut}$



astrocytomas, rather than oligodendrogliomas, in line with the WHO classification.<sup>2</sup> This finding provides reassurance to pathologists and treating clinicians that tumors with 1p- or 19q-unideletion should indeed be considered astrocytomas, rather than having a reason to question the 1p/19q result or repeat testing on a different part of the tumor. Our results are also concordant with our understanding of the underlying biology: 1p/19q-codeletion is thought to occur due to a translocation between chromosomes 1 and 19, with loss of the resulting derivative chromosome,<sup>15,16</sup> accounting for the simultaneous deletion of both chromosome arms. In turn, this implies that single-arm 1p or 19q deletion occurs through different mechanisms, which then manifest as different MR imaging appearances and clinical behavior compared with those of an oligodendroglioma.

Despite the large amount of research into glioma radiogenomics, more recently incorporating artificial intelligence, clinical translation of these techniques has been limited and should be a priority for future research.<sup>17,18</sup> We see radiogenomics as complementary to the criterion standard histologic/molecular assessment, rather than a competing technique. As noted before, radiogenomics can be used to question a molecular testing result, prompting additional genetic testing and hence refinement of the diagnosis.<sup>14</sup> We have demonstrated another potential role of radiogenomics through this work, namely using MR imaging to support the molecular diagnosis and provide additional insight into the underlying tumor biology.

We deliberately assessed only 2 of the radiogenomic features described in grade 2–3 tumors, because these features are the most specific predictors of genotype when *IDH* status is unknown.<sup>6</sup> As we sought to identify features that might potentially question the molecular testing result, it was important to select features with high specificity,<sup>13</sup> rather than necessarily those with the highest sensitivity or overall accuracy. Some other features can help distinguish astrocytomas and oligodendrogliomas if the tumor is known to be *IDH*<sup>mut</sup>—ie, predicting whether the tumor is 1p/19q<sup>codelet</sup>—but are less helpful discriminators if an *IDH*<sup>wt</sup> tumor is also a consideration. For example, oligodendrogliomas tend to be more ill-defined and demonstrate lower ADC values than *IDH*<sup>mut</sup> astrocytomas,<sup>19–22</sup> but *IDH*<sup>wt</sup> tumors are also usually ill-defined, with generally even lower ADC values than oligodendrogliomas.<sup>6,23–26</sup> Similarly, oligodendrogliomas can demonstrate elevated CBV even when low-grade,<sup>27</sup> but CBV elevation is also a feature of *IDH*<sup>wt</sup> tumors.<sup>28</sup> It can be challenging to confidently distinguish calcification and hemorrhage, especially if a preoperative CT scan is not available, so it is possible that calcification could have been underdiagnosed among the unideleted tumors. However, this issue is also true of the oligodendrogliomas, so if optimal characterization had been possible for all tumors, we consider it more likely that calcification would have been identified in additional oligodendrogliomas. If so, a statistically significant difference in the frequency of calcifications between the unideleted and codeleted tumors may have been found. Despite these limitations, we think that our results show quite conclusively that the MR imaging features of unideleted tumors are equivalent to those of *IDH*<sup>mut</sup> astrocytomas rather than oligodendrogliomas.

It was not feasible to correct for treatment in the survival analysis, because the use of chemotherapy and/or radiation therapy was often prompted by evidence of tumor progression, thus could not be considered an independent variable. We did not consider it appropriate to correct for the 2 imaging features assessed in our survival analysis because none of the 1p/19q<sup>codelet</sup> tumors demonstrated T2-FLAIR mismatch and none of the unideleted tumors exhibited calcifications. Additionally, the survival of patients with *IDH*<sup>mut</sup> astrocytomas with and without T2-FLAIR mismatch has already been compared for part of this cohort, with no significant difference in survival found.<sup>29</sup>

We note that there was only one 1p-unideleted tumor in our cohort; thus, it is not possible to assess any potential differences in the MR imaging appearance between 1p- and 19q-unideleted tumors. This is in line with earlier research demonstrating a larger (albeit still small) number of tumors with single-arm 19q deletion than 1p-unideletion.<sup>16,30</sup> Given that 1p- or 19q-unideletion does not alter the molecular diagnosis, it is possible that such findings were under-reported (predominantly for the minority of 1p/19q testing in this cohort that was performed as standard of care), though the numbers seem to be broadly consistent with those in previous studies.<sup>16,30</sup> The rarity of 1p-unideleted tumors implies that if only chromosome 1 were to be assessed, most tumors with 1p deletion would actually be 1p/19q<sup>codelet</sup>. This possibility likely accounts for earlier research showing that 1p deletion predicts a better response to chemotherapy and longer survival.<sup>31</sup>

We acknowledge that the number of unideleted tumors in our cohort is small, but these tumors are uncommon, representing a small proportion of *IDH*-mutant histologic grade 2–3 gliomas (10% in our cohort), which themselves comprise a minority of all adult-type diffuse gliomas. Although these relatively small numbers invite further validation, ultimately our results are themselves providing validation for the existing WHO guidelines, utilizing the unique and complementary ability of imaging to assess the entire tumor. This feature increases confidence that an *IDH*<sup>mut</sup> glioma shown to have single-arm 1p or 19q deletion can truly be considered an astrocytoma, in turn increasing confidence regarding the appropriate management.

## CONCLUSIONS

We have shown that *IDH*<sup>mut</sup> gliomas demonstrating single-arm 1p or 19q deletion have MR imaging appearances and survival similar to those of astrocytomas without 1p or 19q deletion and significantly different from those of 1p/19q<sup>codelet</sup> oligodendrogliomas. This result supports the existing WHO classification that such tumors lie within the spectrum of astrocytomas.

**Disclosure forms** provided by the authors are available with the full text and PDF of this article at [www.ajnr.org](http://www.ajnr.org).

## REFERENCES

- Louis DN, Perry A, Reifenberger G, et al. **The 2016 World Health Organization Classification of Tumors of the Central Nervous System: a summary.** *Acta Neuropathol* 2016;131:803–20 [CrossRef Medline](#)
- Louis DN, Perry A, Wesseling P, et al. **The 2021 WHO Classification of Tumors of the Central Nervous System: a summary.** *Neuro Oncol* 2021;23:1231–51 [CrossRef Medline](#)

3. Horbinski C, Nikiforova MN, Hobbs J, et al. **The importance of 10q status in an outcomes-based comparison between 1p/19q fluorescence in situ hybridization and polymerase chain reaction-based microsatellite loss of heterozygosity analysis of oligodendrogliomas.** *J Neuropathol Exp Neurol* 2012;71:73–82 [CrossRef Medline](#)
4. Horbinski C. **What do we know about IDH1/2 mutations so far, and how do we use it?** *Acta Neuropathol* 2013;125:621–36 [CrossRef Medline](#)
5. Lasocki A, Tsui A, Tacey MA, et al. **MRI grading versus histology: predicting survival of World Health Organization grade II–IV astrocytomas.** *AJNR Am J Neuroradiol* 2015;36:77–83 [CrossRef Medline](#)
6. Lasocki A, Anjari M, Örs Kokurcan S, et al. **Conventional MRI features of adult diffuse glioma molecular subtypes: a systematic review.** *Neuroradiology* 2021;63:353–62 [CrossRef Medline](#)
7. Broen MPG, Smits M, Wijnenga MMJ, et al. **The T2-FLAIR mismatch sign as an imaging marker for non-enhancing IDH-mutant, 1p/19q-intact lower grade glioma: a validation study.** *Neuro Oncol* 2018;20:1393–99 [CrossRef Medline](#)
8. Lasocki A, Gaillard F, Gorelik A, et al. **MRI features can predict 1p/19q status in intracranial gliomas.** *AJNR Am J Neuroradiol* 2018;39:687–92 [CrossRef Medline](#)
9. Patel SH, Poisson LM, Brat DJ, et al. **T2-FLAIR mismatch, an imaging biomarker for IDH and 1p/19q status in lower-grade gliomas: a TCGA/TCIA project.** *Clin Cancer Res* 2017;23:6078–85 [CrossRef Medline](#)
10. Park SI, Suh CH, Guenette JP, et al. **The T2-FLAIR mismatch sign as a predictor of IDH-mutant, 1p/19q-noncodeleted lower-grade gliomas: a systematic review and diagnostic meta-analysis.** *Eur Radiol* 2021;31:5289–99 [CrossRef Medline](#)
11. Saito T, Muragaki Y, Maruyama T, et al. **Calcification on CT is a simple and valuable preoperative indicator of 1p/19q loss of heterozygosity in supratentorial brain tumors that are suspected grade II and III gliomas.** *Brain Tumor Pathol* 2016;33:175–82 [CrossRef Medline](#)
12. Lasocki A, Buckland ME, Drummond KJ, et al. **Conventional MRI features can predict the molecular subtype of adult grade 2–3 intracranial diffuse gliomas.** *Neuroradiology* 2022;64:2295–305 [CrossRef Medline](#)
13. Lasocki A, Rosenthal MA, Roberts-Thomson SJ, et al. **Neuro-oncology and radiogenomics: time to integrate?** *AJNR Am J Neuroradiol* 2020;41:1982–88 [CrossRef Medline](#)
14. Patel SH, Batchala PP, Mrachek EK, et al. **MRI and CT identify isocitrate dehydrogenase (IDH)-mutant lower-grade gliomas misclassified to 1p/19q codeletion status with fluorescence in situ hybridization.** *Radiology* 2020;294:160–67 [CrossRef Medline](#)
15. Brandner S, McAleenan A, Jones HE, et al. **Diagnostic accuracy of 1p/19q codeletion tests in oligodendroglioma: a comprehensive meta-analysis based on a Cochrane systematic review.** *Neuropathol Appl Neurobiol* 2022;48:e12790 [CrossRef Medline](#)
16. Jenkins RB, Blair H, Ballman KV, et al. **A t(1;19)(q10;p10) mediates the combined deletions of 1p and 19q and predicts a better prognosis of patients with oligodendroglioma.** *Cancer Res* 2006;66:9852–61 [CrossRef Medline](#)
17. Bhandari AP, Liong R, Koppen J, et al. **Noninvasive determination of IDH and 1p19q status of lower-grade gliomas using MRI radiomics: a systematic review.** *AJNR Am J Neuroradiol* 2021;42:94–101 [CrossRef Medline](#)
18. Kalaroopan D, Lasocki A. **MRI-based deep learning techniques for the prediction of isocitrate dehydrogenase and 1p/19q status in grade 2–4 adult gliomas.** *J Med Imaging Radiat Oncol* 2023;67:492–98 [CrossRef Medline](#)
19. Johnson DR, Diehn FE, Giannini C, et al. **Genetically defined oligodendroglioma is characterized by indistinct tumor borders at MRI.** *AJNR Am J Neuroradiol* 2017;38:678–84 [CrossRef Medline](#)
20. Kim JW, Park CK, Park SH, et al. **Relationship between radiological characteristics and combined 1p and 19q deletion in World Health Organization grade III oligodendroglial tumours.** *J Neurol Neurosurg Psychiatry* 2011;82:224–27 [CrossRef Medline](#)
21. Cui Y, Ma L, Chen X, et al. **Lower apparent diffusion coefficients indicate distinct prognosis in low-grade and high-grade glioma.** *J Neurooncol* 2014;119:377–85 [CrossRef Medline](#)
22. Thust SC, Hassanein S, Bisdas S, et al. **Apparent diffusion coefficient for molecular subtyping of non-gadolinium-enhancing WHO grade II/III glioma: volumetric segmentation versus two-dimensional region of interest analysis.** *Eur Radiol* 2018;28:3779–88 [CrossRef Medline](#)
23. Darlix A, Deverdun J, Menjot de Champfleury N, et al. **IDH mutation and 1p19q codeletion distinguish two radiological patterns of diffuse low-grade gliomas.** *J Neurooncol* 2017;133:37–45 [CrossRef Medline](#)
24. Delfanti RL, Piccioni DE, Handwerker J, et al. **Imaging correlates for the 2016 update on WHO classification of grade II/III gliomas: implications for IDH, 1p/19q and ATRX status.** *J Neurooncol* 2017;135:601–09 [CrossRef Medline](#)
25. Hyare H, Rice L, Thust S, et al. **Modelling MR and clinical features in grade II/III astrocytomas to predict IDH mutation status.** *Eur J Radiol* 2019;114:120–27 [CrossRef Medline](#)
26. Park YW, Han K, Ahn SS, et al. **Prediction of IDH1-mutation and 1p/19q-codeletion status using preoperative MR imaging phenotypes in lower grade gliomas.** *AJNR Am J Neuroradiol* 2018;39:37–42 [CrossRef Medline](#)
27. Lev MH, Ozsunar Y, Henson JW, et al. **Glial tumor grading and outcome prediction using dynamic spin-echo MR susceptibility mapping compared with conventional contrast-enhanced MR: confounding effect of elevated rCBV of oligodendrogliomas [corrected].** *AJNR Am J Neuroradiol* 2004;25:214–21 [Medline](#)
28. Xing Z, Yang X, She D, et al. **Noninvasive assessment of IDH mutational status in World Health Organization grade II and III astrocytomas using DWI and DSC-PWI combined with conventional MR imaging.** *AJNR Am J Neuroradiol* 2017;38:1138–44 [CrossRef Medline](#)
29. Lasocki A, Buckland ME, Molinaro T, et al. **Correlating MRI features with additional genetic markers and patient survival in histological grade 2–3 IDH-mutant astrocytomas.** *Neuroradiology* 2023;65:1215–23 [CrossRef Medline](#)
30. Vogazianou AP, Chan R, Bäccklund LM, et al. **Distinct patterns of 1p and 19q alterations identify subtypes of human gliomas that have different prognoses.** *Neuro Oncol* 2010;12:664–78 [CrossRef Medline](#)
31. Thiessen B, Maguire JA, McNeil K, et al. **Loss of heterozygosity for loci on chromosome arms 1p and 10q in oligodendroglial tumors: relationship to outcome and chemosensitivity.** *J Neurooncol* 2003;64:271–78 [CrossRef Medline](#)