

Get Clarity On Generics

Cost-Effective CT & MRI Contrast Agents



FRESENIUS
KABI

WATCH VIDEO

AJNR

Lateral Compression Manipulation: A Simple Approach for Sizing Taller-Than-Wide Intracranial Aneurysms with the Woven EndoBridge (WEB) Device

H.S. Chew, M.Y. Chong, W. Butt, S. Al-Ali, B. Butler, M. Al-Tibi, S. Chavda and S. Lamin

This information is current as of August 11, 2025.

AJNR Am J Neuroradiol published online 30 January 2024
<http://www.ajnr.org/content/early/2024/01/25/ajnr.A8172>

Lateral Compression Manipulation: A Simple Approach for Sizing Taller-Than-Wide Intracranial Aneurysms with the Woven EndoBridge (WEB) Device

H.S. Chew, M.Y. Chong, W. Butt, S. Al-Ali, B. Butler, M. Al-Tibi, S. Chavda, S. Lamin

ABSTRACT

BACKGROUND AND PURPOSE: The Woven EndoBridge (WEB) system (MicroVention in Tustin, CA, USA) has established itself as a safe and effective option for managing wide-necked bifurcation aneurysms. Addressing aneurysms with a greater height than width using conventional WEB sizing methods has proven ineffective due to the inherent configuration of the devices. To overcome this limitation, we propose an intuitive approach which involves swapping the width and height dimensions of the aneurysm to determine the appropriate WEB size.

MATERIALS AND METHODS: A retrospective analysis was conducted on patients undergoing WEB embolization treatment at a single neuroscience center from March 2013 to February 2023.

RESULTS: Twenty-five eligible aneurysms were identified, with the height dimension exceeding the width by an average of 2.33 mm (ranging from 1.4 to 4.5 mm). Out of these, twenty cases adhered to the recommended sizing technique, resulting in a 100% success rate of adequate occlusion (14/20 complete occlusion, 6/20 proximal recess filling). In contrast, the outcomes for the remaining five cases that did not follow the proposed sizing method were less favorable ($p < 0.05$). Among these, four cases treated with undersized WEBs showed neck remnants during follow-up, and one patient who received an oversized WEB required device replacement during the same procedure.

CONCLUSIONS: The simple sizing method we proposed for treating taller-than-wide aneurysms has demonstrated promising results, allowing the WEB system to address twice the original size range of treatable aneurysms. Further research with a larger sample size is recommended.

ABBREVIATIONS: WEB = Woven EndoBridge; SL = Single Layer; SLS = Single Layer Sphere.

Received month day, year; accepted after revision month day, year.

From the Department of Neuroradiology, Queen Elizabeth Hospital Birmingham, Birmingham, UK.

Disclosure of potential conflicts of interest should be included here.

Please address correspondence to Han Seng Chew, MD, Department of Neuroradiology, Queen Elizabeth Hospital Birmingham, Mindelsohn Way, Edgbaston, B15 2GW Birmingham, UK; e-mail: hanseng.chew@uhb.nhs.uk

SUMMARY SECTION

PREVIOUS LITERATURE: The concept of increasing lateral compression to strengthen the WEB device is widely known. However, conventional sizing methods, such as the +1/-1 rule or reliance on the manufacturer's WEB sizing chart, often face challenges in providing the necessary height extension for optimal fit in aneurysms with a high height-to-dome ratio.

KEY FINDINGS: Interchanging the height and width dimensions consistently yields reliable results for sizing taller-than-wide aneurysms. This straightforward and practical approach has the potential to expand the original range of treatable aneurysms without the need for additional fixed-sized WEB implants.

KNOWLEDGE ADVANCEMENT: Exploring the impact of manipulating lateral compression holds promise for enhancing the clinical versatility of the WEB device.

INTRODUCTION

The Woven EndoBridge (WEB) device has emerged as a reliable and effective solution for the treatment of wide-necked intracranial bifurcation aneurysms.¹ Accurate device sizing is crucial for achieving favorable angiographic outcomes.² However, traditional sizing methods like the +1/-1 rule or referencing the manufacturer's sizing chart may struggle to deliver the necessary height extension to achieve an optimal fit for aneurysms characterized by a high height-to-dome ratio (Figure 1). To address this issue, we introduce an intuitive approach that prompts the device to undergo significant lateral compression, leading to a substantial increase in its vertical extension. The main purpose of this article is to provide an in-depth exploration of the proposed sizing strategy and highlight its potential in enhancing the clinical utility of the WEB system.

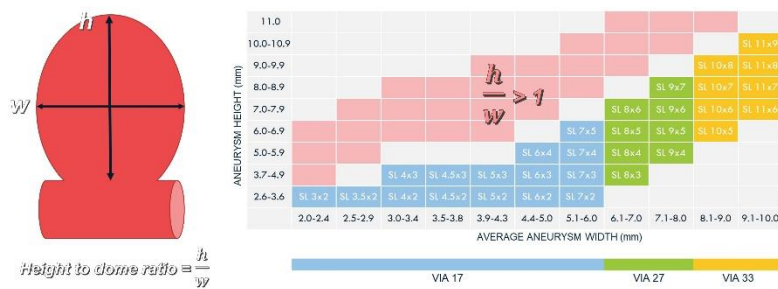

FIG 1. The manufacturer's sizing chart for the WEB device does not cover aneurysms with a height-to-dome ratio > 1. Our proposed approach expands the original range of treatable aneurysms to include those showed in the red zone, effectively doubling the spectrum of aneurysms without the need for additional fixed-sized WEB devices.

MATERIALS AND METHODS

We conducted a retrospective review of patients who underwent WEB embolization treatment at our institution from March 2013 to February 2023. To qualify for inclusion in the analysis, we define an aneurysm as taller-than-wide when its height-to-dome ratio surpasses one.

Data collection includes patient demographics, aneurysm characteristics, device parameters and angiographic outcomes. Surveillance imaging protocols for individuals who receive WEB embolization include DSA and MRA at 6-month and 2-year intervals. However, starting from 2020, due to the COVID-19 pandemic and in adherence to local infection control policies, all cases are exclusively followed up using MRA alone to minimize the risk of viral transmission.

Technical Details

After acquiring both 2D and 3D angiographic images, the target aneurysm is evaluated from two orthogonal projections, with one of them typically being the 'down-the-barrel' view. After excluding redundant spaces such as daughter sacs and side blebs, the appropriate WEB size can be determined by strategically "swapping" the height and width dimensions of the aneurysm (Figure 2). For an aneurysm that measures w millimeters in width and h millimeters in height, the recommended WEB size would be $h \times w$ millimeters.

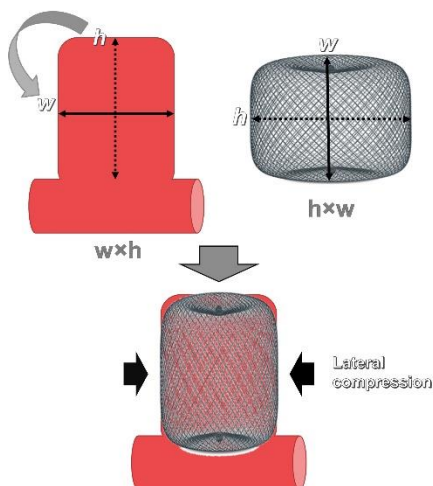


FIG 2. Diagram depicting the proposed sizing strategy for aneurysms with a high height-to-dome ratio. The appropriate WEB size is determined by strategically "swapping" the aneurysm's height and width dimensions. For an aneurysm measuring $w \times h$, it is advisable to employ a $h \times w$ WEB. When fully deployed, the device undergoes significant lateral compression, leading to a substantial increase in its vertical extension which helps to achieve an optimal fit for the aneurysm.

Figure 3 demonstrates a practical application of the suggested sizing technique. A highly elongated cylindrical aneurysm on the right middle cerebral artery, measuring 3.82 mm in width and 8 mm in height, was under consideration for WEB embolization to safeguard the adjacent temporal branch. Based on the size measurements, an 8x4 mm WEB SL was selected for the procedure. The device underwent significant lateral compression, resulting in a reduction of its width from 8 mm to 4 mm and a similar increase in its height from 4 mm to approximately 8 mm. This dynamic transformation led to effective occlusion of the aneurysm, which remained stable during subsequent follow-ups.

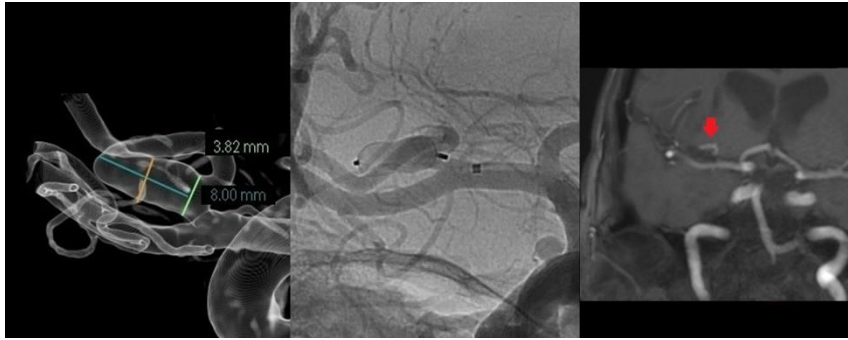


FIG 3. An elective embolization was performed on a right MCA aneurysm that has a cylindrical shape, with measurements indicating a maximum width of 3.82 mm and a height of 8 mm. An 8x4 mm WEB SL device was successfully deployed without impeding the adjacent temporal branch. As a result of intense lateral compression, the base of the SL device assumed a cup-shaped configuration, leaving a small "dog ear" at the neck of the aneurysm. At the 6-month follow-up, the aneurysm continued to show satisfactory results.

Sizing of non-cylindrical aneurysms

The process of choosing the appropriate WEB size for standard cylindrical aneurysms is often straightforward as their shape closely matches that of the recommended device. When dealing with non-cylindrical aneurysms, interobserver disparity in image interpretation and aneurysm measurement can result in inconsistent results. To improve sizing consistency, we recommend adding a minor adjustment which involves targeting the maximum height and width of the aneurysm.

Since the actual volume of a non-cylindrical aneurysm is inherently smaller in comparison to its cylindrical counterpart with equivalent maximum height and width, it becomes necessary to "downsize" the selected WEB device by reducing the device height while keeping its width constant. In most cases, a one-millimeter reduction in height is adequate to prevent oversizing the WEB implant. However, aneurysms that significantly deviate from the standard cylindrical model may require a two-millimeter reduction. In cases where lowering the device height is not feasible, the width of the device can be reduced as a last resort measure to decrease the overall volume of the WEB.

Figure 4 provides an illustrative example to demonstrate the downsizing procedure. In this visual representation, all three aneurysms share the same maximum width and height dimensions of 5x8 mm, suggesting that they should be treated with an 8x5 mm WEB device according to the recommended sizing method. However, it becomes apparent that the volumes of the two non-cylindrical aneurysms are, in fact, smaller, and would not provide sufficient room for an 8x5 mm device. To address this, the WEB device can be downsized by reducing the height by 1 mm, making an 8x4 mm device a more appropriate choice for these aneurysms.

With the pre-determined range of commercially available WEBs, size adjustments for the device are typically limited to 1 mm increments. Given the general ease of reaching a consensus on the maximum width and height of the aneurysm, the downsizing approach effectively minimizes interobserver variation in size selection to just one or two options (Figure 5).

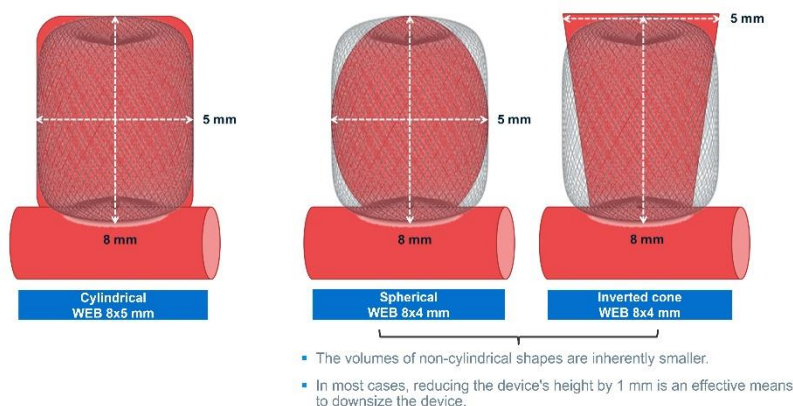


FIG 4. When dealing with aneurysms of non-cylindrical shapes, interobserver discrepancies in image interpretation and aneurysm measurement can result in inconsistent results. Aneurysms with non-cylindrical shapes generally have smaller actual volumes than their cylindrical counterparts with the same maximum width and height. To ensure an adequate fit within the aneurysms, it is necessary to "downsize" the WEB device by reducing the device height. In this visual representation, all three aneurysms share the same maximum width and height dimensions of 5x8 mm, suggesting that they should be treated with an 8x5 mm WEB device according to the recommended sizing method. However, the actual volumes of the two non-cylindrical aneurysms are smaller and would not provide sufficient room for an 8x5 mm device. To address this, the WEB device can be downsized by reducing the height by 1 mm, making an 8x4 mm device a more appropriate choice for these aneurysms.

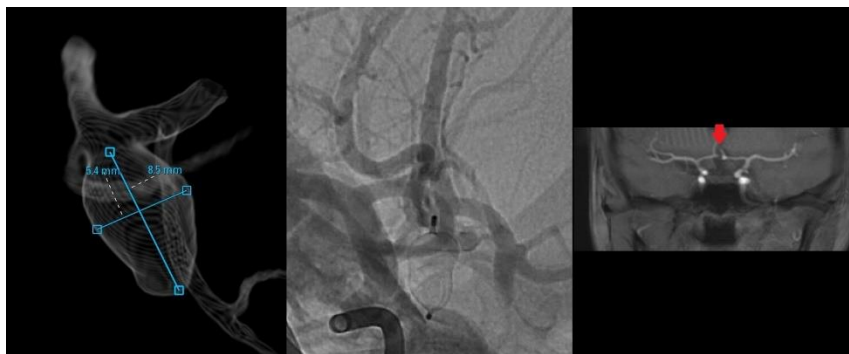

FIG 5. WEB embolization of an acute ACOM aneurysm, characterized by a maximum width of 5.4 mm and a height of 8.5 mm. A strategic ‘downsizing’ was made due to the aneurysm’s non-cylindrical shape. Instead of using an 8×5 mm device, an 8×4 mm WEB SL was selected for the procedure. A follow-up at 6 months showed that the aneurysm remained fully occluded.

RESULTS

A total of twenty-five cases were identified, out of 315 WEB embolization procedures over a 10-year period. The average age of the patients was 61.8 ± 13 years, with 68% of them being female. Among the cases, 76% were presented with acute SAH, while the remaining cases were elective procedures.

The heights of treated aneurysms surpass their widths by a range of 1.4 to 4.5 mm, with an average difference of 2.33 mm. Approximately 44% of the aneurysms were located at the anterior communicating artery, 40% were found at the middle cerebral artery bifurcation or M1 segment, 8% at the ophthalmic segment of the internal carotid artery, 4% at the pericallosal artery and 4% at the anterior choroidal artery. The average aneurysm width was 5.04 mm (3.32–8.20 mm), and the average aneurysm height was 7.38 mm (5.24–11.39 mm). The WEB devices undergo an average lateral compression of 2.03 mm (0.03–4.00 mm) following full deployment. All patients underwent surveillance studies at 6 months, and imaging follow-up at the two-year interval was available for 60% of the cases.

Angiographic occlusion rates

In order to evaluate the effectiveness of the proposed sizing method, the patient cohort was divided into two categories – group A consisted of individuals who adhered to the recommended sizing technique, whereas group B included those who deviated from it (Table 1, online Table 2).

In all twenty cases within group A, a single WEB device was effectively deployed without the need for subsequent replacement arising from sizing errors. Angiographic surveillance shows that 70% (14/20) of the aneurysms exhibited complete occlusion (WEB Occlusion Scale, grade A), while the remaining 30% (6/20) displayed proximal recess filling (grade B). No incidence of persistent neck remnant (grade C) or aneurysm remnant (grade D) was observed.

The remaining five patients in group B underwent treatment with WEB devices that were selected without adhering to the recommended sizing strategy. These cases predominantly occurred during the initial phase of introducing the WEB system, preceding widespread acceptance of the recommended sizing strategy in our department. Among these patients, four were treated with WEB devices that were smaller than what was advised, resulting in aneurysm neck recurrence (grade C) in all four cases and one patient undergoing additional treatment with a flow diverting stent. The last patient in this group received a WEB larger than necessary, which was replaced with a smaller device during the same procedure and subsequent follow-up examinations demonstrated complete aneurysm occlusion at the two-year interval.

Table 1: Comparison of patient’s demographics and details of operative procedures between group A, which adhered to the proposed sizing method, and group B, which did not.

	Group A	Group B	p-value
Patient’s demographics			
n (total=25)	20	5	
Age (years)	63.8 ± 11.2	58.6 ± 14.5	
Gender (female to male)	13:7 (65.0%)	4:1 (80.0%)	0.6416
Rupture status			0.2887
Acute SAH	14 (70%)	5 (100%)	
Elective	6 (30%)		
Location of aneurysm			
MCA	7 (35%)	3 (60%)	
ACOM	11 (55%)		
Ophthalmic ICA	1 (5%)	1 (20%)	
Pericallosal		1 (20%)	
Anterior choroidal	1 (5%)		
Morphology of aneurysm			
Cylindrical	6 (30%)		
Teardrop	1 (5%)	1 (20%)	
Spindle	2 (10%)		

Irregular	11 (55%)	4 (80%)	
Aneurysm dimensions			
Width	4.95 mm (3.32-8.40 mm)	5.40 mm (3.55-7.73 mm)	
Height	7.11 mm (5.24-10.60 mm)	8.44 mm (6.60-11.39 mm)	
Neck	3.70 mm (2.36-6.00 mm)	3.81 mm (2.36-4.70 mm)	
Degree of lateral compression	2.05 mm (1.4-4.0 mm)	2.00 mm (0.03-3.27 mm)	
2-year imaging follow-up	10 (50%)	5 (100%)	0.0613
Occlusion rate			0.0001 (<0.05)
WOS Grade A	14 (70%)	1 (20%)*	
WOS Grade B	6 (30%)		
WOS Grade C		4 (80%)	
Operative procedure			
WEB sizes (width)			0.8219
3-7 mm	14 (70%)	3 (60%)	
8-9 mm	4 (20%)	1 (20%)	
10-11 mm	2 (10%)	1 (20%)	
WEB models			0.0124 (<0.05)
SL/SLS	18 (90%)	2 (40%)	
SL/SLS 17	2 (10%)	3 (60%)	

* Successful replacement of an oversized WEB device conducted during the same procedure resulted in complete angiographic occlusion on subsequent follow-up.

DISCUSSION

A recently published meta-analysis revealed that an aspect ratio of ≥ 1.5 increase the risk of rupture, independently of the aneurysm size.³ While these aneurysms can often be treated with coil embolization alone, a subset of cases with a neck size exceeding 4 mm may still pose significant challenges.⁴ Designed to function as a standalone device, the WEB system provides a safe and effective treatment option without the need for additional assistance devices. It is typically oversized by 1–2 mm from the average diameter of the aneurysm in two perpendicular planes. To accommodate the vertical extension resulting from lateral compression, its height is reduced by 1–2 mm in comparison to the aneurysm height.⁵ However, due to the inherent wider-than-tall design of WEB devices, this sizing approach often proves ineffective for addressing elongated aneurysms. For example, adjusting the device's width and height by 1-2 mm for a 5×8 mm aneurysm would result in the choice of a 6×7 or 7×6 mm SL device, both of which are commercially unavailable.

The strategy we put forward offers a simple approach that can be readily implemented in everyday practice. Through the interchange of width and height dimensions, all patients in the compliant group achieved adequate aneurysm occlusion during subsequent surveillance. In contrast, those who deviated from it experienced significantly less favorable angiographic outcomes ($p<0.05$). Furthermore, a substantial degree of lateral compression greatly enhances the device's resistance to delayed compaction in the compliant group, which may contribute to the high occlusion rate observed in surveillance imaging.⁶

The Clinical Assessment of WEB device in Ruptured Aneurysms (CLARYS) trial demonstrates promising outcomes in the application of the WEB for treating ruptured aneurysms, allowing protection against early and mid-late rebleeds.⁷ 76% of patients in our small series presented with ruptured aneurysms. Based on our limited experience, there appears to be no significant rise in the risk of aneurysmal wall injury attributed to elevated wall tension, potentially underscoring the high compliance of the WEB system.

Clinical applications

Conventional sizing methods, such as the +1/-1 rule and the official sizing chart, restrict each individual device to a narrow range of treatable aneurysms. As a result, expanding the use of the WEB to treat a broader spectrum of aneurysms will require adding new device sizes, which may increase the complexity in inventory management. The sizing method we proposed holds the potential to double the original range of treatable aneurysms, all without the need for additional fixed-sized WEB implants (Figure 1). The concept of enhancing the clinical versatility of the WEB device through lateral compression manipulation is relatively underexplored and merits further investigation.

Impacts of Extreme Lateral Compression

In instances where the height of an aneurysm markedly surpasses its width, extreme level of lateral compression is unavoidable upon the full deployment. This can induce a significant morphological transformation of the WEB device that may impact its intended deployment.

In the case of WEB SL, the corners of the device typically generate the greatest radial forces, while the waist is more susceptible to external compression. When subjected to extreme lateral compression, the WEB SL device tends to assume a characteristic 'hourglass' shape. In contrast, the WEB SLS, with its initially broader waist diameter, is more likely to take on a cylindrical configuration (Figure 6).

Consequently, the base of the WEB SL device which covers the aneurysm neck frequently adopts a concave, cup-shaped appearance, while the proximal recess of the WEB SLS device tends to form a flat surface. Under extreme lateral compression, the two models essentially switch roles to accommodate aneurysm configurations that deviate from their originally intended targets. This role reversal can potentially affect the neck coverage during the treatment of the aneurysm (Figure 3). It is therefore important to anticipate their impact on the device's performance.

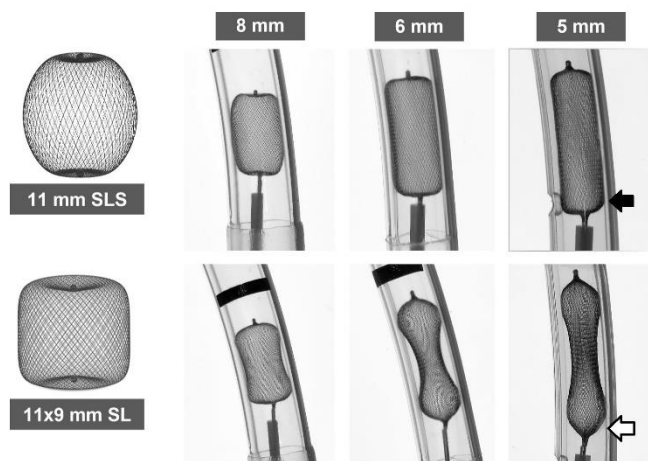


FIG 2. When subjected to extreme lateral compression, the WEB SL device tends to assume a characteristic 'hourglass' shape while the WEB SLS is more likely to take on a cylindrical configuration. As a result, the base of the WEB SL device frequently adopts a concave, cup-shaped appearance (open arrow), whereas the WEB SLS device tends to create a flat base (solid arrow). This inversion of configurations can potentially affect the neck coverage during the treatment of the aneurysm.

Study limitations

There are several limitations to our study. Due to the limited sample size, inherent variations (such as ruptured status, WEB models, and larger device/aneurysms) between the two groups could influence the statistical difference in treatment outcomes.⁸ Its retrospective design may introduce inherent biases associated with the use of historical data. Additionally, being conducted at a single neuroscience center may limit the applicability of the results to wider populations.

Despite recent progress in neurovascular device manufacturing, MR imaging of a WEB device remains difficult due to a combination of magnetic susceptibility artifacts and Faraday cage effect. The low sensitivity of 3D TOF-MRA for aneurysm remnant detection suggests that DSA remains the criterion standard for follow-up.⁹ The use of site interpretation rather than core laboratory assessment of angiographic outcomes may render it susceptible to observer bias.

Further illustrative cases are available in the supplementary files, including an irregularly shaped aneurysm (online Figure 7), a non-compliant case (online Figure 8), and an atypical location (online Figure 9).

CONCLUSIONS

Our proposed approach for sizing WEB devices to address taller-than-wide aneurysms has shown promising results. The intuitive strategy, which involves the interchange of width and height dimensions of the aneurysm, presents a simple and practical solution to the limitations of conventional sizing methods. Further investigation with a larger sample size is recommended to evaluate the applicability of this sizing approach across diverse aneurysm configurations.

Disclosure forms provided by the authors are available with the full text and PDF of this article at www.ajnr.org.

REFERENCES

1. Lv X, Zhang Y, Jiang W. Systematic Review of Woven EndoBridge for Wide-Necked Bifurcation Aneurysms: Complications, Adequate Occlusion Rate, Morbidity, and Mortality. *World Neurosurg* 2018 Feb;110:20-25
2. Behme D, Berlis A, Weber W. Woven EndoBridge Intracranial Flow Disrupter for the Treatment of Ruptured and Unruptured Wide-Neck Cerebral Aneurysms: Report of 55 Cases. *AJNR Am J Neuroradiol* 2015 Aug;36(8):1501-6
3. Sanchez S, Hickerson Patel R et al. Morphological Characteristics of Ruptured Brain Aneurysms: A Systematic Literature Review and Meta-Analysis. *Stroke: Vascular and Interventional Neurology* 2023;3:e000707
4. Brinjikji W, Cloft HJ, Kallmes DF. Difficult aneurysms for endovascular treatment: overdue or undertall? *AJNR Am J Neuroradiol* 2009 Sep;30(8):1513-7
5. van Rooij WJ, van Rooij SBT, Kortman HG, et al. The Woven EndoBridge Finally Coming Home across the Atlantic: What to Expect? *AJNR Am J Neuroradiol* 2018 Nov;39(11):1964-6
6. Delgado Almandoz, Jossier E.; Kayan, Yasha; Copelan, Alexander Z, et al. Lateral Compression is the Strongest Independent Predictor of Aneurysm Occlusion After Endovascular Treatment of Intracranial Aneurysms With the Woven EndoBridge Device. *Neurosurgery Practice* 4(3):e00054, September 2023
7. Spelle L, Herbreteau D, Caroff J, et al. CLinical Assessment of WEB device in Ruptured aneurYSms (CLARYS): results of 1-month and 1-year assessment of rebleeding protection and clinical safety in a multicenter study. *Journal of NeuroInterventional Surgery* 2022;14:807-814
8. Fortunel A, Javed K, Holland R, et al. Impact of aneurysm diameter, angulation, and device sizing on complete occlusion rates using the woven endobridge (WEB) device: Single center United States experience. *Interv Neuroradiol* 2023 Jun;29(3):260-267
9. Timsit C, Soize S, Benaissa A, et al. Contrast-enhanced and time-of-flight MRA at 3T compared with DSA for the follow-up of intracranial aneurysms treated with the WEB device. *AJNR Am J Neuroradiol* 2016;37:1684-1689

SUPPLEMENTAL FILES

Table 2: Details of individual patient's demographics, aneurysm characteristics, device parameters and angiographic outcomes

Year	Urgency	Aneurysm location	Aneurysm shape	Width (mm)	Height (mm)	Neck (mm)	WEB size (mm)	Degree of lateral compression (mm)	6-month follow up result (WOS)	2-year follow up result (WOS)	
Group A											
2018	Acute	ACOM	Inverted	5.42	6.84	4.50	7 SLS	1.58	Grade A	Grade A	
2019	Elective	MCA	Cylindrical	5.20	7.10	4.40	7×5	1.8	Grade A	Grade A	
2019	Acute	ACOM	Cylindrical	4.30	6.36	3.00	6×4	1.7	Grade B		
2019	Acute	MCA	Irregular	3.32	5.24	2.39	5×3	1.68	Grade A	Grade A	
2020	Acute	ACOM	Irregular	4.30	6.00	2.36	6×4	1.7	Grade A	Grade A	
2020	Elective	MCA	Cylindrical	4.00	8.50	3.82	8×4	4	Grade A		
2020	Elective	MCA	Irregular	5.00	7.20	3.79	7×5	2	Grade B	Grade B	
2020	Elective	ACOM	Irregular	5.20	7.10	3.70	7×4	1.8	Grade B	Grade B	
2021	Acute	Para-ophthalmic	Irregular	8.20	9.60	3.85	10×7	1.8	Grade A	Grade A	
2021	Acute	ACOM	Irregular	6.45	8.48	4.01	8×6	1.55	Grade A	Grade B	
2021	Elective	MCA	Irregular	3.50	6.50	3.50	6×4	2.5	Grade A	Grade A	
2021	Acute	MCA	Irregular	5.20	8.20	4.20	8×5	2.8	Grade B	Grade B	
2021	Acute	ACOM	Spindle	5.40	8.50	4.00	8×4	2.6	Grade A		
2021	Acute	ACOM	Irregular	4.60	6.00	3.00	6 SLS	1.4	Grade A		
2021	Elective	MCA	Cylindrical	4.70	6.70	4.70	7×4	2.3	Grade A		
2022	Elective	ACOM	Irregular	3.90	5.60	3.40	6×4	2.1	Grade A		
2022	Acute	ACOM	Irregular	3.90	5.80	2.50	6×4	2.1	Grade A		
2022	Acute	ACOM	Cylindrical	8.40	10.60	6.00	10×8	1.6	Grade B		
2022	Acute	ACOM	Spindle	4.50	6.00	3.80	6×4	1.5	Grade A		
2022	Acute	Anterior choroidal	Cylindrical	3.60	5.90	3.10	6×3	2.4	Grade A		
Group B											
2016	Acute	Para-ophthalmic	Irregular	5.75	9.20	3.11	8 SLS	9×6*	2.25	Grade C	Grade C
2017	Acute	Pericallosal	Irregular	5.97	8.00	4.59	6×4	8×6*	0.03	Grade C	Grade C
2017	Acute	MCA	Irregular	3.55	7.00	3.50	6×3	7×4/ 3*	2.45	Grade C	Grade C
2019	Acute	MCA	Inverted	4.00	6.60	2.50	7 SLS	6 SLS*	3	Grade A**	Grade A**
2020	Acute	MCA	Irregular	7.73	11.39	5.34	11×6	11×8*	3.27	Grade C	Grade C

* Recommended device size based on the proposed sizing method.

** Replacing an oversized 7 mm WEB SLS with a 6 mm SLS device resulted in complete angiographic occlusion on subsequent follow-up.

Irregularly shaped aneurysm

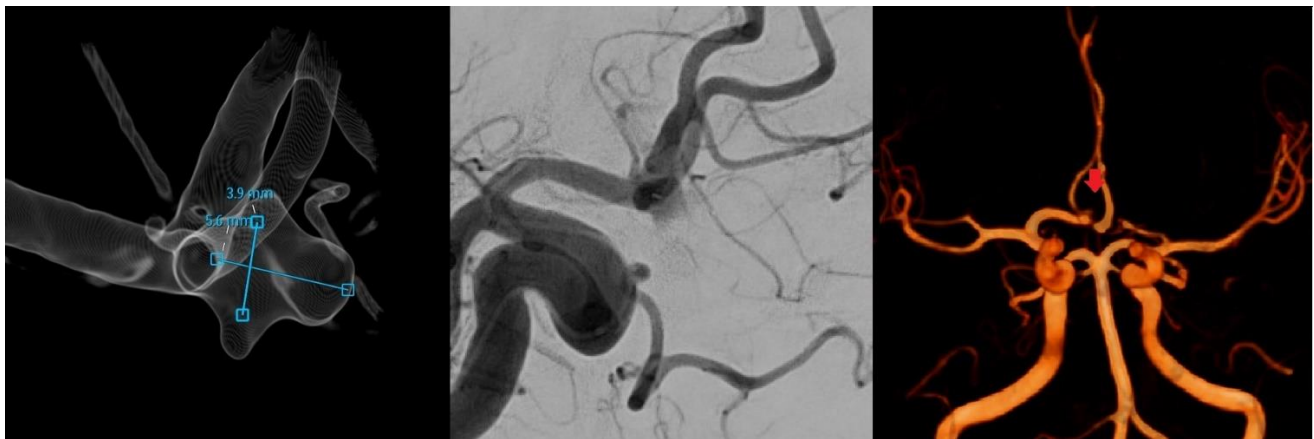
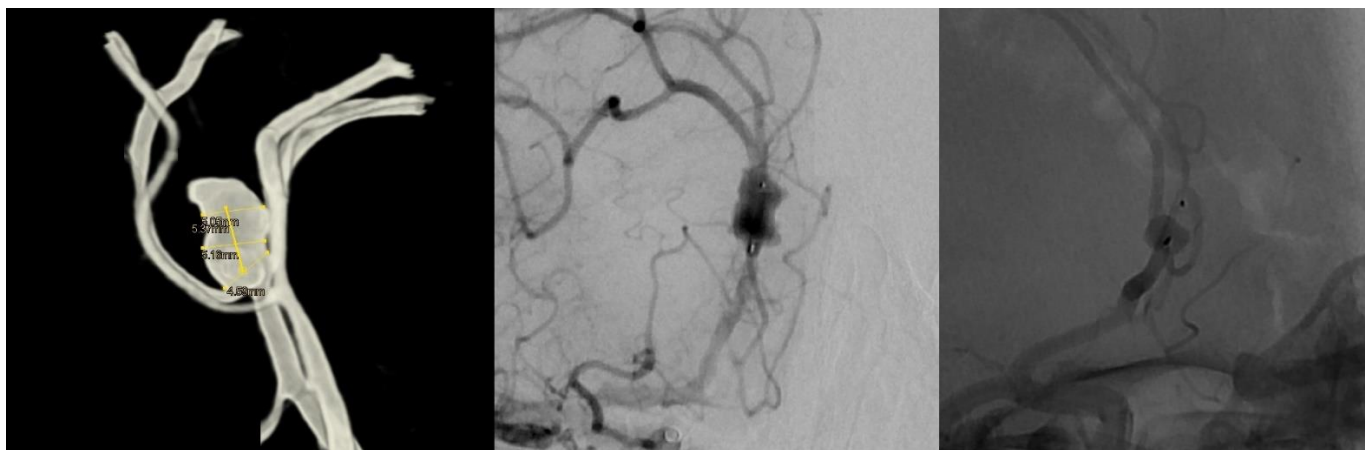

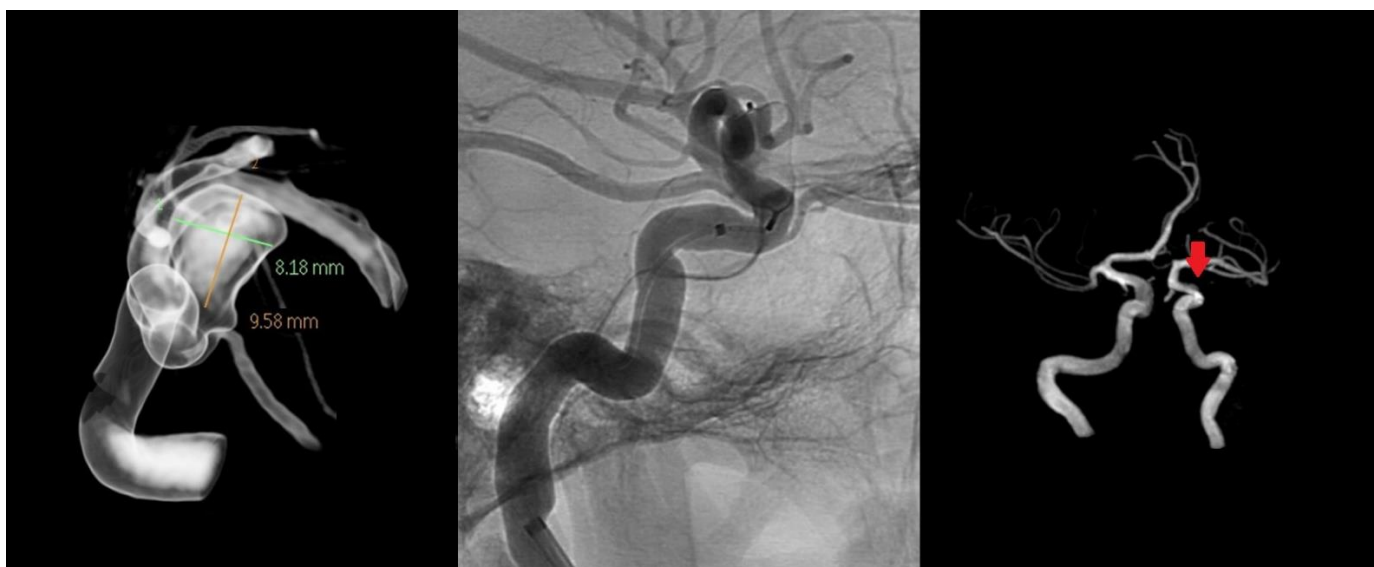FIG 7. A ruptured ACOM aneurysm, characterized by an irregular shape with a maximum height of 5.6 mm and a width of 3.9 mm (excluding the side blebs), was managed using a 6×4 mm WEB SL device. The aneurysm remained occluded after 6 months as confirmed by a surveillance MRA.

1 **Non-compliant case**



2
3 **FIG 8.** A ruptured pericallosal aneurysm, with a maximum height of 8 mm and a width of 5.97 mm, was initially treated using a
4 6×4 mm WEB SL device positioned in the lower segment of the aneurysm. However, a DSA surveillance at 6 months showed a
5 significant neck recurrence due to the device shifting toward the aneurysm dome. Our proposed method recommended an 8×6
6 mm device.

7
8 **Para-ophthalmic aneurysm**



9
10 **FIG 9.** A ruptured para-ophthalmic aneurysm, with a maximum height of 10 mm and a width of 8.18 mm, was treated with a 10×7
11 mm WEB SL device (downsized from 10×8 mm). The aneurysm remained occluded after 6 months as confirmed by a surveillance
12 MRA.

13
14