



**Providing Choice & Value**

Generic CT and MRI Contrast Agents



CONTACT REP

**AJNR**

This information is current as  
of July 16, 2025.

## **Cortical and Subcortical Brain Atrophy Assessment Using Simple Measures on NCCT Compared with MRI in Acute Stroke**

Tanaporn Jaroengarmsamer, Faysal Benali, Joachim Fladt,  
Nishita Singh, Fouzi Bala, Michael Tymianski, Michael D.  
Hill, Mayank Goyal and Aravind Ganesh

*AJNR Am J Neuroradiol* published online 31 August 2023  
<http://www.ajnr.org/content/early/2023/08/31/ajnr.A7981>

# Cortical and Subcortical Brain Atrophy Assessment Using Simple Measures on NCCT Compared with MRI in Acute Stroke

 Tanaporn Jaroengarmsamer,  Faysal Benali,  Joachim Fladt,  Nishita Singh,  Fouzi Bala,  Michael Tymianski,  Michael D. Hill,  Mayank Goyal,  Aravind Ganesh,  
On behalf of the ESCAPE-NA1 Investigators



## ABSTRACT

**BACKGROUND AND PURPOSE:** Brain atrophy is an important surrogate for brain reserve, the capacity of the brain to cope with acquired injuries such as acute stroke. It is unclear how well atrophy measurements on MR imaging can be reproduced using NCCT imaging. We aimed to compare pragmatic atrophy measures on NCCT with MR imaging in patients with acute ischemic stroke.

**MATERIALS AND METHODS:** This is a post hoc analysis, including baseline NCCT and 24-hour follow-up MR imaging data from the Safety and Efficacy of Nerinetide (NA-1) in Subjects Undergoing Endovascular Thrombectomy for Stroke (ESCAPE-NA1) trial. Cortical atrophy was measured using the global cortical atrophy scale, and subcortical atrophy was measured using the intercaudate distance-to-inner-table width (CC/IT) ratio. Agreement and correlation between these measures on NCCT and MR imaging were calculated using the Gwet agreement coefficient 1 and Pearson correlation coefficients, respectively.

**RESULTS:** Among 1105 participants in the ESCAPE-NA1 trial, interpretable NCCT and 24-hour MR imaging were available in 558 (50.5%) patients (mean age, 67.2 [SD, 13.7] years; 282 women). Cortical atrophy assessments performed on NCCT underestimated atrophy severity compared with MR imaging (eg, patients with global cortical atrophy of  $\geq 1$  assessed on NCCT = 133/558 [23.8%] and on MR imaging = 247/558 [44.3%]; a 20.5% difference). Overall, cortical (ie, global cortical atrophy) atrophy assessments on NCCT had substantial or better agreement with MR imaging (Gwet agreement coefficient 1 of  $> 0.784$ ;  $P < .001$ ). Subcortical atrophy measures (CC/IT ratio) showed strong correlations between NCCT and MR imaging (Pearson correlation = 0.746,  $P < .001$ ).

**CONCLUSIONS:** Brain atrophy can be evaluated using simple measures in emergently acquired NCCT. Subcortical atrophy assessments on NCCT show strong correlations with MR imaging. Although cortical atrophy assessments on NCCT are strongly correlated with MR imaging ratings, there is a general underestimation of atrophy severity on NCCT.

**ABBREVIATIONS:** AC1 = agreement coefficient 1; CC/IT = intercaudate distance-to-inner-table width; ESCAPE-NA1 = Safety and Efficacy of Nerinetide (NA-1) in Subjects Undergoing Endovascular Thrombectomy for Stroke; GCA = global cortical atrophy; h-ICD = hemi-intercaudate distance; MTA = medial temporal atrophy

Brain atrophy is considered an important imaging surrogate of brain reserve, the ability of the brain to cope with acquired tissue injuries, such as stroke, demyelination, or trauma.<sup>1-7</sup> There is compelling evidence on the role that atrophy and other

measures of brain reserve play in moderating functional recovery and neurocognitive sequelae after such brain injuries, leading to burgeoning interest in assessing these markers in research and practice.<sup>8-10</sup> Several methods to assess brain atrophy on NCCT

Received October 18, 2022; accepted after revision August 3, 2023.

From the Department of Clinical Neurosciences (T.J., F. Benali, J.F., N.S., F. Bala, M.D.H., M.G., A.G.), University of Calgary, Calgary, Alberta, Canada; Faculty of Medicine Ramathibodi Hospital (T.J.), Mahidol University, Bangkok, Thailand; Department of Radiology and Nuclear Medicine (F. Benali), Maastricht University Medical Center+ (MUMC+), Maastricht, the Netherlands; Department of Neurology and Stroke Center (J.F.), University Hospital Basel, Basel, Switzerland; NoNO Inc (M.T.), Toronto, Ontario, Canada; Department of Radiology (M.D.H., M.G.), Department of Community Health Sciences (M.D.H.), and Hotchkiss Brain Institute and the Mathison Centre for Mental Health Research and Education (M.D.H., M.G., A.G.), University of Calgary, Calgary, Alberta, Canada; and Department of Medicine (M.D.H.), University of Calgary Cumming School of Medicine, Calgary, Alberta, Canada.

The first authorship is shared between Drs Tanaporn Jaroengarmsamer and Faysal Benali for equal contributions to conceptualization, data collection and analysis, and manuscript writing of this study.

The senior authorship is shared between Drs Mayank Goyal and Aravind Ganesh for equal contributions to the study design, supervision, analysis, and revision of the study manuscript.

Dr Jaroengarmsamer reported receiving a scholarship from the Prince Mahidol Award Youth Program. Dr Tymianski reported being chief executive officer of NoNO Inc, a company developing neuroprotectants for the treatment of acute ischemic stroke. Dr Hill reported receiving personal fees from Sun Pharma and Merck and receiving nonfinancial support from Hoffmann-La Roche Canada; holding a patent for US 10,916,346 licensed to Circle NVI and a patent for US 62/086,077 licensed to Circle NVI; owning stock in PureWeb Inc; serving as a director of the Canadian Federation of Neurological Sciences, the Canadian Stroke Consortium, and Circle NVI; and receiving grants from Alberta Innovates Health Solutions, the Canadian Institutes of Health Research, the Heart & Stroke Foundation of Canada, Covidien, Boehringer-Ingelheim, Biogen, Stryker, Medtronic, and the National Institutes of Neurological Disorders and Stroke. Dr Goyal reported receiving personal fees from Medtronic, Stryker, MicroVention, and Mentice during the management of the study; receiving unrestricted research grants to the University of Calgary from NoNO, Stryker, and Medtronic; holding a patent for systems of acute

have been developed, including sophisticated automated volumetrics.<sup>11,12</sup> However, pragmatic visual ratings and measurements are currently the mainstay in clinical practice.<sup>13–15</sup>

Such pragmatic scales include cortical atrophy assessments, which are based on the width of the sulci and volume of the gyri (global cortical atrophy [GCA]);<sup>13</sup> hippocampal atrophy assessments, based on the height/volume of the hippocampus (medial temporal atrophy [MTA] scale)<sup>15</sup> and parietal lobe atrophy assessments based on the width of the posterior cingulate and parieto-occipital sulci (Koedam scale).<sup>14</sup> Subcortical atrophy is assessed less commonly but can be quantified using simple measurements and calculations like the intercaudate distance-to-inner-table width (CC/IT) ratio.<sup>16</sup>

MR imaging is the preferred imaging tool for the aforementioned scales and measures because they were originally developed as part of the work-up for neurodegenerative disorders.<sup>17</sup> However, NCCT is more widely available and more often used in emergency settings like acute stroke. In addition, some patients cannot undergo MR imaging due to claustrophobia, excessive agitation, metal implants, or other contraindications.<sup>18,19</sup> Therefore, should atrophy assessments on NCCT be comparable with those on MR imaging, this similarity would help facilitate the routine consideration of brain atrophy in the evaluation and prognostication of patients with acute neurologic injuries like stroke.

Prior studies comparing the use of NCCT and MR imaging for atrophy assessment included patients with neurodegenerative disorders rather than acute injuries like stroke<sup>12,20</sup> and used less established scales or measurements.<sup>21</sup> The few studies that included patients with acute stroke share the important limitation of not considering confounding of measurements by mass effect from infarct-related edema, which can complicate around 5% of all ischemic strokes.<sup>22,23</sup>

In this study, we aimed to compare the pragmatic assessment of cortical and subcortical atrophy using well-known and standardized rating scales applied on NCCT versus MR imaging in a large randomized controlled trial–derived population of patients with acute stroke.

## MATERIALS AND METHODS

### Patient Sample

This study is a post hoc analysis of the Safety and Efficacy of Nerinetide (NA-1) in Subjects Undergoing Endovascular Thrombectomy for Stroke (ESCAPE-NA1) trial (clinicaltrials.gov: NCT02930018), assessing the efficacy of IV nerinetide in participants with acute ischemic stroke who underwent endovascular thrombectomy within 12 hours from onset.<sup>24</sup> Trial participants of ESCAPE-NA1 were enrolled between March 1, 2017, and August 12, 2019. Detailed information about the trial is provided in the Online Supplemental Data. We performed the

stroke diagnosis, licensed to GE Healthcare; and having an ownership interest in Circle NVI. Dr Ganesh reported receiving grants from the Wellcome Trust, the Canadian Institutes of Health Research, Canadian Cardiovascular Society, Alberta Innovates, Campus Alberta Neuroscience, and Sunnybrook Research Institute (INOVAIT network); receiving personal fees from MD Analytics, My Medical Panel, Creative Research Designs, Atheneum, DeepBench, Research on Mind, Figure 1, Alexion; receiving travel awards from American Academy of Neurology, American Heart Association, and University of Calgary; receiving cash awards from the Association of Indian Neurologists in America; holding stock options from SnapDx, Advanced Health Analytics, and The Rounds.com outside the submitted work; holding a patent for US 63/024,239 pending for a system for patient monitoring and

atrophy measurement between February 1, 2022, and July 31, 2022.

### Image Acquisition

The imaging included in this study consisted of baseline NCCT and MR imaging at 24 hours after randomization. The 5-mm-thick, axial NCCT was acquired using a minimum power of 120–140 kV and 170–200 mA and a 2-second scanning time. The images were processed using appropriate algorithms to reduce bone artifacts and a high SNR for gray-white differentiation. Contiguous axial sections were obtained from the skull base to the vertex, parallel to the inferior orbitomeatal line. A good-quality NCCT scan was defined as having a well-discriminated lateral margin of the lentiform nucleus on the unaffected side and a well-defined insular ribbon in the absence of previous infarction. Reformats included 5-mm-thick sections of axial, sagittal, and coronal NCCT images and 25-mm axial and sagittal MIP CTA images, all generated from the source. CTA required at least 75 mL of contrast media. The scan was used only to confirm affected side for measuring hemi-intercaudate distance (h-ICD) on the contralateral side. A follow-up brain MR imaging was performed at a mean of 24 (SD, 12) hours after randomization. MR imaging sequences included a minimum of axial DWI, gradient-echo, and FLAIR. Reformation was used to generate axial, coronal, and sagittal images from the 3D FLAIR source. If only axial 2D FLAIR images were acquired, as was the case for some sites in this international trial, then available axial views were reviewed.

### Image Analysis

Available baseline NCCT and 24-hour MR imaging data (flow chart, Fig 1) were reviewed by independent core laboratory readers (F. Benali, F. Bala, J.F., N.S., with 4–7 years of experience; Online Supplemental Data) who were blinded to clinical and outcome data. Disagreements were resolved by a senior reader (A.G., with 10 years of experience). The readers were trained to measure atrophy and subcortical atrophy using 20 cases from the data set. However, these cases were re-read for this study after a 30-day washout period, mixed in with all the other data set cases with no indicators of being from the training set. The readers then randomly assessed either NCCT or MR imaging, with no reader assessing both scans from the same patient in the first pass. An additional intrarater intermodality analysis was conducted to assess whether the same rater read NCCT and MR imaging differently.<sup>25</sup> Two readers (F. Benali and J.F.) each assessed global cortical atrophy (applying the GCA scale) in a random set of 100 patients using NCCT and MR imaging, with a washout period of 30 days between the NCCT and MR imaging reading sessions to mitigate the likelihood of being biased by prior measurements. We selected a sample size of 100 patients because this would give

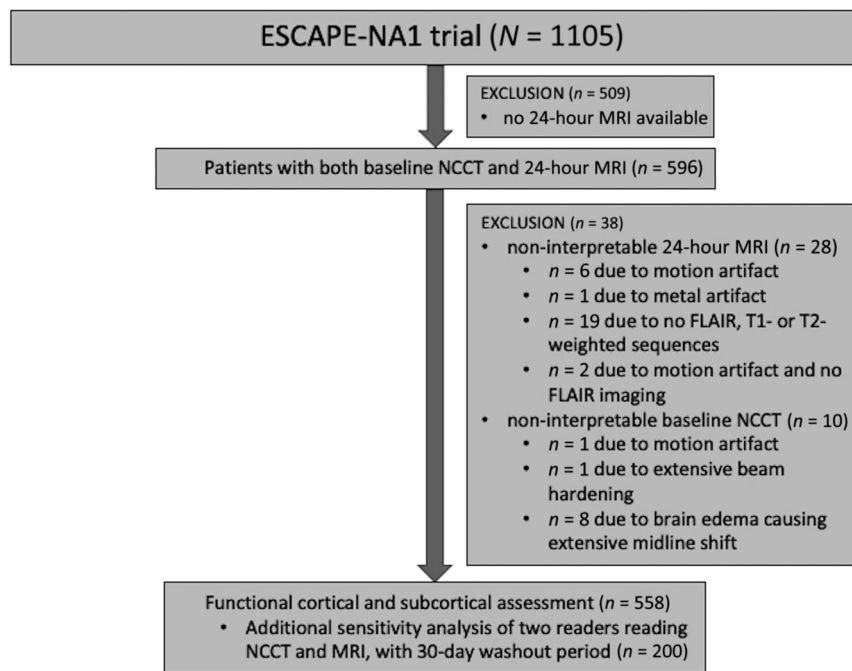
delivery of remote ischemic conditioning or other cuff-based therapies; and serving on the editorial boards of *Neurology*; *Neurology: Clinical Practice*; and *Stroke*.

Please address correspondence to Tanaporn Jaroengngarmsamer, MD, 270 Rama VI Rd, Thung Phaya Thai, Ratchathewi, Bangkok 10400, Thailand; e-mail: tanaporn.jn@gmail.com

🔓 Indicates open access to non-subscribers at [www.ajnr.org](http://www.ajnr.org)

📄 Indicates article with online supplemental data.

<http://dx.doi.org/10.3174/ajnr.A7981>



**FIG 1.** Flow diagram showing inclusion and exclusion of cases.

us 80% power for identifying a disagreement rate of 10% at an  $\alpha$  of .001.<sup>26</sup>

### Cortical Atrophy

Cortical atrophy was measured using visual rating scales for the GCA (Online Supplemental Data). Additional sensitivity analyses included regional atrophy assessments, assessed in both hemispheres by applying the aforementioned scale to the frontal, temporal, and occipital lobes. The parietal lobe was assessed using the Koedam scale (Online Supplemental Data),<sup>14</sup> and the hippocampus was assessed using the MTA scale (Online Supplemental Data).<sup>15</sup> If the atrophy was asymmetric in any of the mentioned scales, the most severe side was included.

### Subcortical Atrophy

Subcortical atrophy was assessed by calculating the ratio of the intercaudate distance-to-the-inner-table width, the CC/IT ratio.<sup>16</sup> To avoid measurement error due to potential infarct-associated edema, the intercaudate distance was measured on the contralateral hemisphere (ie, h-ICD) and then multiplied by 2 (Online Supplemental Data). The h-ICD was defined as the minimum distance between the caudate head and the septum pellucidum at the level of the foramen of Monro and has been used previously<sup>22,23</sup> to assess subcortical atrophy in stroke. In case of very severe edema and midline shift, participants were excluded from all analyses.

### Statistical Analyses

Baseline variables of the included participants were summarized using mean (SD) or median and interquartile range for numeric data; and numbers (No.) and percentages (%) for categorical and dichotomous variables.

For correlation analyses regarding cortical atrophy assessment in the overall data set, we analyzed the intermodality agreement

between NCCT and MR imaging ratings. When we examined the distribution of our data, most cortical atrophy data fell into the “no atrophy” and “mild atrophy” categories. With such a data distribution, use of conventional methods for interrater reliability like the Cohen  $\kappa$  can result in misleadingly low  $\kappa$  values, even in the setting of good agreement, also known as the  $\kappa$  paradox.<sup>27</sup> The Gwet agreement coefficient 1 (AC1)<sup>28</sup> is particularly useful in this setting because it provides a more stable coefficient with varying prevalence or marginal probability.<sup>29</sup> We used a linear-weighted Gwet AC1 for our agreement calculations. The Gwet coefficient was also used for assessment of intermodality agreement for the random subset of 200 cases for which both NCCT and MR imaging were read by the same readers (100 cases each).

Although Gwet did not describe the level of agreement with categorized AC1

results, Landis and Koch’s level of agreement was used to interpret AC1.<sup>28,30</sup> Such categorizations have been used in discussing the results of prior studies using the Gwet AC1.<sup>30</sup> An AC1 of 0.21–0.40 was considered fair agreement, 0.41–0.60 was considered moderate, 0.61–0.80 was considered substantial, and 0.81–1.00 was considered almost perfect.<sup>31</sup> We performed agreement analyses for binary assessment of atrophy: no atrophy (atrophy grade 0) versus any atrophy (atrophy grade 1 or more) (Online Supplemental Data).

For correlation analysis in the measurement of subcortical atrophy between NCCT and MR imaging, we used Pearson correlation analyses. A Pearson correlation of 0.1–0.39 was considered as weak, a coefficient of 0.4–0.69 was considered moderate, and a coefficient of 0.7–0.89 was considered strong.<sup>32</sup> Scatterplots were first drawn to visualize any outliers or linear correlations. In addition, we used Bland-Altman plots to visualize the agreements between NCCT and MR imaging. The patterns of the plots help interpret the correlation between NCCT and MR imaging beyond numeric data.<sup>33,34</sup> For example, a Bland-Altman plot with concentrated data reveals that the both sets of data are highly correlated, whereas the plot with parallel data shows that the difference among data are constant. A narrow difference in the former plot means that the concentration of data is high and the bias between measurements is low. One of the radiologic indicators of early surgical decompression in patients with an ischemic brain is the bicaudate ratio of  $<0.16$ .<sup>35</sup> We performed Gwet AC1 analysis for binary comparison of the CC/IT ratio ( $<0.16$  and  $\geq 0.16$ ). All  $P$  values  $\leq .05$  were considered significant, and analyses were performed using STATA/MP 16.1 (StataCorp).

### RESULTS

Among the 1105 patients enrolled in the ESCAPE-NA1 trial, 1102 (99.7%) had interpretable NCCT and 568 (51.4%) had interpretable 24-hour MR imaging. Interpretable baseline NCCT and 24-



hour MR imaging were available in 566 (51.2%) patients. We excluded 8 cases for which subcortical atrophy was not assessable due to severe brain edema (Fig 1). Of the remaining 558 cases, 282 were women, with a mean age of 67.2 (SD, 13.7) years (Table 1). Multiplanar reformation of FLAIR images was available in 399 (71.5%) patients.

### Cortical Atrophy

When using MR imaging, the rate of participants with any atrophy (GCA  $\geq 1$ ) was higher compared with when GCA assessments were performed using NCCT (ie, 245/558 [43.9%] and 133/558 [23.8%] for MR imaging and NCCT, respectively). This finding was also true for other cortical atrophy scales, such as the Koedam scale (ie, Koedam  $\geq 1$  with NCCT = 172/558 [30.8%] and with MR imaging = 261/558 [46.8%]) and the MTA scale (ie, MTA of  $\geq 1$  with NCCT = 123/558 [22.0%] and with MR imaging = 213/558 [38.2%]). The agreement values of binary (no versus any atrophy) assessments (Gwet AC1 = 0.500–0.554) were lower than the values of standard assessments (Gwet AC1 = 0.784–0.833). GCA assessment showed almost perfect agreement between NCCT and MR imaging (Gwet AC1 = 0.815;  $P < .001$ ) (Table 2). Regional cortical atrophy assessments showed substantial-to-almost-perfect agreement (Gwet AC1  $> 0.784$ ,  $P < .001$ ) (Online Supplemental Data). Additional intrarater intermodality analyses of the GCA (for cases read by the same person) showed moderate-to-substantial agreement (Gwet AC1 = 0.775 and 0.547;  $P < .001$ ).

### Subcortical Atrophy

Subcortical atrophy assessments (CC/IT ratios) were similar when using NCCT compared with MR imaging (CC/IT ratio of  $\geq 0.16$

with NCCT = 87 [15.6%] and with MR imaging = 93 [16.7%]) with a Pearson correlation coefficient of 0.746 ( $P < .001$ ). Bland-Altman plots depicting NCCT assessments compared with MR imaging showed a low difference in highly concentrated areas (mean difference of the ratio was 0.0002; 95% limits of agreement, 0.005–0.005), suggesting highly correlated measurements (Fig 2).<sup>33,34</sup>

## DISCUSSION

In this post hoc analysis of 558 participants in the ESCAPE-NA1 trial who underwent baseline NCCT and 24-hour follow-up MR imaging, we show that pragmatic visual ratings of cortical atrophy on NCCT strongly correlate with atrophy assessments on MR imaging, though atrophy grades tended to be lower when assessed on NCCT compared with 24-hour MR imaging across different rating scales including GCA, Koedam, and MTA. Moreover, we found a strong correlation between NCCT and MR imaging for subcortical atrophy measurements using the intercaudate distance on the nonaffected hemisphere.

Compared with previous literature mostly involving considerably smaller patient samples, our study shows similar or higher agreement between atrophy ratings performed on NCCT and MR imaging. One observational study including 70 patients with stroke that assessed cortical and subcortical atrophy on NCCT and MR imaging using a more complex 5-point visual rating scale<sup>21</sup> found lower agreement than in our study (weighted  $\kappa = 0.43$ –0.61 for cortical atrophy and 0.53–0.70 for subcortical atrophy). In a prospective cross-sectional study of 30 patients suspected of having dementia, the GCA and MTA scales on NCCT and MR imaging<sup>20</sup> showed agreement similar to our results (weighted  $\kappa = 0.83$  for the GCA scale, 0.86 and 0.88 for the MTA scale on the right and left side, respectively). Notably, in this study, imaging acquisitions were from patients recruited in a memory clinic rather than the acute emergency setting. In addition, a recently conducted retrospective study including 214 patients with neurodegenerative disorders used computational atrophy analyses including automated volumetrics of different brain regions (ie, frontal, temporal, parietal, and occipital) and showed strong correlations of the obtained volumes in all regions (Pearson correlation  $> 0.82$ ) between NCCT and MR imaging.<sup>12</sup>

Our study adds to previous literature providing empiric evidence that a simple visual assessment of brain atrophy on routine NCCT is feasible in patients with acute neurologic conditions such as stroke or traumatic brain injury and represents a valuable

diagnostic tool in the emergency setting when the numbers of acutely unwell patients are relatively high and performance of MR imaging or sophisticated volumetric analyses is not practical.

Pragmatic visual atrophy assessment may have important prognostic value complementing routine neuroimaging beyond the confirmation of acute stroke diagnosis and depiction of ischemic penumbra to inform treatment planning as well as recovery expectations for patients and treating physicians.

**Table 1: Baseline characteristics (n = 558)**

Clinical Characteristics	
Age (mean) (yr)	67.2 (SD, 13.7)
Sex (female) (No.) (%)	282 (50.5)
Hypertension (No.) (%)	386 (69.2)
Current smoker (No.) (%)	130 (23.3), n = 557
Dyslipidemia (No.) (%)	245 (43.9)
Atrial fibrillation (No.) (%)	172 (30.8)
Coronary artery disease (No.) (%)	121 (21.7)
Diabetes mellitus (No.) (%)	92 (16.5)
Any prior stroke (No.) (%)	76 (13.6)
Peripheral vascular disease (No.) (%)	19 (3.4)
Systolic blood pressure (mean) (mm Hg)	147.4 (SD, 25.1) n = 557
ASPECTS (median) (IQR)	8 (7–9) n = 552

Note:—IQR indicates interquartile range.

**Table 2: Agreement and correlation between NCCT and MR imaging for cortical and subcortical atrophy assessments, respectively<sup>a</sup>**

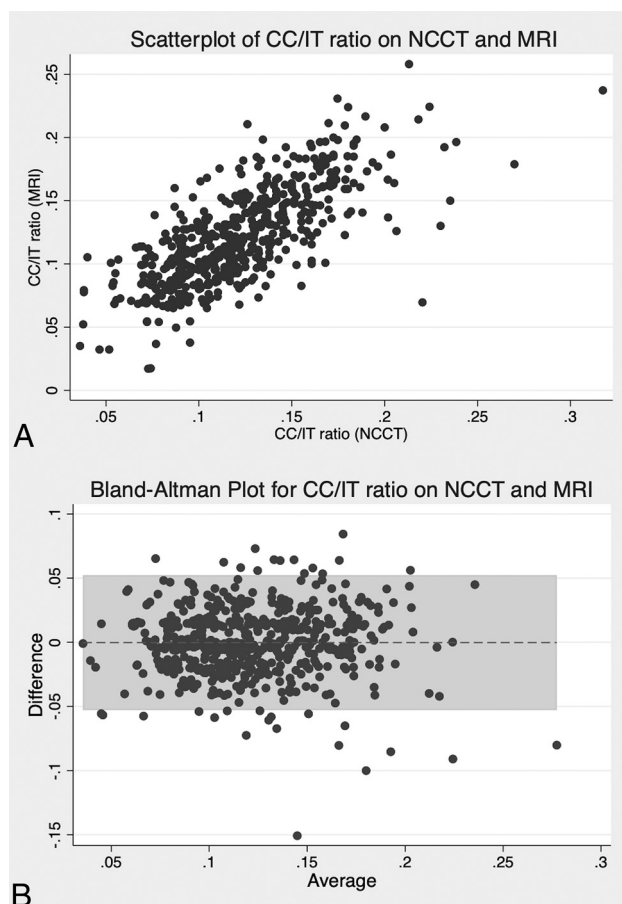
	NCCT	MRI	Gwet AC1 <sup>a</sup>
GCA (median) (min-max) <sup>b</sup>	0 (0–2)	0 (0–3)	0.815
GCA $\geq 1$ (No.) (%)	133 (23.8)	245 (43.9)	0.500
Koedam (median) (min-max) <sup>b</sup>	0 (0–2)	0 (0–3)	0.784
Koedam $\geq 1$ (No.) (%)	172 (30.8)	261 (46.8)	0.512
MTA (median) (min-max) <sup>b</sup>	0 (0–4)	0 (0–4)	0.833
MTA $\geq 1$ (No.) (%)	123 (22.0)	213 (38.2)	0.554
CC/IT ratio (median) (IQR) <sup>b</sup>	0.12 (0.09–0.14)	0.12 (0.09–0.15)	0.746 (Pearson correlation)
CC/IT ratio $\geq 0.16$ (No.) (%) <sup>c</sup>	87 (15.6)	93 (16.7)	0.523

Note:—min indicates minimum; max, maximum.

<sup>a</sup> All P values are  $< .001$ .

<sup>b</sup> Full categoric scale is provided. Linear-weighted Gwet AC1.

<sup>c</sup> Cutoff is chosen on the basis of prior literature.<sup>35</sup>



**FIG 2.** Scatterplot and Bland-Altman plot for the CC/IT ratio ( $n = 558$ ). Scatterplot (A) and Bland-Altman plot (B) for the CC/IT ratio measured on NCCT and MR imaging. The Bland-Altman plot had a mean difference of 0.0002 (95% limits of agreement,  $-0.005$ – $0.005$ ). Highly concentrated areas could be observed, which can be seen in highly correlated measurements.

While an important value of our article is in demonstrating how simple measurements of brain atrophy on NCCT compare with MR imaging measurements, the specific setting of acute stroke used for our study is also of interest, given the emerging recognition of atrophy and other such measures of brain frailty as important mediators of treatment outcome in acute stroke.<sup>36–38</sup> Because there is now considerable impetus for future acute stroke studies to factor such variables into the analyses, our finding that cortical and subcortical atrophy can be feasibly measured on NCCT in the acute setting is reassuring. In addition, future studies could examine how the underestimation of atrophy burden on NCCT affects the prediction of poststroke outcomes.

### Limitations

First, because all raters in our study had several years of experience with neuroimaging readings and received similar training using the scales at the start of the study, we cannot comment on to what extent interrater differences in experience or training could contribute to discrepancies between NCCT and MR imaging assessments. Second, even though we used the h-ICD to account for any stroke-related edema, possible evolution of edema during the 24-hour interval between baseline NCCT and follow-up MR

imaging could theoretically confound comparisons. However, cases with extensive midline shift and/or sulcal or ventricular effacement that were noninterpretable on the basis of the judgment of the reader were excluded and accounted for  $<1\%$  of the cases in the data set. Third, because this was a multicenter international trial, scanners differed from one site to another, and we did not impose specific MR imaging parameters beyond the expectations for a minimum set of sequences. However, this choice allowed us to perform a more pragmatic comparison of ratings performed on CT and MR imaging that is more generalizable to the heterogeneities of real-world practice.

### CONCLUSIONS

Brain atrophy can be feasibly evaluated using simple measures in emergently acquired NCCT imaging. Subcortical atrophy measurement using CC/IT ratios are highly reproducible on both NCCT and MR imaging axial planes. Cortical atrophy assessments on NCCT have substantial or better agreement with MR imaging ratings but generally underestimate the severity of atrophy.

Disclosure forms provided by the authors are available with the full text and PDF of this article at [www.ajnr.org](http://www.ajnr.org).

### REFERENCES

1. Rabinstein AA, Albers GW, Brinjikji W, et al. Factors that may contribute to poor outcome despite good reperfusion after acute endovascular stroke therapy. *Int J Stroke* 2019;14:23–31 [CrossRef Medline](#)
2. Pedraza MI, de Lera M, Bos D, et al. Brain atrophy and the risk of futile endovascular reperfusion in acute ischemic stroke. *Stroke* 2020;51:1514–21 [CrossRef Medline](#)
3. Luijten SP, Compagne KC, van Es AC, et al. Brain atrophy and endovascular treatment effect in acute ischemic stroke: a secondary analysis of the MR CLEAN trial. *Int J Stroke* 2021 Oct 28. [Epub ahead of print] [CrossRef Medline](#)
4. Lauksio I, Lindström I, Khan N, et al. Brain atrophy predicts mortality after mechanical thrombectomy of proximal anterior circulation occlusion. *J Neurointerv Surg* 2021;13:415–20 [CrossRef Medline](#)
5. Lamballais S, Zijlmans JL, Vernooij MW, et al. The risk of dementia in relation to cognitive and brain reserve. *J Alzheimers Dis* 2020;77:607–18 [CrossRef Medline](#)
6. Fuchs TA, Benedict RH, Bartnik A, et al. Preserved network functional connectivity underlies cognitive reserve in multiple sclerosis. *Hum Brain Mapp* 2019;40:5231–41 [CrossRef Medline](#)
7. Yoon HJ, Kim SG, Kim SH, et al; For the Alzheimer's Disease Neuroimaging Initiative. Associations between brain reserve proxies and clinical progression in Alzheimer's disease dementia. *Int J Environ Res Public Health* 2021;18:12159 [CrossRef](#)
8. Benali F, Singh N, Fladt J, et al. Brain frailty mediates the relationship between age and 90-day functional outcome after endovascular therapy: analysis of the Escape-NA1 trial. *Stroke* 2023;54 (Suppl1):AWMP57 [CrossRef](#)
9. Hussein NE, Katzan IL, Rost NS, et al; American Heart Association Stroke Council; Council on Cardiovascular and Stroke Nursing; Council on Cardiovascular Radiology and Intervention; Council on Hypertension; and Council on Lifestyle and Cardiometabolic Health. Cognitive impairment after ischemic and hemorrhagic stroke: a scientific statement from the American Heart Association/American Stroke Association. *Stroke* 2023;54:e272–91 [CrossRef Medline](#)
10. Bigler ED. The clinical significance of cerebral atrophy in traumatic brain injury. *Arch Clin Neuropsychol* 1987;2:293–304 [Medline](#)
11. Caspers J, Heeger A, Turowski B, et al. Automated age- and sex-specific volumetric estimation of regional brain atrophy: workflow and feasibility. *Eur Radiol* 2021;31:1043–48 [CrossRef Medline](#)

12. Kaipainen AL, Pitkänen J, Haapalinna F, et al. **A novel CT-based automated analysis method provides comparable results with MRI in measuring brain atrophy and white matter lesions.** *Neuroradiology* 2021;63:2035–46 [CrossRef Medline](#)
13. Pasquier F, Leys D, Weerts JG, et al. **Inter- and intraobserver reproducibility of cerebral atrophy assessment on MRI scans with hemispheric infarcts.** *Eur Neurol* 1996;36:268–72 [CrossRef Medline](#)
14. Koedam EL, Lehmann M, van der Flier WM, et al. **Visual assessment of posterior atrophy development of an MRI rating scale.** *Eur Radiol* 2011;21:2618–25 [CrossRef Medline](#)
15. Torisson G, van Westen D, Stavenow L, et al. **Medial temporal lobe atrophy is underreported and may have important clinical correlates in medical inpatients.** *BMC Geriatr* 2015;15:65 [CrossRef Medline](#)
16. van Zagten M, Kessels F, Boiten J, et al. **Interobserver agreement in the assessment of cerebral atrophy on CT using bicaudate and Sylvian-fissure ratios.** *Neuroradiology* 1999;41:261–64 [CrossRef Medline](#)
17. Kipps CM, Davies RR, Mitchell J, et al. **Clinical significance of lobar atrophy in frontotemporal dementia: application of an MRI visual rating scale.** *Dement Geriatr Cogn Disord* 2007;23:334–42 [CrossRef Medline](#)
18. Boldor N, Vaknin S, Myers V, et al. **Reforming the MRI system: the Israeli National Program to shorten waiting times and increase efficiency.** *Isr J Health Policy Res* 2021;10:57 [CrossRef Medline](#)
19. Frija G, Blazović I, Frush DP, et al. **How to improve access to medical imaging in low- and middle-income countries?** *EClinicalMedicine* 2021;38:101034 [CrossRef Medline](#)
20. Wattjes MP, Henneman WJ, van der Flier WM, et al. **Diagnostic imaging of patients in a memory clinic: comparison of MR imaging and 64-detector row CT.** *Radiology* 2009;253:174–83 [CrossRef Medline](#)
21. Ferguson KJ, Cvorovic V, MacLulich AM, et al. **Visual rating scales of white matter hyperintensities and atrophy: comparison of computed tomography and magnetic resonance imaging.** *J Stroke Cerebrovasc Dis* 2018;27:1815–21 [CrossRef Medline](#)
22. Lee SH, Oh CW, Han JH, et al. **The effect of brain atrophy on outcome after a large cerebral infarction.** *J Neurol Neurosurg Psychiatry* 2010;81:1316–21 [CrossRef Medline](#)
23. Butzkueven H, Kolbe SC, Jolley DJ, et al. **Validation of linear cerebral atrophy markers in multiple sclerosis.** *J Clin Neurosci* 2008;15:130–37 [CrossRef Medline](#)
24. Hill MD, Goyal M, Menon BK, et al; ESCAPE-NA1 Investigators. **Efficacy and Safety of Nerinetide for the Treatment of Acute Ischaemic Stroke (ESCAPE-NA1): a multicentre, double-blind, randomised controlled trial.** *Lancet* 2020;395:878–87 [CrossRef Medline](#)
25. Schmaranzer F, Kallini JR, Miller PE, et al. **The effect of modality and landmark selection on MRI and CT femoral torsion angles.** *Radiology* 2020;296:381–90 [CrossRef Medline](#)
26. Liao JJ. **Sample size calculation for an agreement study.** *Pharm Stat* 2010;9:125–32 [CrossRef Medline](#)
27. Zec S, Soriani N, Comoretto R, et al. **High agreement and high prevalence: the paradox of Cohen's Kappa.** *Open Nurs J* 2017;11:211–18 [CrossRef Medline](#)
28. Gwet KL. **Computing inter-rater reliability and its variance in the presence of high agreement.** *Br J Math Stat Psychol* 2008;61:29–48 [CrossRef Medline](#)
29. Gwet KL. **Testing the difference of correlated agreement coefficients for statistical significance.** *Educ Psychol Meas* 2016;76:609–37 [CrossRef Medline](#)
30. Wongpakaran N, Wongpakaran T, Wedding D, et al. **A comparison of Cohen's kappa and Gwet's AC1 when calculating inter-rater reliability coefficients: a study conducted with personality disorder samples.** *BMC Med Res Methodol* 2013;13:61 [CrossRef Medline](#)
31. Landis JR, Koch GG. **The measurement of observer agreement for categorical data.** *Biometrics* 1977;33:159–74
32. Schober P, Boer C, Schwarte LA. **Correlation coefficients: appropriate use and interpretation.** *Anesth Analg* 2018;126:1763–68 [CrossRef Medline](#)
33. Giavarina D. **Understanding Bland Altman analysis.** *Biochem Med (Zagreb)* 2015;25:141–51 [CrossRef Medline](#)
34. Bland JM, Altman DG. **Statistical methods for assessing agreement between two methods of clinical measurement.** *Lancet* 1986;1:307–10 [Medline](#)
35. Park J, Goh DH, Sung JK, et al. **Timely assessment of infarct volume and brain atrophy in acute hemispheric infarction for early surgical decompression: strict cutoff criteria with high specificity.** *Acta Neurochir (Wien)* 2012;154:79–85 [CrossRef Medline](#)
36. Benali F, Fladt J, Jaroennarmsamer T, et al. **Association of white matter disease with functional recovery and 90-day outcome after EVT: beyond chronological age.** *Stroke Vasc Interv Neurol* 2023;3:e000734 [CrossRef](#)
37. Bretzner M, Bonkhoff AK, Schirmer MD, et al; MRI-GENIE and GISCOME Investigators and the International Stroke Genetics Consortium. **Radiomics-derived brain age predicts functional outcome after acute ischemic stroke.** *Neurology* 2023;100:e822–33 [CrossRef Medline](#)
38. Benali F, Fladt J, Jaroennarmsamer T, et al. **Association of brain atrophy with functional outcome and recovery trajectories after thrombectomy: Post-hoc analysis of the ESCAPE-NA1 Trial.** *Neurology* 2023;17 [CrossRef Medline](#)