

# Double stent-retriever technique for mechanical thrombectomy: a systematic review and meta-analysis

Jeremy Hofmeister, Olivier Brina, Gianmarco Bernava, Andrea Rosi, Philippe Reymond, Karl-Olof Lovblad, Paolo Machi

## ABSTRACT

**BACKGROUND:** Mechanical thrombectomy using a double stent-retriever technique has recently been described for the treatment of acute ischemic stroke, but its efficacy and safety are not well established.

**PURPOSE:** The aim of this systematic review and meta-analysis was to evaluate reports of the use of double stent-retriever during the endovascular treatment of patients with ischemic stroke.

**DATA SOURCES:** The PubMed, Embase, Web of Science and Scopus databases were searched to identify all studies (clinical trials, cohorts series and case reports) investigating the utility of double stent-retriever for the treatment of stroke. The study is reported in accordance with PRISMA 2020 guidelines and was prospectively registered in PROSPERO (BLINDED FOR PEER REVIEW).

**STUDY SELECTION:** 17 studies involving a total of 128 patients with large vessel occlusions predominantly in the anterior circulation (93.0%) were identified.

**DATA ANALYSIS:** Outcomes of interest were the prevalence of successful recanalization (mTICI  $\geq 2b$ ) and a first-pass effect following double stent-retriever, as well as complications such as iatrogenic dissections and subarachnoid hemorrhage. Data were pooled using a random-effects model.

**DATA SYNTHESIS:** Double stent-retriever was used as a rescue strategy in occlusions refractory to conventional endovascular treatment in 68.7% (88/128) of patients and as a first-line strategy in 31.3% (40/128) patients. Double stent-retriever achieved an overall final mTICI  $\geq 2b$  in 92.6% cases with a first-pass effect of 76.6%. The complication rate remained low, with 0.37% dissection and 1.56% subarachnoid hemorrhage.

**LIMITATIONS:** Limitations of the study include (1) a large number of case reports or small series, (2) a meta-analysis of proportions with no statistical comparison to a control group, and (3) the lack of access to patient-level data.

**CONCLUSIONS:** Our findings suggest that double stent-retriever thrombectomy may be safe and associated with good recanalization outcomes, but prospective comparative studies are needed to determine which patients may benefit from this endovascular procedure.

**ABBREVIATIONS:** AICH = asymptomatic intracranial hemorrhage; AIS = acute ischemic stroke; DSR = double stent-retriever; FPE = first pass effect; ICH = intracranial hemorrhage; LVO = large vessel occlusion; MT = mechanical thrombectomy; SAH = subarachnoid hemorrhage; SICH = symptomatic intracranial hemorrhage; SSR = single stent-retriever.

Received month day, year; accepted after revision month day, year.

From the Department of Diagnostic and Interventional Neuroradiology, Geneva University Hospitals, Geneva, Switzerland (J.H., O.B., G.B., A.R., P.R., K.O.L., P.M.) and the Brain Endovascular Therapeutics R&D Lab, Radiology and Medical Informatics, University of Geneva, Geneva, Switzerland (J.H., O.B., P.R., P.M.).

## DISCLOSURE OF POTENTIAL CONFLICTS OF INTEREST:

JH has been awarded a speaking compensation by Philips and Nicolab. GB has been awarded a speaking compensation by Penumbra. PM has been awarded a speaking compensation by Medtronic, Stryker and Penumbra. The other authors declare no conflicts of interest related to the content of this article.

## Correspondence:

Jeremy Hofmeister, Department of Diagnostic and Interventional Neuroradiology, Geneva University Hospitals, Rue Gabrielle-Perret-Gentil 4, 1205 Geneva, Switzerland. Email: Jeremy.hofmeister@hcuge.ch

## INTRODUCTION

Mechanical thrombectomy (MT) using a double stent-retriever (DSR) approach has recently been reported as a highly effective endovascular treatment for patients with acute ischemic stroke (AIS).<sup>1–17</sup> DSR MT was first introduced as a rescue technique when conventional single stent-retriever (SSR) treatment failed.<sup>1–14, 16</sup> More recently, it has been used as a first-line treatment for large intracranial vessel occlusion.<sup>17</sup> However, there is no systematic review and meta-analysis of clinical cases treated with this approach, which limits the evaluation of its overall efficacy and safety. Our systematic review and meta-analysis aimed to evaluate articles reporting the use of DSR during endovascular treatment of patients with AIS to better assess the efficacy and safety of this endovascular approach.

## MATERIALS AND METHODS

### *Search strategy*

The Cochrane Handbook for Systematic Reviews of Interventions and Preferred Reporting Items for Systematic Reviews and Meta-analyses (PRISMA, <http://www.prisma-statement.org/>) guidelines were followed. The study protocol was prospectively registered in PROSPERO (CRD42023482691). Four online databases (PubMed, Embase, Web of Science, and Scopus) were searched using filters for English language articles published from their inception to October 31 2023. Medical subject headings and keyword searches included the terms "brain" OR "cerebral" AND "stroke" AND "thrombectomy" OR "endovascular" AND "double stent" OR "y-stent". To identify missing articles, we also conducted an extensive manual search of the reference lists of included articles and pertinent available non-systematic analysis were reviewed for other potential citations. Data from unpublished sources were not searched or included.

### *Screening process and eligibility criteria*

Two investigators (JH and OB) performed the title and abstract selection, followed by a full-text selection phase including the studies remaining after the initial selection. In case of disagreement, a third investigator (PM) was consulted to reach a consensus. We included all original studies that met our criteria for population (AIS patients), exposure (DSR MT), comparator (none) and outcome. The primary endpoint was successful intracranial recanalization at the end of MT, defined by a mTICI score  $\geq 2b$ , recanalization rate (mTICI score  $\geq 2b$ ) at the first-pass of DSR (first-pass effect [FPE]), arterial dissections during DSR MT, rate of subarachnoid hemorrhage (SAH) at the end of the procedure, asymptomatic intracerebral hemorrhage (AICH), and symptomatic intracerebral hemorrhage (SICH) on control imaging 24–48 h after the procedure, as defined by the European Cooperative Acute Stroke Study (ECASS) criteria.<sup>18</sup> We were unable to include embolization to a new territory as a primary endpoint in our analysis because it was not reported in the studies reviewed, although it is an important outcome of mechanical thrombectomy and could represent a publication bias. We excluded studies evaluating DSR in vitro and conference abstracts. We had no restrictions on patient characteristics or stroke location.

We assessed the evidence of the non-randomized studies included using the Newcastle-Ottawa Scale (NOS),<sup>19</sup> to provide a quality assessment in the interpretation of meta-analysis results. Two investigators (JH and OB) rated the NOS for each study. In case of disagreement, a third investigator (PM) was consulted to reach a consensus.

### *Data extraction*

Data extracted included study characteristics, baseline demographic and clinical characteristics of patients treated by DSR, and outcomes of interest. Two authors (JH and OB) independently performed the data extraction, which was then reviewed by a third author (PM) for consensus.

### *Statistical analysis*

We pooled frequencies and means with corresponding 95% confidence intervals (CIs). Generalized linear mixed models with logit transformation and random effects were used to pool data due to relatively small sample sizes, the presence of 0 events, and methodological differences between studies.<sup>20,21</sup> Heterogeneity was assessed using the Q statistic and the  $I^2$  test, where  $P < 0.05$  (two-tailed) or  $I^2$  values greater than 50% were considered to be significant, similar to Kobeissi et al.<sup>22</sup> Funnel plots were used for the visualization of publication bias. We first analyzed all published articles and then repeated the same analyses only for consecutive cohorts with  $>5$  patients. All data were analyzed using R, version 4.2.2 (R Project for Statistical Computing) and the meta package.

## RESULTS

### *Search and screening results*

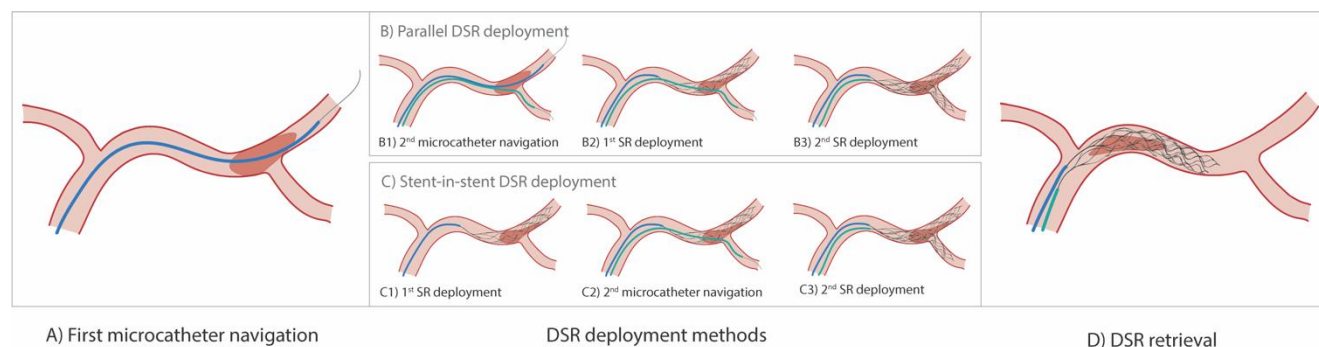
The initial research resulted in 424 articles, of which 237 came from the PubMed search, 121 from Embase and 66 from Scopus. After removing 178 duplicates, we retained 246 articles for further selection. We excluded a further 228 articles at the title and abstract selection stage, resulting in 18 articles for full-text review. One article was removed because the authors used a Merci device and not a stent retriever,<sup>23</sup> leaving 17 articles that met our inclusion criteria with appropriate reporting of the outcomes of interest and comprising 128 patients treated by MT using a DSR technique. The results of our literature screening are summarized in Supplementary Figure 1.

### *Study characteristics*

Of the 17 articles published between 2009 and 2023, 11 were case reports with 1 or 2 patients only 1–11 and six were consecutive case series with 9 to 39 patients).12–17 Patient characteristics, including age, sex, initial National Institutes of Health Stroke Scale (NIHSS), and use of intravenous thrombolytics are detailed in Table 1. Patients enrolled had predominantly anterior circulation occlusions (n=119 [93.0%]) involving in the internal carotid artery (ICA; n=59) and/or middle cerebral artery (MCA; n=76). Nine patients had posterior circulation occlusions (7.0%) involving in the basilar artery (BA).

### Procedure characteristics

Forty MTs with DSR were performed as first-line treatment (31.3%) and 88 as rescue treatment (68.7%). One hundred and thirteen (88.3%) MTs with DSR were performed with parallel stent deployment, in which two microcatheters were placed in branches distal to the clot prior to stent deployment. Fifteen (11.7%) MTs were performed using a stent-in-stent deployment technique, in which a first microcatheter is advanced distal to the clot and a SR is deployed through it, followed by navigation of a second microcatheter through this first SR to allow deployment of the second SR. Details of the two stent deployment techniques and practical tips found in the literature are shown in Figure 1.



**FIG 1.** Illustration of the parallel and stent-in-stent DSR techniques.

A) Navigation of the first microcatheter over a microwire distal to the clot (step common to both DSR techniques), as in conventional thrombectomy using a single stent retriever (SSR).

Deployment of the stent retrievers (3 different steps between the parallel and stent-in-stent DSR techniques).

B) In the parallel DSR technique: B1) A second microcatheter is navigated distal to the clot on a microwire, ideally in an arterial branch different from the first microcatheter. B2) The first SR is deployed distally and through the clot. As with the MT SSR, the clot should be in the proximal part of the SR. B3) The second SR is deployed, ideally with the clot also in the proximal part of the SR.

C) In the stent-in-stent technique: C1) The first SR is deployed distally and through the clot, ideally with a clot in the proximal part of the SR. C2) A second microcatheter is navigated distal to the clot over a microwire through the mesh of the first stent, ideally into an arterial branch different from the first microcatheter. C3) The second SR is deployed, ideally with a clot also in the proximal part of the SR.

D) Removal of the two stent retrievers together (common to both DSR techniques). Both stent retrievers are removed at the same time and at the same slow speed. To ensure that the removal of both SRs begins at the same time, it is important to tension both stents prior to retrieval. It may also be useful to place a single torquer on the pushwires of both stents once they have been tensioned, in order to remove the stents at an identical and harmonious speed.

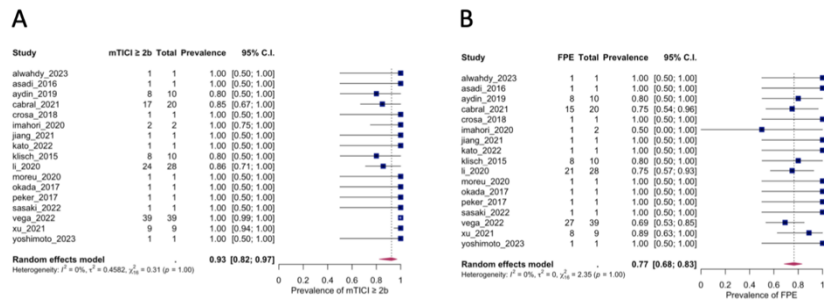
### Quality of evidence

The quality of the evidence from the studies included in our systematic review and meta-analysis evaluated using the NOS is poor, relying on many case reports (Table 2). This could raise concerns about publication bias in studies evaluating the use of the DSR. Therefore, in addition to the analysis of all included articles, we repeated the meta-analysis by including only larger consecutive cohorts (6 cohorts, 116 patients in total) of patients treated with DSR.

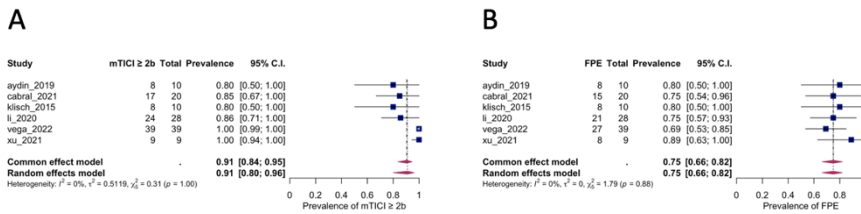
### DSR efficacy

The meta-analysis of all studies showed a high rate of successful recanalization (mTICI  $\geq 2b$ ) at the end of MT with a DSR, with a prevalence of 92.6% (95% CI 82.4–97.0) (Figure 2A and Table 2A). When combined, these studies also reported an FPE (at the first pass of DSR) of 76.6% (95% CI 68.5–83.1) (Figure 2B and Table 2A). There was no heterogeneity between the pooled studies for the final successful recanalization (mTICI  $\geq 2b$ ) ( $I^2 = 26.4\%$ ,  $p=1.0$ ) or for FPE ( $I^2 = 0\%$ ,  $p=1.0$ ) (Table 2A).

In the sub-analysis including only the larger consecutive cohorts, the mTICI score 2b–3 had a frequency of 91.1% (95% CI 80.0–96.3) and the FPE 75.0% (95% CI 66.3–82.0) (Table 2B and Figure 3). Although still moderate, study heterogeneity is higher for mTICI ( $I^2 = 44.4\%$ ;  $p=0.998$ ), while it remains very low for FPE ( $I^2 = 0\%$ ,  $p=0.887$ ). Funnel plots for these efficacy indicators are shown in Supplementary Figures 2 and 3.



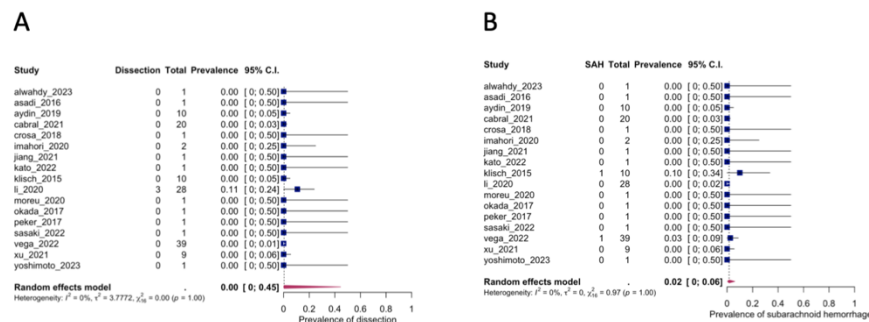
**FIG 2.** Efficacy of DSR MT. Efficacy of DSR MT: A) successful recanalization (mTICI  $\geq 2b$ ) and B) first-pass effect (FPE).



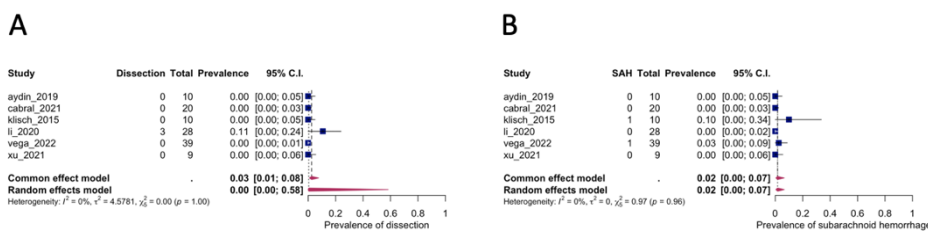
**FIG 3.** Efficacy of DSR MT in large cohorts only (n=6): A) successful recanalization (mTICI  $\geq 2b$ ) and B) first-pass effect (FPE).

### DSR safety

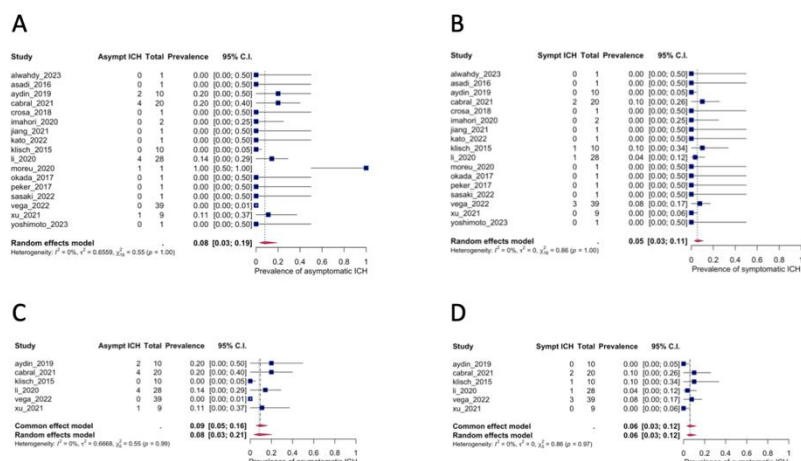
The pooled analysis of all studies showed a low rate of dissection with the use of DSRs, estimated at 0.4% (95% CI 0-44.5) (Figure 4A and Table 3A), but with heterogeneity between studies ( $I^2 = 65.9\%$ ,  $p=1.0$ ). SAH rates also remained low at an estimated 1.6% (95% CI 0.4-6.0) (Figure 4B), with no heterogeneity in the data ( $I^2 = 0\%$ ,  $p=1.0$ ). Finally, AICH and SICH rates were also low, with an estimated 8.1% (95% CI 3.1-19.1) and 5.5% (95% CI 2.6-11.0), respectively (Figure 6). However, study heterogeneity was greater for AICH ( $I^2 = 33.6\%$ ,  $p=1.0$ ) than for SICH ( $I^2 = 0\%$ ,  $p=1.0$ ) (Table 2A). These results for the frequencies of dissection, SAH, AICH and SICH are very similar in the sub-analysis of large consecutive cohorts only, although with greater heterogeneity for dissection and AICH (see Table 3B and Figures 5). Funnel plots for these safety variables are shown in Supplementary Figures 2 and 3.



**FIG 4.** Safety of DSR MT. Safety of DSR MT: A) dissections and B) subarachnoid hemorrhage (SAH).



**FIG 5.** Safety of DSR MT in large cohort studies only (n=6): A) dissections and B) subarachnoid hemorrhage (SAH).



**FIG 6.** Symptomatic and asymptomatic intracranial hemorrhage (ICH): A) AICH in all studies, B) SICH in all studies, C) AICH in large cohorts only, D) SICH in large cohorts only. Abbreviations: AICH: asymptomatic intracranial hemorrhage, SICH: symptomatic intracranial hemorrhage.

## DISCUSSION

This systematic review and meta-analysis synthesized cohorts and clinical cases of patients treated with a DSR MT technique reported in the literature, including 128 patients with large intracranial vessel occlusion predominantly in the anterior circulation (93.0%). The results suggest that MT using a DSR technique may be safe and associated with a high efficacy.

### DSR efficacy

Successful recanalization (mTICI  $\geq 2b$ ) was achieved in 92.6% of cases, which is close to that reported in recent clinical trials of MT with SSR.24 DSR was used as a rescue strategy in 88 cases (68.7%) and as a first-line treatment in the remaining 40 cases (31.3%). Considering that 68.7% of these DSR TMs were performed as a rescue strategy in occlusions refractory to conventional endovascular treatment with SSR, the efficacy of DSR TM appears very high. Furthermore, the FPE rate when using a DSR was 76.6%, which is very high compared to the recent literature. Indeed, recent cohort articles or post hoc analyses of clinical trials report FPE rates between 22.8% and 31%.25–27 and a recent meta-analysis found an FPE rate of 40.3% with conventional MT.28 Therefore, DSR MT may be a promising strategy in the therapeutic armamentarium for the endovascular treatment of AIS in occlusions that are difficult to treat with SSR, but may also be an interesting first-line strategy in selected situations.

### DSR safety

One concern with the use of DSR is the potential increased complication rate due to the addition of a second SR, which may exert greater force during clot retrieval. In our meta-analysis, the rate of dissection, SAH and intracranial hemorrhage (AICH and SICH) with DSR is comparable to the recent literature using conventional types of MT.29,30 The estimated rates of dissection and SAH in our meta-analysis were 0.4% and 1.6%, respectively. However, the heterogeneity of the data was significant for dissection ( $I^2$  of 65.9%). In addition, the use of long and large diameter SRs was associated with a higher complication rate in one clinical cohort included in our meta-analysis.14 The rate of ICH on follow-up imaging was also comparable to that reported in the literature, with an estimated 8.1% of AICH and 5.5% of SICH. The fear of a higher rate of complications with the use of a DSR MT therefore would appear to be allayed by our meta-analysis, which found complication rates similar to those reported in the recent literature.

### DSR mechanism of action

Although in-vitro studies were excluded from our meta-analysis because they did not directly involve patients treated for AIS, they may provide insight into the mechanism of action underlying the efficacy of DSR. Indeed, only in vitro studies performed under videographic guidance allow visualization of the interaction between the clot and the SRs during the MT maneuver. Two recent in vitro studies have investigated the efficacy of DSR and confirmed a higher rate of recanalization and a reduction in distal emboli compared to MT by SSR.31,32 Analysis of MT by DSR in these studies provides a better understanding of the mechanisms underlying the improved efficacy of DSR. First, the surface area for interaction between the SR and the clot is increased due to the addition of a second stent, creating a wider "fishing net" effect that ensures a lower risk of clot fragmentation during retrieval. Second, the mechanism of clot capture by the DSR appears to be different to that of an SSR due to a "pincer effect" that traps the clot between the two SRs. Thus, whereas SSRs integrate into soft clots and drag hard clots in a rolling phenomenon, the addition of a second SR modifies the clot capture mechanism in two ways (i.e., a wider "fishing net" and a "pincer effect"), irrespective of clot consistency. Finally, in bifurcation occlusions (e.g., M1-M2), where the exact location of the clot is uncertain, targeting two different branches increases the likelihood that the SR will completely



cover the thrombus. Thus, although targeting the correct or incorrect M2 branch using SSR remains a probabilistic concept, using DSR could reduce the occurrence of partial clot coverage. One of the two in vitro studies also reported a higher clot retraction force with DSR than with SSR using two open cell SRs.<sup>32</sup> However, the retrieval force remained within the range observed with other stent types and designs (open and closed cell). This suggests that the choice of two SRs may have an impact on MT safety.

## Limitations

Our meta-analysis has some major limitations. First, the quality of evidence is poor and relies on a large number of case reports or small series. While the case series and reports show that this approach is certainly feasible and potentially very useful in certain circumstances, the numbers of patient in most articles are small and there is a potential publication bias. Indeed, only one-third of included articles were medium-sized consecutive case series. However, a sub-analysis of these consecutive case series showed results close to those obtained by analyzing all articles in our meta-analysis. Second, our meta-analysis did not have a comparison group that was treated with SSR as none of the studies included such a group. Third, we were unable to access patient-level data for all studies included, which limited the analyses we could perform. In addition, there is no core laboratory adjudication of the results and no external validation of the reported results. Fourth, the technical approaches to MT are not standardized, both in terms of how a conventional thrombectomy failure is considered (number of passes, devices used, intracranial stenting or other rescue techniques, etc.) and in terms of how the DSR is used.

Finally, it is important to emphasize that there are other rescue options that can be considered when first-line thrombectomy fails. Furthermore, the cost-effectiveness of DSR as a first-line or rescue option has not been reported in the literature. We therefore support the recommendation of a multi-center randomized clinical trial to compare DSR with conventional approaches in terms of safety, efficacy and cost-effectiveness.

## CONCLUSIONS

In this meta-analysis of retrospective clinical data from 128 patients treated by MT using DSR, we observed an excellent FPE (76.6%) and successful final recanalization rates (92.6%). In addition, we observed a low complication rate similar to that reported in the literature using conventional endovascular techniques. Future prospective and comparative studies and subsequent patient-level meta-analyses should be conducted to further evaluate the use of DSR as an established strategy for the endovascular treatment of AIS.

## ACKNOWLEDGMENTS

None.

## REFERENCES

1. Alwahdy AS, Dongoran RA. Double stent retriever technique for rescue recanalization in refractory large vessel occlusions. *Radiol Case Rep* 2023;18:2860–3.
2. Asadi H, Brennan P, Martin A, et al. Double Stent-Retriever Technique in Endovascular Treatment of Middle Cerebral Artery Saddle Embolus. *Journal of Stroke and Cerebrovascular Diseases* 2016;25:e9–11.
3. Crosa R, Spiotta AM, Negrotto M, et al. “Y-stent retriever”: a new rescue technique for refractory large-vessel occlusions? *J Neurosurg* 2018;128:1349–53.
4. Imahori T, Miura S, Sugihara M, et al. Double Stent Retriever (SR) Technique: A Novel Mechanical Thrombectomy Technique to Facilitate the Device-Clot Interaction for Refractory Acute Cerebral Large Vessel Occlusions. *World Neurosurg* 2020;141:175–83.
5. Jiang C, Li Y, Hao F, et al. Y-configuration double-stent-retriever thrombectomy for refractory thrombus in middle cerebral artery bifurcation: A case report. *Medicine* 2021;100:E24993.
6. Kato N, Kinkori T, Watanabe K, et al. Parallel Stent Retriever Technique for a Refractory Middle Cerebral Artery Embolism: A Technical Case Report. *Journal of Neuroendovascular Therapy* 2020;14:522.
7. Moreu M, Pérez-García C, Gómez-Escalonilla C, et al. Dual SAVE technique for mechanical thrombectomy rescue on MCA bifurcation clots. *J Neurointerv Surg* 2020;12:1034–1034.
8. Okada H, Matsuda Y, Chung J, et al. Utility of a Y-configured stentriever technique as a rescue method of thrombectomy for an intractable rooted thrombus located on the middle cerebral artery bifurcation: Technical note. *Neurosurg Focus* 2017;42.
9. Peker A, Akgoz A, Arsava EM, et al. Dual Mechanical Thrombectomy for Recanalization of a Resistant Acute Posterior Circulation Stroke. *J Cerebrovasc Endovasc Neurosurg* 2017;19:96–100.
10. Sasaki I, Imahori T, Yano T, et al. Crossing double stent retriever technique for refractory terminal internal carotid artery occlusion. *Radiol Case Rep* 2022;17:1848–52.
11. Yoshimoto T, Hosoki S, Tanaka K, et al. Parallel stent retriever mechanical thrombectomy of an acute internal carotid artery occlusion refractory to standard techniques: A case report. *Frontiers in Stroke* 2023;2:1066491.
12. Li Z, Liu P, Zhang L, et al. Y-Stent Rescue Technique for Failed Thrombectomy in Patients With Large Vessel Occlusion: A Case Series and Pooled Analysis. *Front Neurol* 2020;11:924.
13. Aydin K, Barbuoglu M, Oztop Cakmak O, et al. Crossing Y-Solitaire thrombectomy as a rescue treatment for refractory acute occlusions of the middle cerebral artery. *J Neurointerv Surg* 2019;11:246–50.
14. Cabral LS, Mont’Alverne F, Silva HC, et al. Device size selection can enhance Y-stentriever efficacy and safety as a rescue strategy in stroke thrombectomy. *J Neurointerv Surg* <https://doi.org/10.1136/neurintsurg-2021-017751>.
15. Klisch J, Sychra V, Strasilla C, et al. Double solitaire mechanical thrombectomy in acute stroke: Effective rescue strategy for refractory artery occlusions? *American Journal of Neuroradiology* 2015;36:552–6.
16. Xu H, Peng S, Quan T, et al. Tandem stents thrombectomy as a rescue treatment for refractory large vessel occlusions. *J Neurointerv Surg* 2021;13:33–

8.

17. Vega P, Murias E, Jimenez JM, et al. First-line Double Stentriever Thrombectomy for M1/TICA Occlusions: Initial Experiences. Clin Neuroradiol <https://doi.org/10.1007/S00062-022-01161-2>
18. Hacke W, Kaste M, Fieschi C, von Kummer R, Davalos A, Meier D, et al. Randomised double-blind placebo-controlled trial of thrombolytic therapy with intravenous alteplase in acute ischaemic stroke (ECASS II). Second European-Australasian Acute Stroke Study Investigators. Lancet. 1998; 352:1245–1251
19. Wells GA, Tugwell P, O'Connell D, Welch V, Peterson J, Shea B, Losos M.. The Newcastle-Ottawa Scale (NOS) for Assessing the Quality of Nonrandomized Studies in Meta-Analyses. Ottawa: Ottawa Hospital Research Institute; 2011. Oxford. asp; 2011.
20. Barendregt JJ, Doi SA, Lee YY, et al. Meta-analysis of prevalence. J Epidemiol Community Health 2013;67:974–8.
21. Borenstein M, Hedges L V., Higgins JPT, et al. A basic introduction to fixed-effect and random-effects models for meta-analysis. Res Synth Methods 2010;1:97–111.
22. Kobeissi H, Ghozy S, Adusumilli G, et al. Endovascular Therapy for Stroke Presenting Beyond 24 Hours: A Systematic Review and Meta-analysis. JAMA Netw Open 2023;6:e2311768–e2311768.
23. Clarençon F, Blanc R, Gallas S, et al. Thrombectomy for acute basilar artery occlusion by using double Merci retriever devices and bilateral temporary vertebral artery flow reversal: Technical note. J Neurosurg 2009;111:53–6.
24. Fischer U, Kaesmacher J, Strbian D, et al. Thrombectomy alone versus intravenous alteplase plus thrombectomy in patients with stroke: an open-label, blinded-outcome, randomised non-inferiority trial. The Lancet 2022;400:104–15.
25. Kamiya Y, Suzuki K, Miyauchi Y, et al. Intravenous Thrombolysis Increases the First Pass Effect for Large Vessel Occlusion Treated With Mechanical Thrombectomy. Stroke: Vascular and Interventional Neurology 2023;3.
26. Zaidat OO, Castonguay AC, Linfante I, et al. First Pass Effect. Stroke 2018;49:660–6.
27. Di Maria F, Kyheng M, Consoli A, et al. Identifying the predictors of first-pass effect and its influence on clinical outcome in the setting of endovascular thrombectomy for acute ischemic stroke: Results from a multicentric prospective registry. International Journal of Stroke 2021;16:20–8.
28. Jang KM, Choi HH, Nam TK, et al. Clinical outcomes of first-pass effect after mechanical thrombectomy for acute ischemic stroke: A systematic review and meta-analysis. Clin Neurol Neurosurg 2021;211:107030.
29. Pilgram-Pastor SM, Piechowiak EI, Dobrocky T, et al. Stroke thrombectomy complication management. J Neurointerv Surg 2021;13:912–7.
30. Ngankou EH, Gory B, Marnat G, et al. Thrombectomy complications in large vessel occlusions: Incidence, predictors, and clinical impact in the ETIS registry. Stroke 2021;52:E764–8.
31. Li J, Tiberi R, Canals P, et al. Double stent-retriever as the first-line approach in mechanical thrombectomy: A randomized in vitro evaluation. J Neurointerv Surg <https://doi.org/10.1136/JNIS-2022-019887>.
32. Hofmeister J, Bernava G, Rosi A, et al. Benchtop evaluation of a double stent retriever thrombectomy technique for acute ischemic stroke treatment. Interventional Neuroradiology <https://doi.org/10.1177/15910199231179846>

**Table 1:** Characteristics of patients and endovascular procedures in the included studies (n=18).

Study	N	Age	Gender	NIHSS	IV Lysis	DSR approach	DSR technique	Stents type	Aspiration	Clot location
Alwahdy et al. (2023)	1	50	M	18	1 (100%)	rescue	parallel	ERIC 6 × 44 mm and Catch 4 × 20 mm	Proximal	ICA
Asadi et al. (2016)	1	76	M	16	1 (100%)	rescue	NA	Trevo ProVue 4x20 mm and Embotrap 5x21 mm	Proximal	M1
Aydin et al. (2019)	10	69.8* [34-83]	5 M, 5 F	19† [16-22]	3 (30%)	rescue	stent-in-stent	First stent: Solitaire 6x30 mm or 4x20 mm Second stent: Solitaire 4x20 mm	Proximal (through BGC)	MCA
Cabral et al. (2021)	20	62.4*± SD 14.7	11 M, 9 F	16.6*± SD 5.7	9 (45%)	rescue	parallel	Trevo XP (n=18), Solitaire (N=15), NeVa (n=3),	Proximal	10 ICA, 18 M1, 5 M2, 1 BA

								EmboTrap (n=2) and Catch Plus (n=2) (no specification on their combination). Mean size and length: First stent: 4.92 (± 1.03) x 31.15 (±7.05) mm Second stent: 4.01 (±0.34) x 26.1 (±7.0) mm		
Crosa et al. (2018)	1	57	M	12	0 (0%)	rescue	stent-in-stent	Solitaire SR 4x20 mm and Catch SR 4x20 mm	Proximal	MCA
Imahori et al. (2020)	2	69 and 72	1 M, 1 F	16 and 27	0 (0%)	rescue	stent-in-stent	First case: Trevo XP 6 × 25 mm and Trevo XP 4 × 30 mm Second case: Trevo XP 6 × 25 mm and Solitaire 18 Platinum 6 × 30 mm	Proximal (through BGC)	ICA
Jiang et al. (2021)	1	72	M	16	1 (100%)	rescue	stent-in-stent	Solitaire 6x30 mm and Solitaire 4x15 mm	Distal	MCA M1
Kato et al. (2022)	1	86	M	28	0 (0%)	rescue	parallel	Solitaire Platinum 6x40 m and Trevo XP ProVue 6x25 mm	NA	M1
Klisch et al. (2015)	1 0	70* [51-88]	7M, 3 F	16 [IQR: 13-19]	NA	9 rescue, 1 first-line	parallel	Two Solitaire device of similar or different sizes (eg. 4x20 mm and 6x30 mm) (no specification on their combination)	Distal	3 ICA, 2 ICA-M1, 5 M1
Li et al. (2020)	2 8	66.9*± SD 9,6	18 M, 10 F	21*±S D 8	6 (21.4%)	rescue	parallel	Solitaire and Rvice SE (n=16),	Proximal and distal	17 ICA, 4 MCA, 7 BA
Moreu et al. (2020)	1	NA	NA	NA	0 (0%)	rescue	stent-in-stent	EmboTrap and Trevo 4x30 mm	NA	MCA



Okada et al. (2017)	1	80	M	NA	0 (0%)	rescue	stent-in-stent	Trevo 4x30 mm and Trevo 4x20 mm	ProVue and ProVue	Proximal (through BGC) and distal	M1
Peker et al. (2017)	1	71	M	27	0 (0%)	rescue	parallel	Two Plus	Catch Mini	Distal	BA
Sasaki et al. (2022)	1	87	M	26	0 (0%)	rescue	parallel	Two 4 × 28 mm	Trevo NXT	Proximal (through BGC)	ICA
Vega et al. (2022)	3 9	79† [42-96]	16 M, 23 F	17*±S D 4.39	6 (15.4%)	first-line	parallel	Solitaire and Trevo and Embotrap II and 6.5x45 mm (no specification on their combination)	X 4x40 mm, 6x40 mm, NXT 4x35 mm, 5x37 mm	Proximal (through BGC)	19 ICA, 20 M1
Xu et al. (2021)	9	65.2* [29-84]	6 M, 3 F	18†[12-24]	2 (22.2%)	rescue	stent-in-stent	First Solitaire mm Second Solitaire 4.5x22 mm	stent: FR 6x30 mm stent: FR 4x20 mm or ReVive SE	Proximal and/or distal (not detailed)	3 ICA, 6 M1
Yoshimoto et al. (2023)	1	68	F	28	0 (0%)	rescue	parallel	Two mm	Trevo 6x25 mm	Proximal (through BGC)	ICA

**Abbreviations:** \* mean, † median, [] range, BA = basilar artery, BGC = balloon-guide catheter, F = female, GCS: Glasgow Coma Scale, ICA = internal carotid artery, IQR = interquartile range, M = male, MCA = middle cerebral artery, M1 = M1 segment of the MCA, M2 = M2 segment of the MCA, SD = standard deviation, NA = not available, NIHSS = National Institutes of Health Stroke Scale.

**Table 2.** Newcastle-Ottawa Scale to evaluate the quality of evidence of the included studies (n=17).

Study	Selection				Comparability	Outcome			Total
	Representativeness of the exposed cohort	Selection of the non exposed cohort	Ascertainment of exposure	Outcome of interest was not present at start of study	Comparability of cohorts on the basis of the design or analysis	Assessment of outcome	Length of FU	Adequacy of FU	
Alwahdy et al. (2023)	*		*	*		*	*		5/9
Asadi et al. (2016)	*		*	*		*			4/9

Aydin et al. (2019)	*	*	*	*	*	*	6/9
Cabral et al. (2021)	*	*	*	*			4/9
Crosa et al. (2018)	*	*	*	*			4/9
Imahori et al. (2020)	*	*	*	*	*	*	6/9
Jiang et al. (2021)	*	*	*	*	*	*	6/9
Kato et al. (2022)	*	*	*	*			4/9
Klisch et al. (2015)	*	*	*	*			4/9
Li et al. (2020)	*	*	*	*	*	*	6/9
Moreu et al. (2020)	*	*	*	*			4/9
Okada et al. (2017)	*	*	*	*			4/9
Peker et al. (2017)	*	*	*	*			4/9
Sasaki et al. (2022)	*	*	*	*	*		5/9
Vega et al. (2022)	*	*	*	*	*	*	6/9
Xu et al. (2021)	*	*	*	*	*	*	6/9
Yoshimoto et al. (2023)	*	*	*	*			4/9

Abbreviations: FU = Follow-up

**Table 3.** Estimated prevalence of successful recanalization (mTICI  $\geq 2b$ ) and a first-pass effect following DSR, as well as complications due to dissection, SAH, AICH and SICH. A) Estimated prevalence for all studies (n=17). B) Estimated prevalence for large studies only (n= 6).

A)

	Prevalence (95% CI)	Heterogeneity $I^2$	Wld (p-value)
FPE	76.56% [68.46-83.10]	0%	2.35 (p=1.0)
mTICI $\geq 2b$	92.60% [82.43-97.01]	26.42%	0.31 (p=1.0)
Dissection	0.37% [0-44.50]	65.90%	0.0 (p=1.0)
SAH	1.56% [0.39-6.03]	0%	0.97 (p=1.0)
AICH	8.05% [3.14-19.14]	33.58%	0.55 (p=1.0)
SICH	5.47% [2.63-11.03]	0%	0.86 (p=1.0)

B)

	Prevalence (95% CI)	Heterogeneity I <sup>2</sup>	Wld (p-value)
FPE	75.0% [66.34-82.04]	0%	1.79 (p=0.877)
mTICI $\geq$ 2b	91.05% [80.04-96.27]	44.39%	0.31 (p=0.998)
Dissection	0.42% [0-58.34]	75.96%	0.0 (p=1.0)
SAH	1.72% [0.43-6.63]	0%	0.97 (p=0.965)
AICH	8.37% [3.13-20.55]	50.0%	0.55 (p=0.990)
SICH	6.03% [2.90-12.12]	0%	0.85 (p=0.973)

Abbreviations: AICH = asymptomatic intracranial hemorrhage, FPE = First-pass effect, SAH = subarachnoid hemorrhage, SICH = symptomatic intracranial hemorrhage, Wld = Wald-type test statistic of the test for (residual) heterogeneity.

## SUPPLEMENTAL FILES

**Supplementary Figure 1.** PRISMA diagram summarizing the systematic process used to identify, screen, and include articles analyzed for this review.

**Supplementary Figure 2.** Funnel plots. Abbreviations: AICH= asymptomatic intracranial hemorrhage, FPE = first-pass effect, SAH = subarachnoid hemorrhage, SICH = symptomatic intracranial hemorrhage.

**Supplementary Figure 3.** Funnel plots in large cohorts only (n=6). Abbreviations: AICH = asymptomatic intracranial hemorrhage, FPE = first-pass effect, SAH = subarachnoid hemorrhage, SICH = symptomatic intracranial hemorrhage.