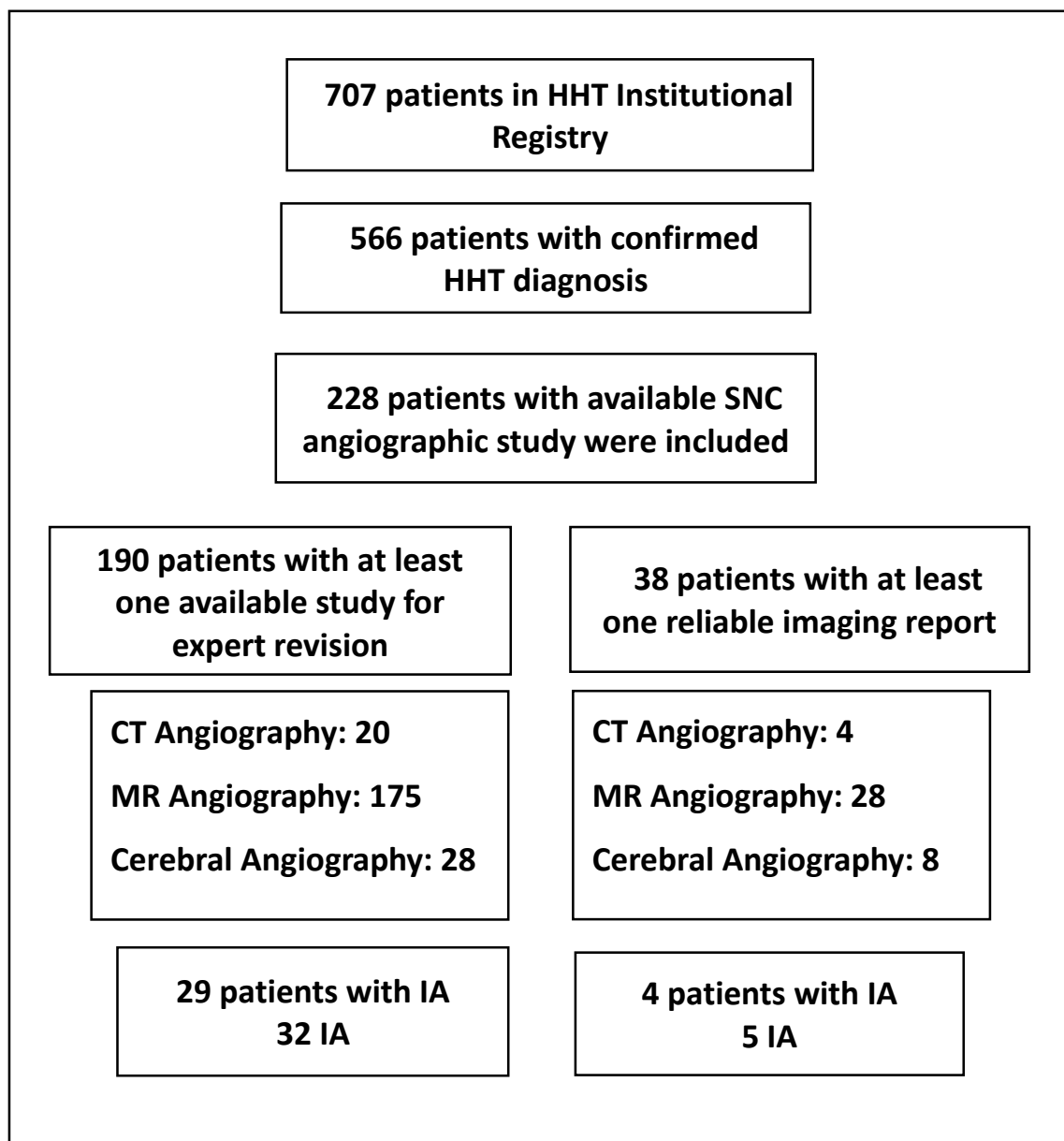


Prevalence of Intracranial Aneurysms in Hereditary Hemorrhagic Telangiectasia: report from a single reference center

Supplementary Material

S. Fig 1: Study Flow Chart



Abbreviations: HHT: hereditary hemorrhagic telangiectasia, IA: intracranial aneurysm.